

Mitral Loop Cerclage

annuloplasty for mitral regurgitation

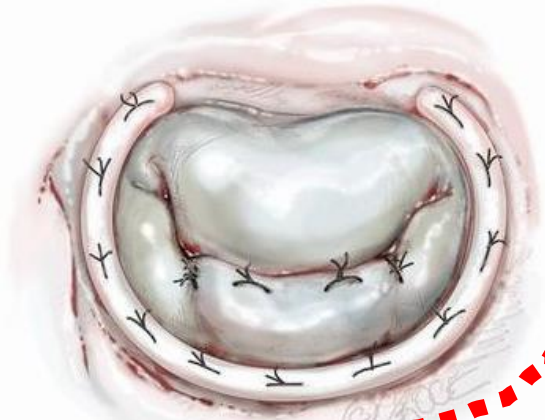Yong Hyun Park, MD

Pusan National University Yangsan Hospital

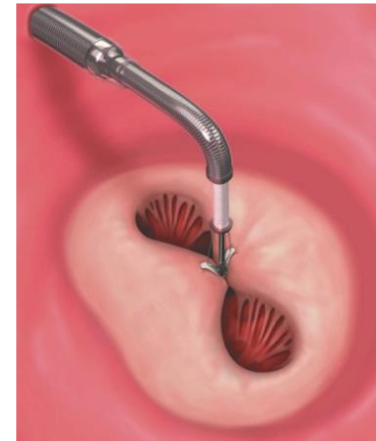I have nothing to disclose.

Transcatheter MV repair

Leaflet correction + annuloplasty

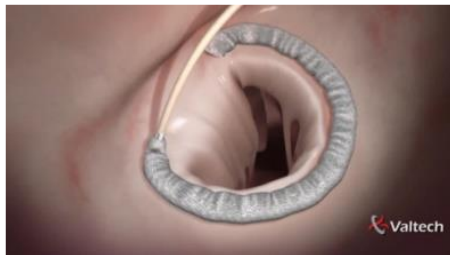


Leaflet correction



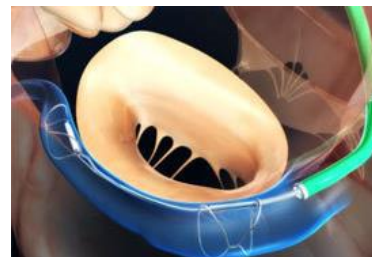
Mitraclip

Direct annuloplasty

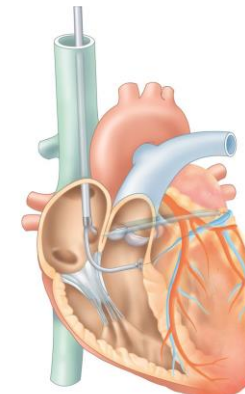


Cardioband

Indirect annuloplasty



Carillon



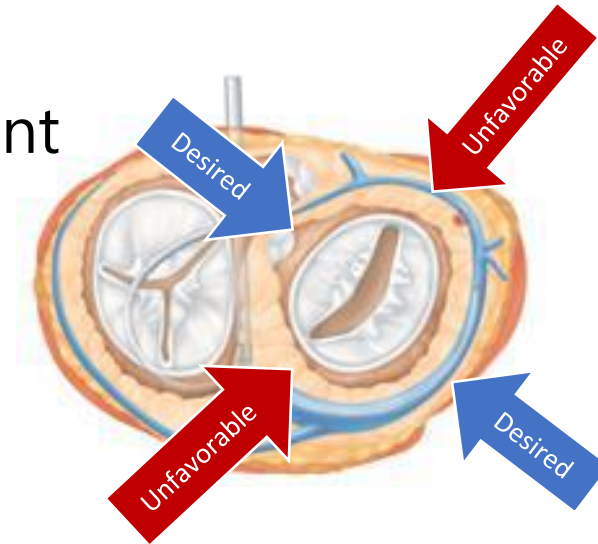
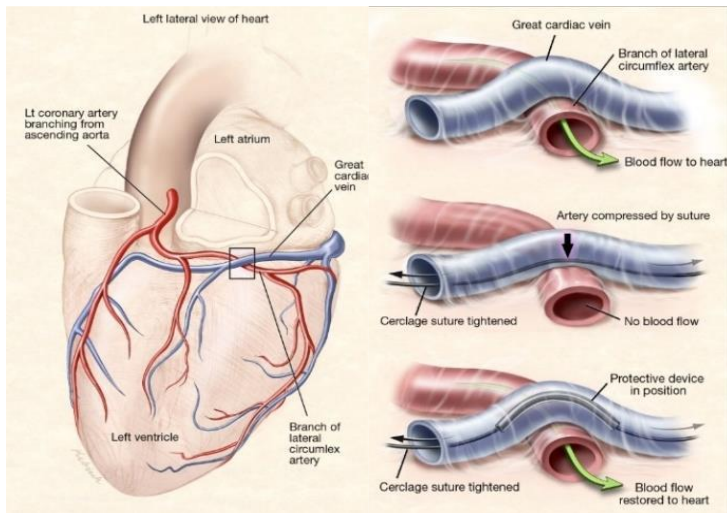
Cerclage

CS approach

: limitations and solutions

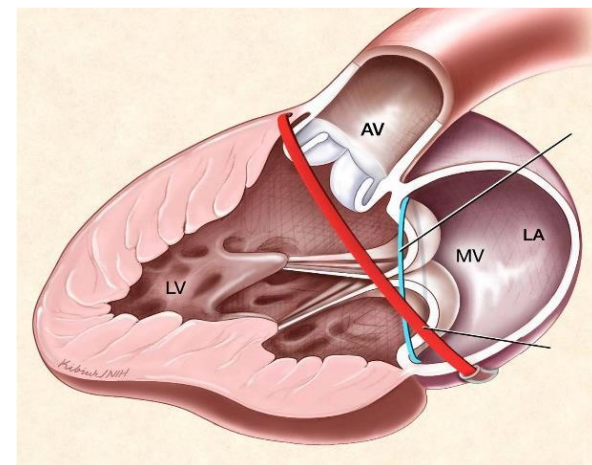
1: hemi-circumferential compression : insufficient

- Solution: **circumferential compression**



2: Coronary artery entrapment

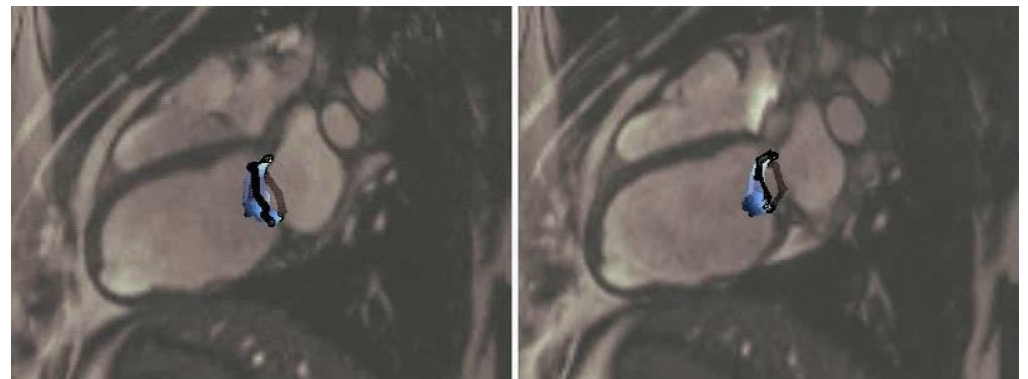
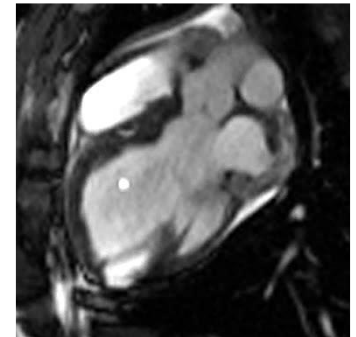

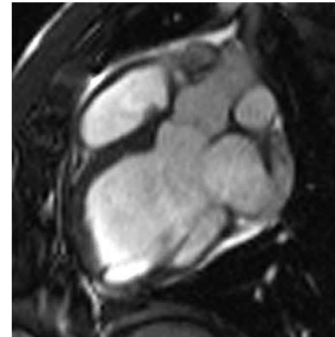
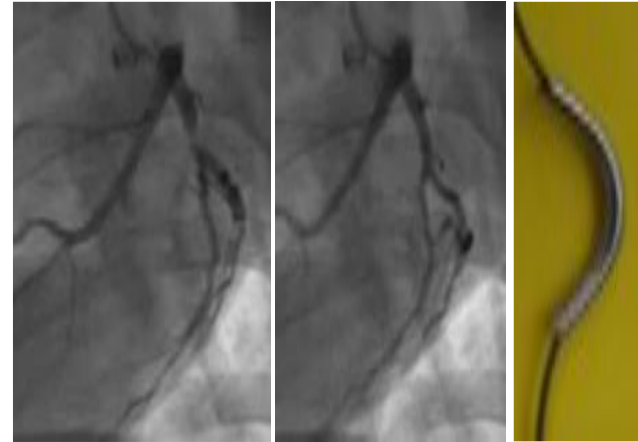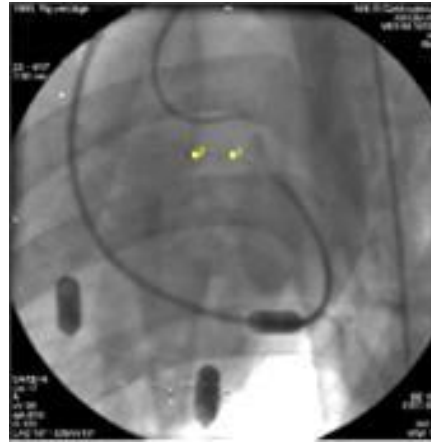
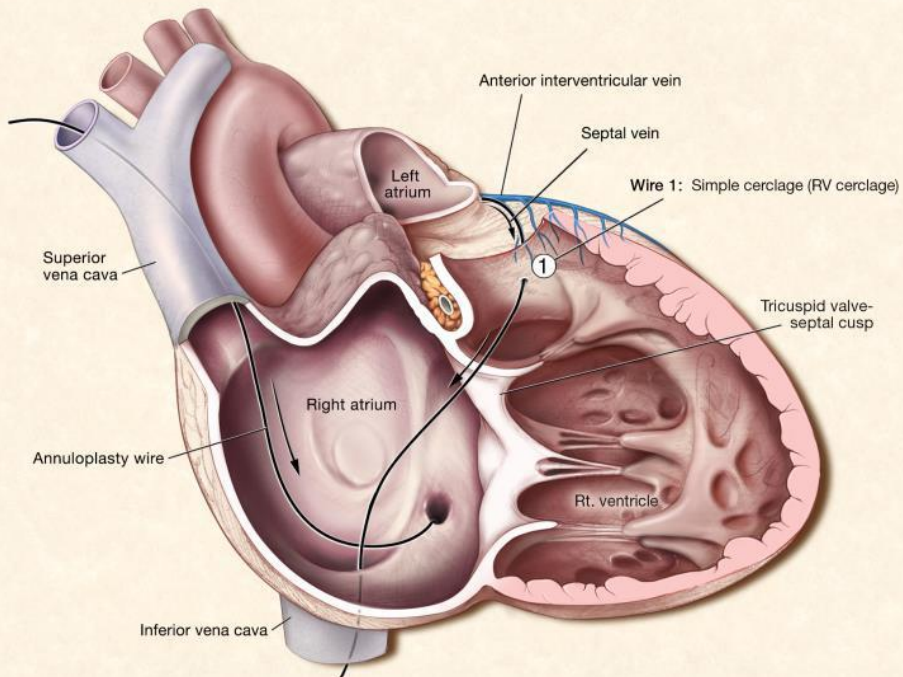
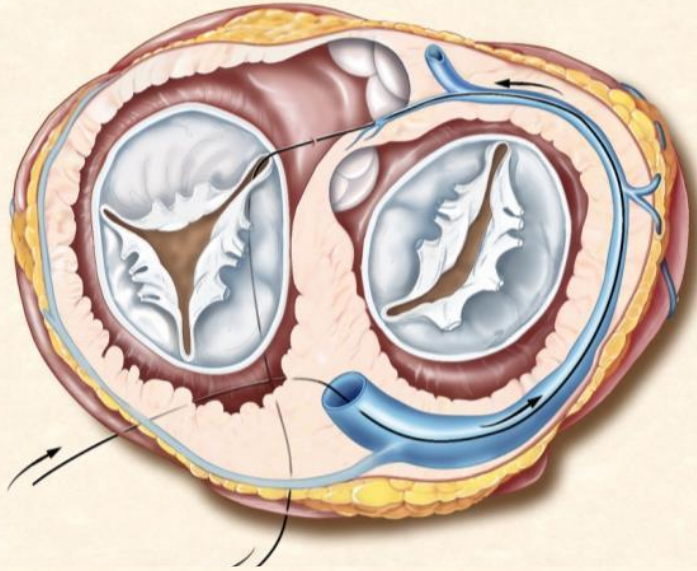
- Solution: **coronary protection**



3: Coronary sinus far from annulus

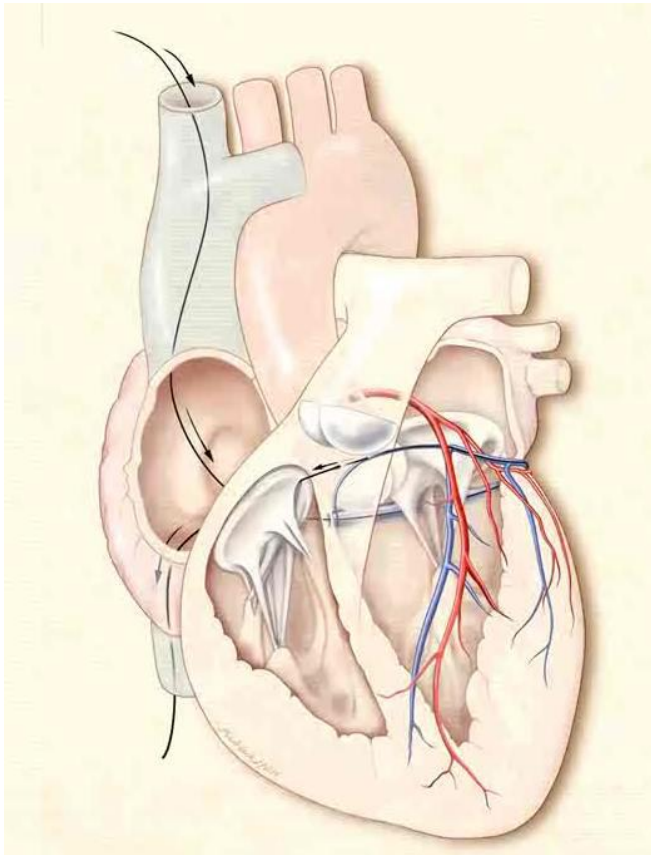
- Solution: **"Apical tilt" of plane**

Pre-clinical 'mitral cerclage'



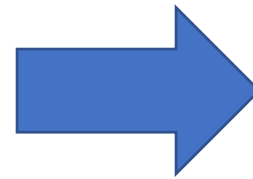
What is Mitral Loop Cerclage ?

- Circumferential tension around MV annulus by LV basal squeezing

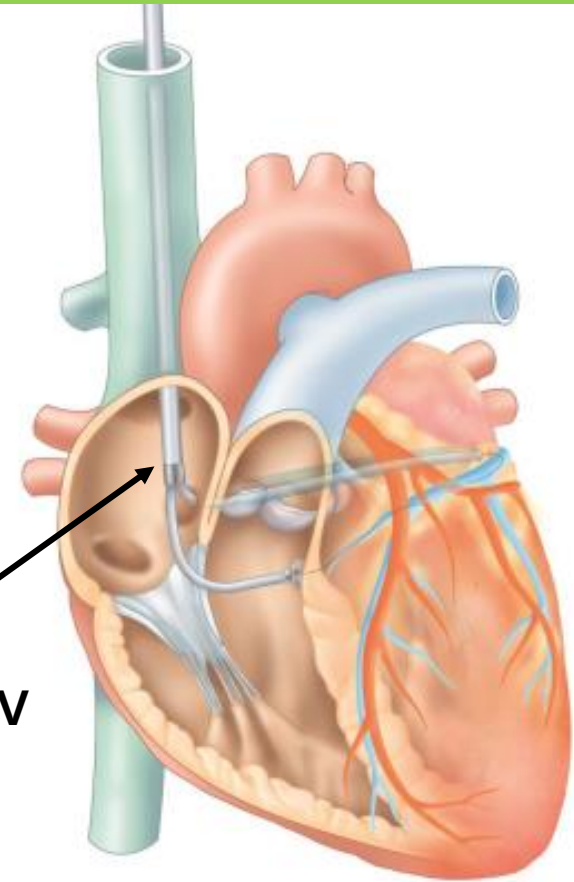


Mitral Cerclage

- Reinforce of safety issues
- improving technical feasibility



CSTV
(coronary sinus and TV
protective device)

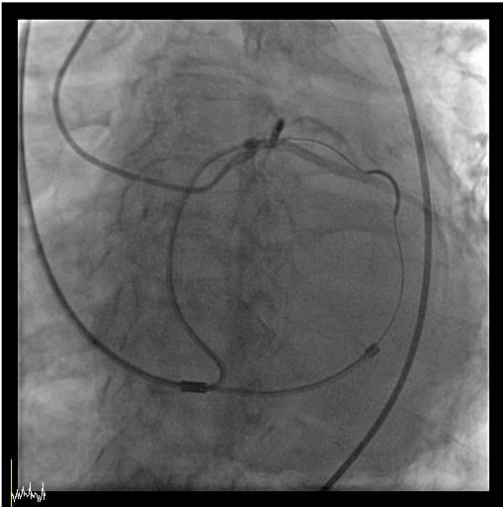
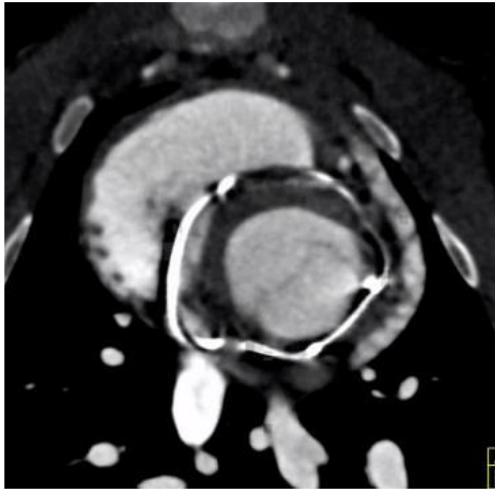


Mitral Loop Cerclage

+ a bifid appliance =

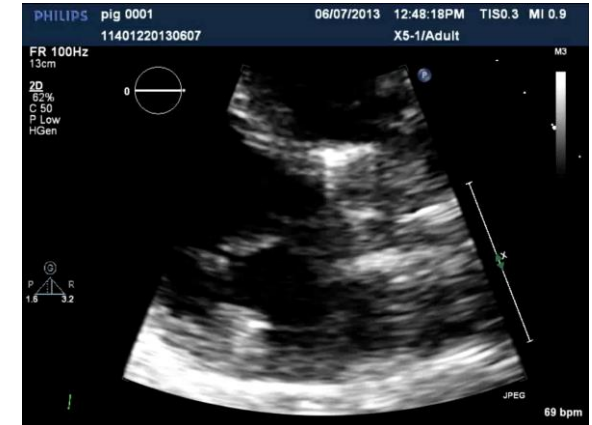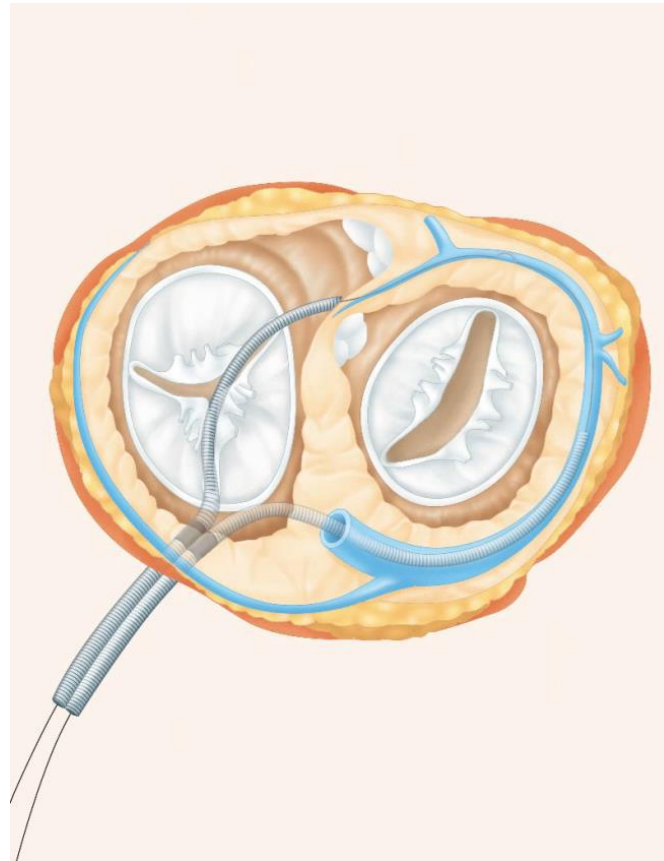
MLC: How to function?

(1) TV & conduction protection



Arch formation during tension

(2) Interactive tension adjustment

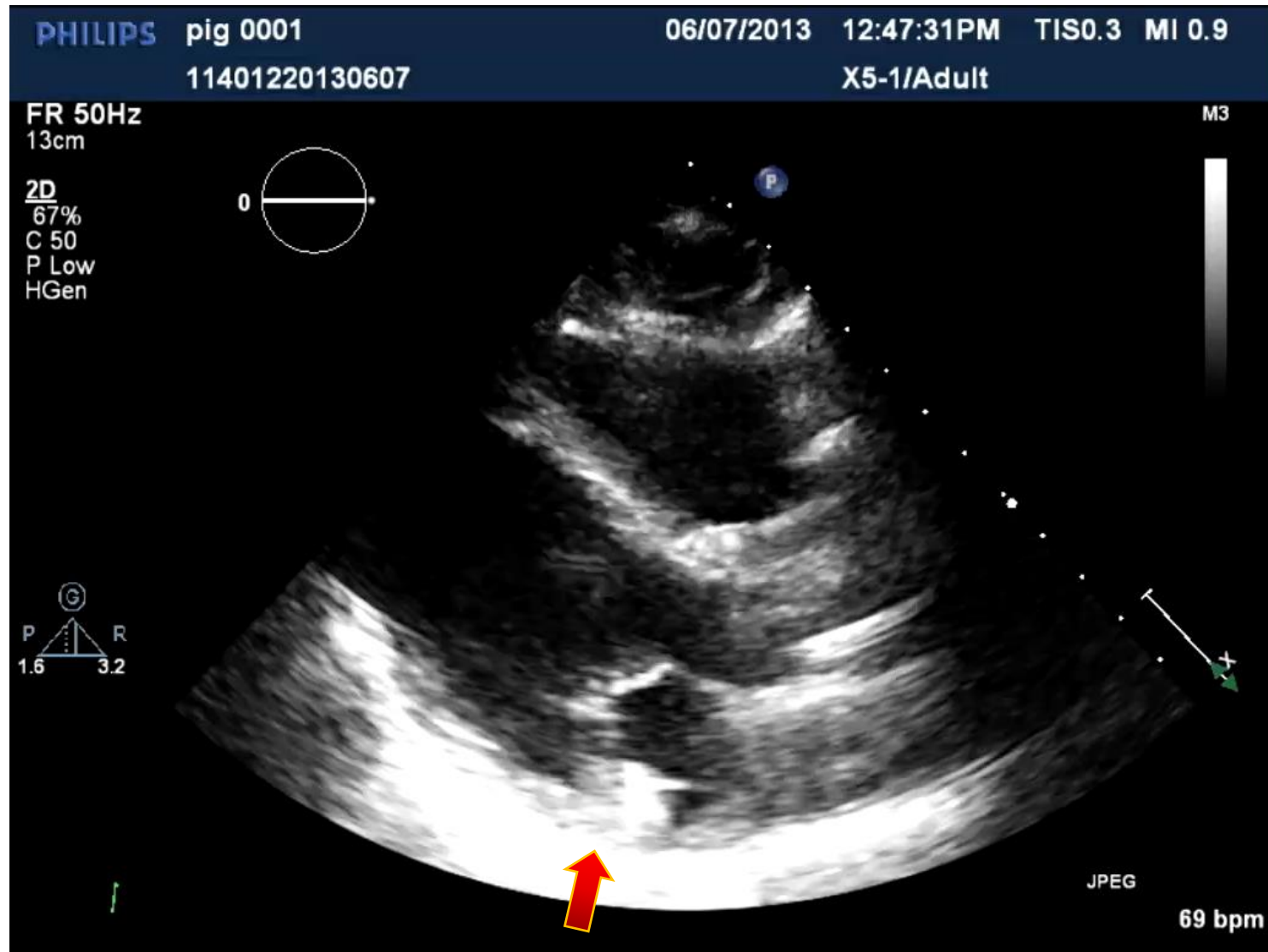


Septal lateral dimension

Tensioning through a tip
of CSTV loop

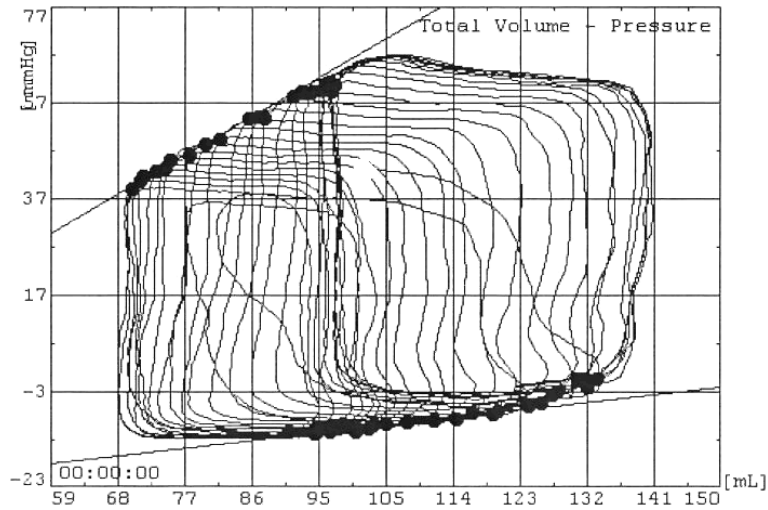
(3) Easy re-adjustment of tension when it is needed

Adjustment of S-L dimension

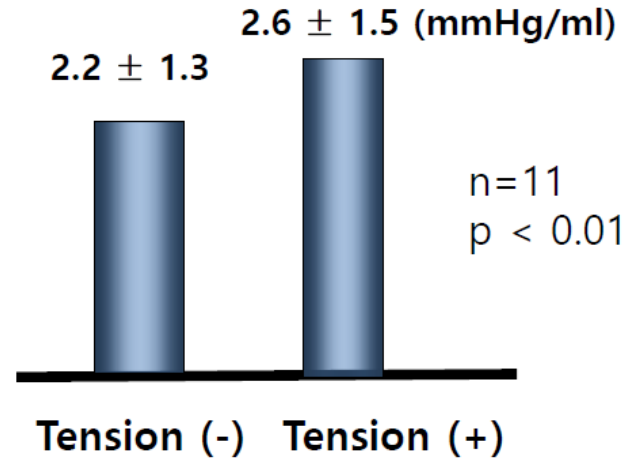


Basal LV squeezing: Is it OK for sick heart?

Preserved contractility & reduced LV wall tension

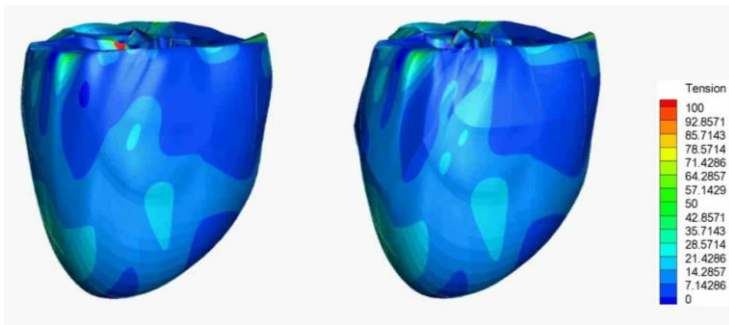


End systolic pressure volume relationship (Ees)




Original model

Modified model

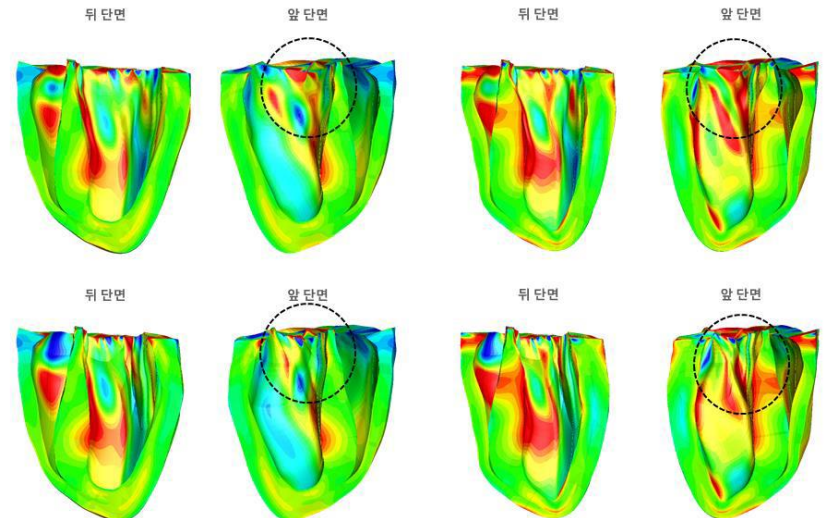



Original model

End-diastolic



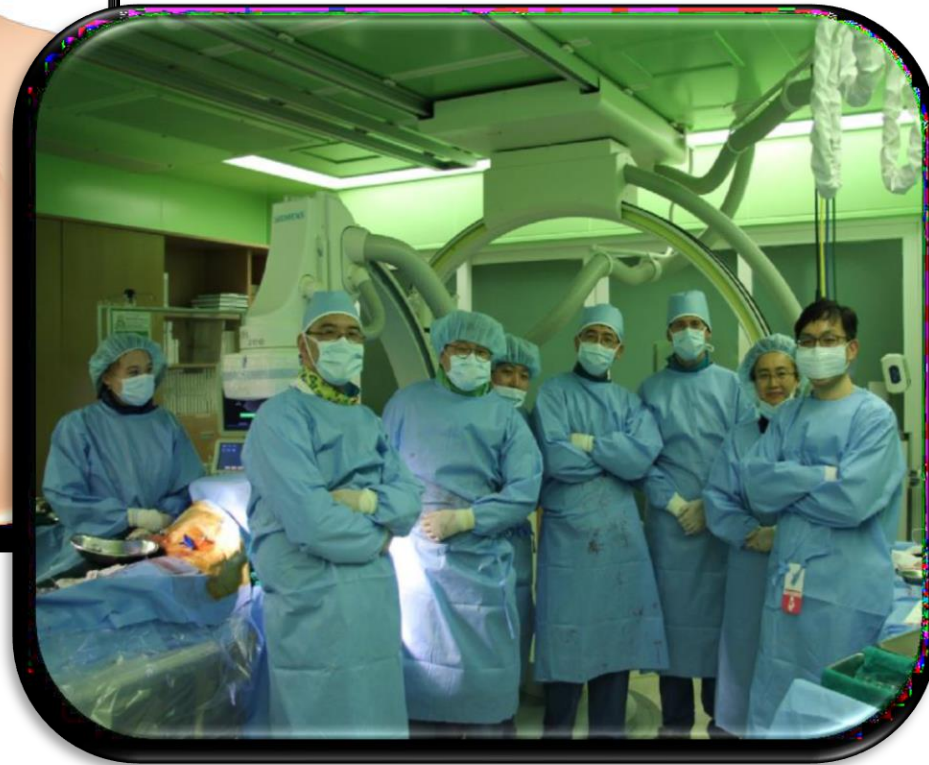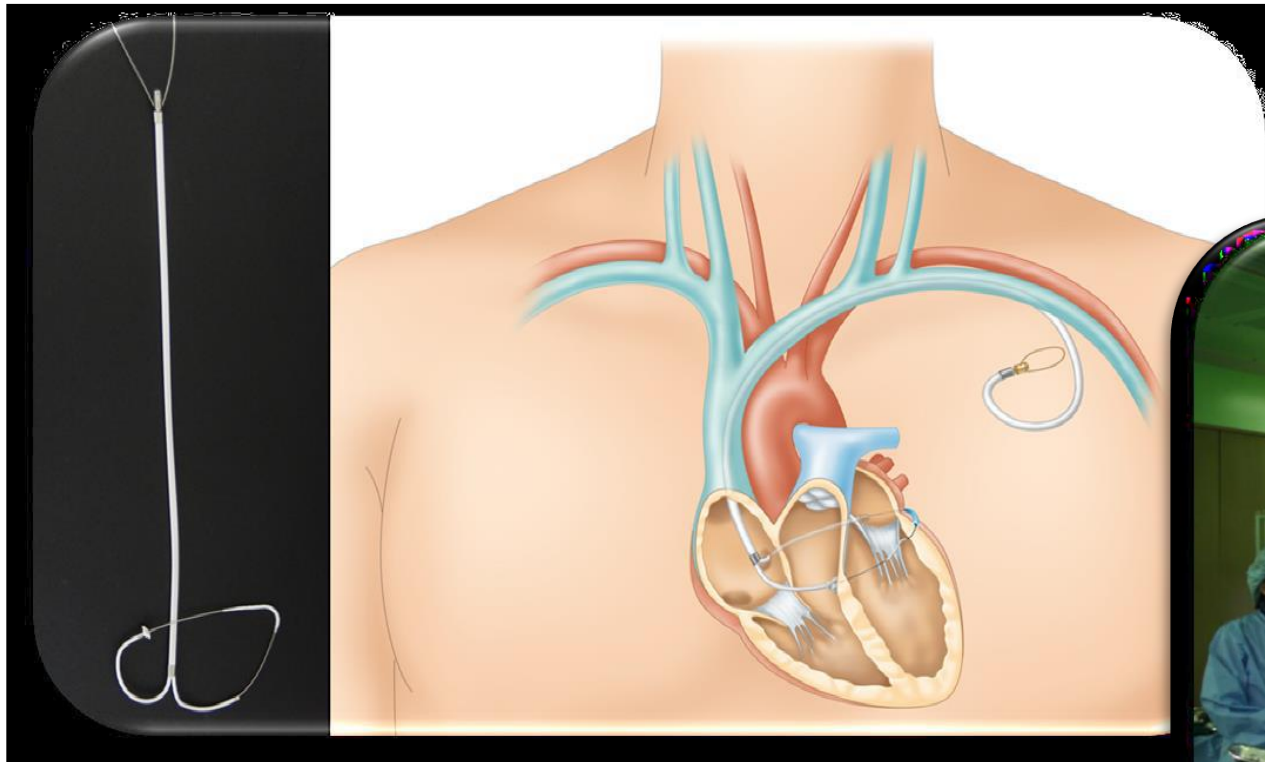
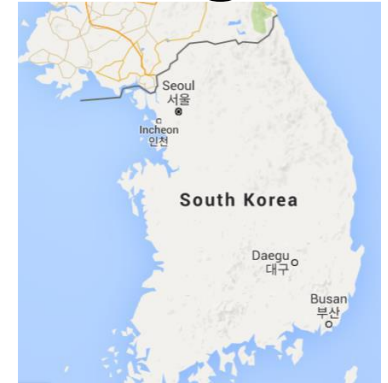Modified model



Computational heart modeling with real human data,

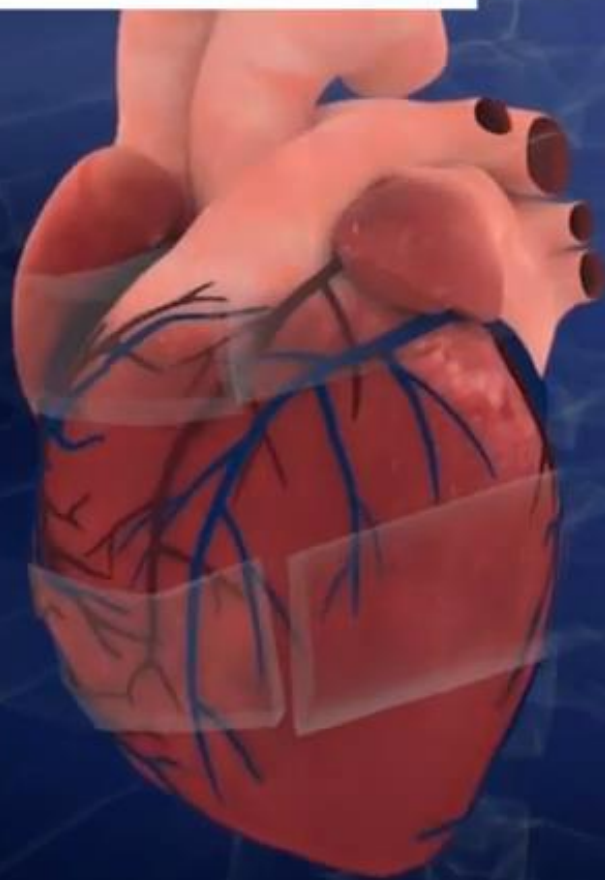
The early feasibility study of Mitral Loop Cerclage (n=5)

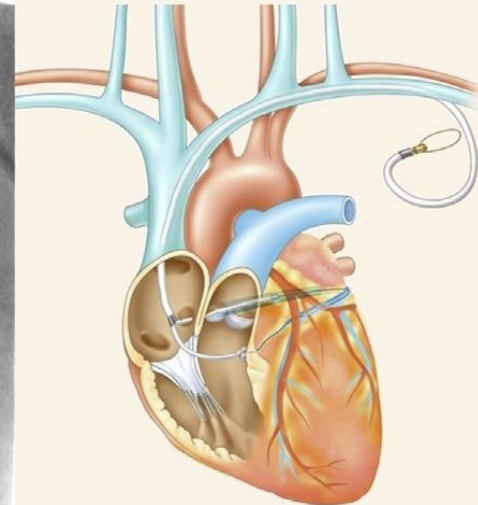
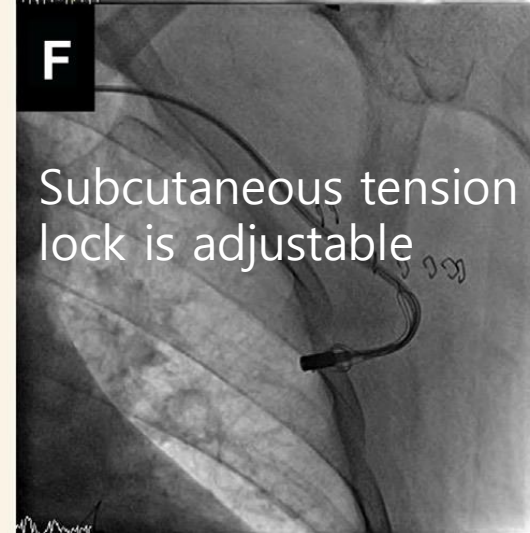
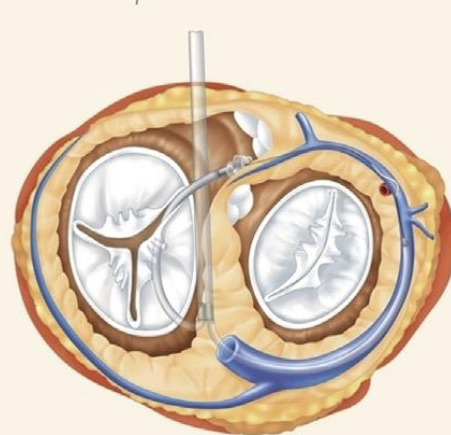
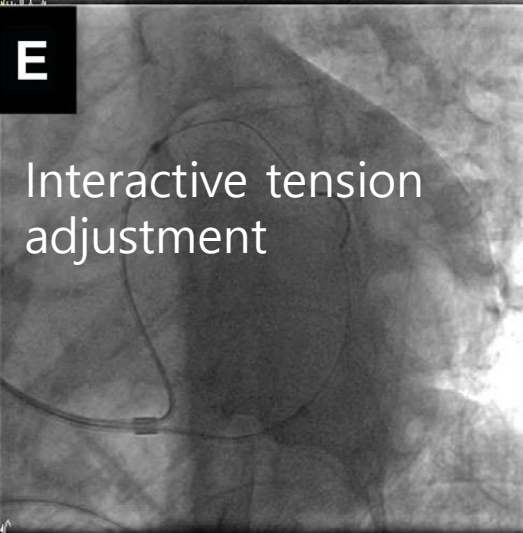
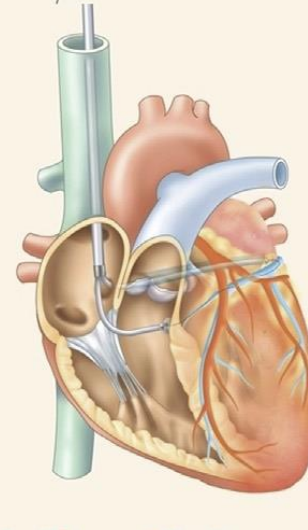
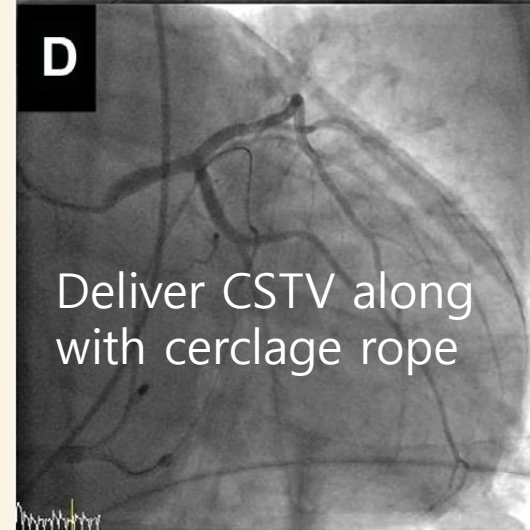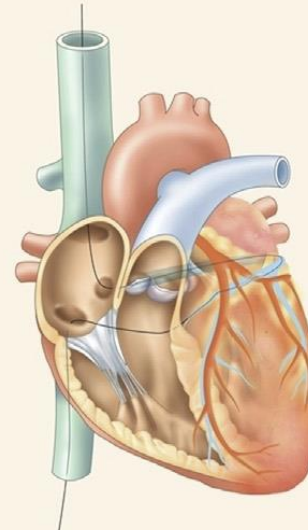
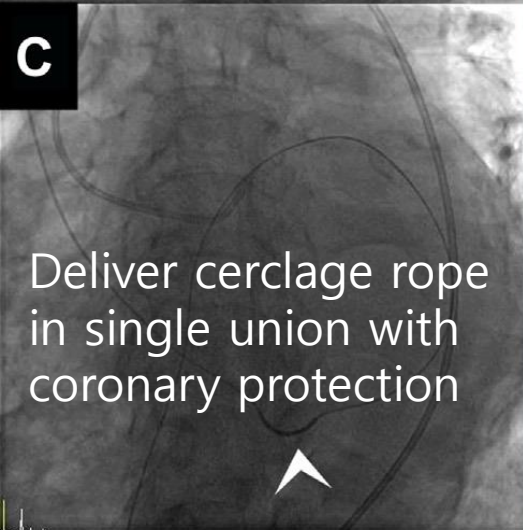
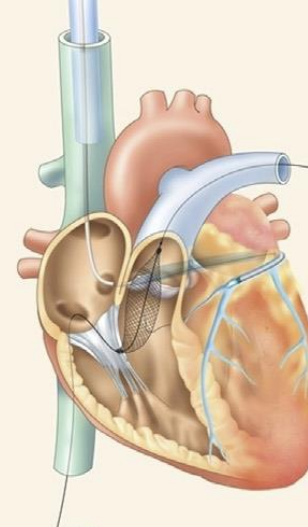
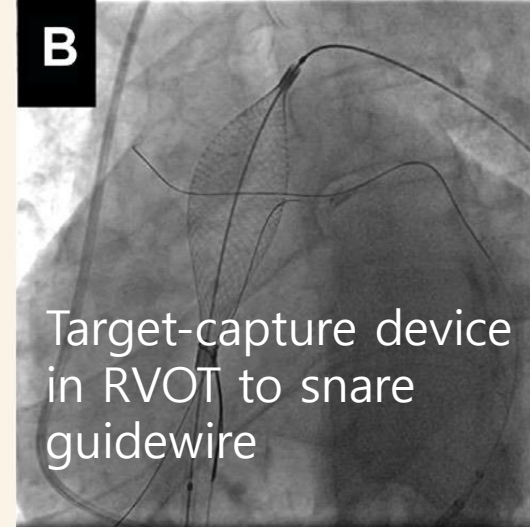
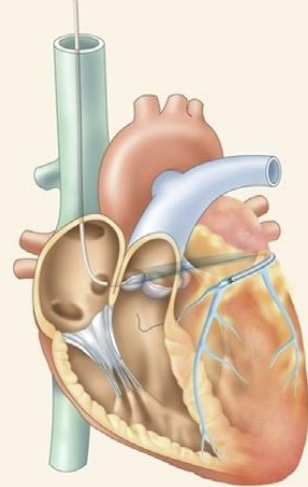
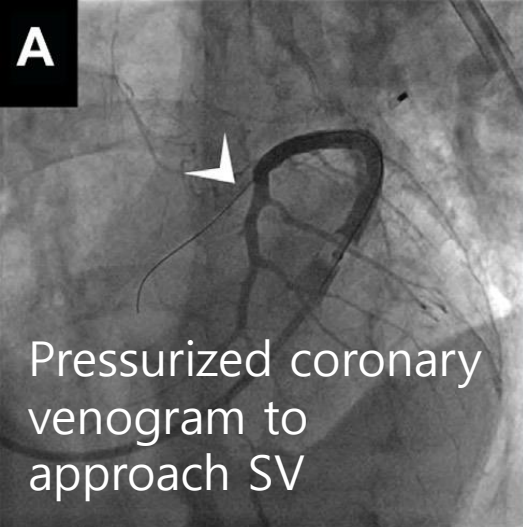
The first case of Mitral Loop Cerclage FIM in PNUYH, Korea (July 10th 2015)



Inclusion : NYHA class III or IV dyspnea due to severe functional MR in spite of optimal medical TX at least for 3 months

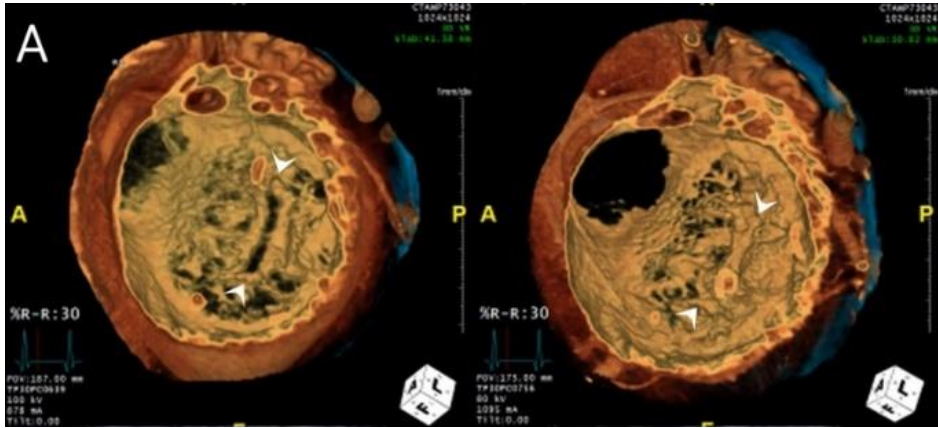
Mitral Loop Cerclage Annuloplasty





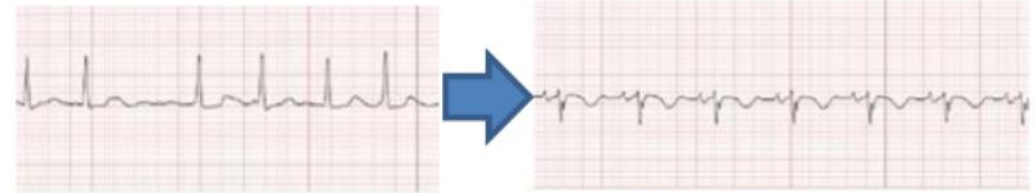
A Representative Case of MLC

74F, NICM, NYHA IV dyspnea despite aggressive medical therapy for 1yr



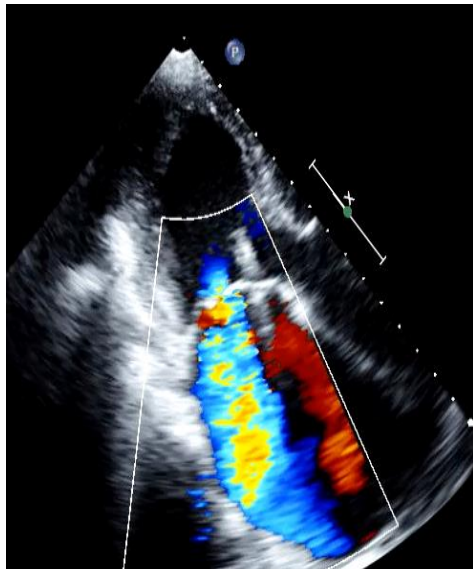
Baseline

1 month

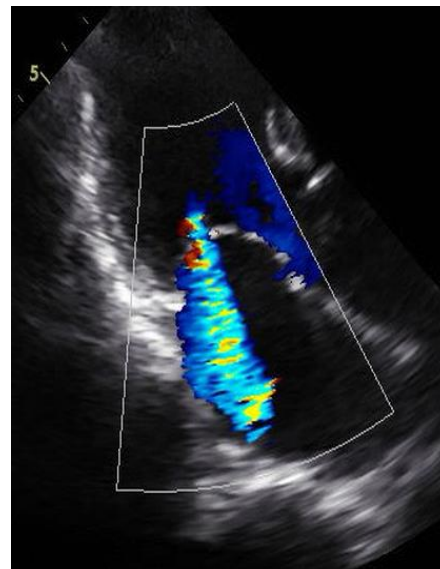

Chronic AF

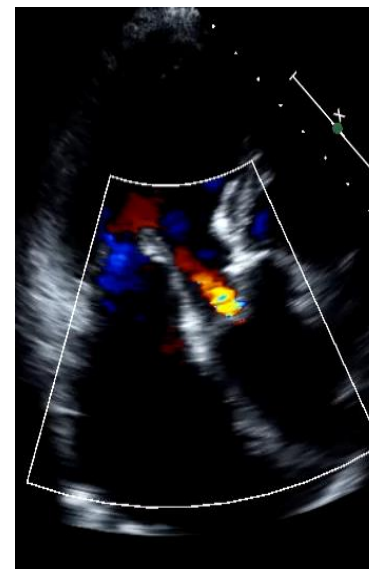
Normal sinus rhythm



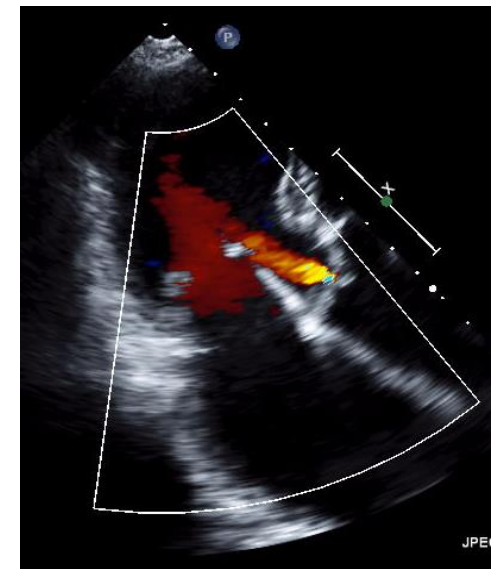- ERO 0.34 cm²
- RV 63 ml
- Atrial fibrillation



- ERO 0.14 cm²
- RV 25 ml
- Normal sinus R



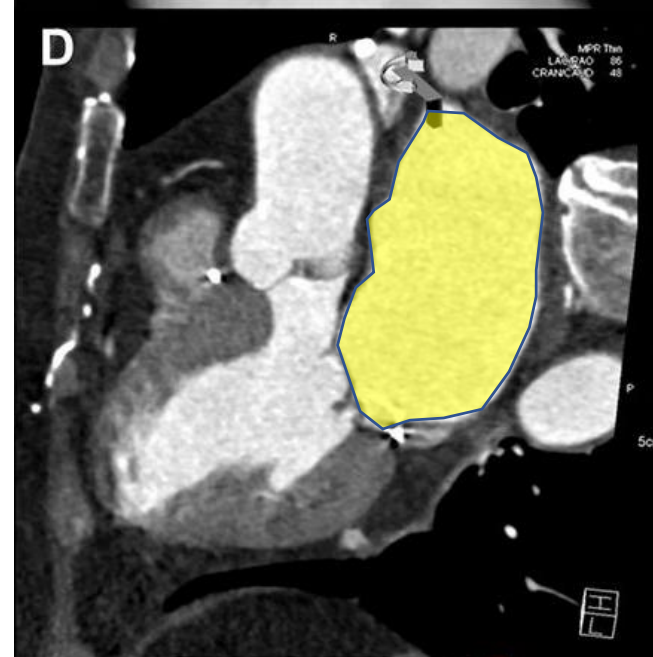
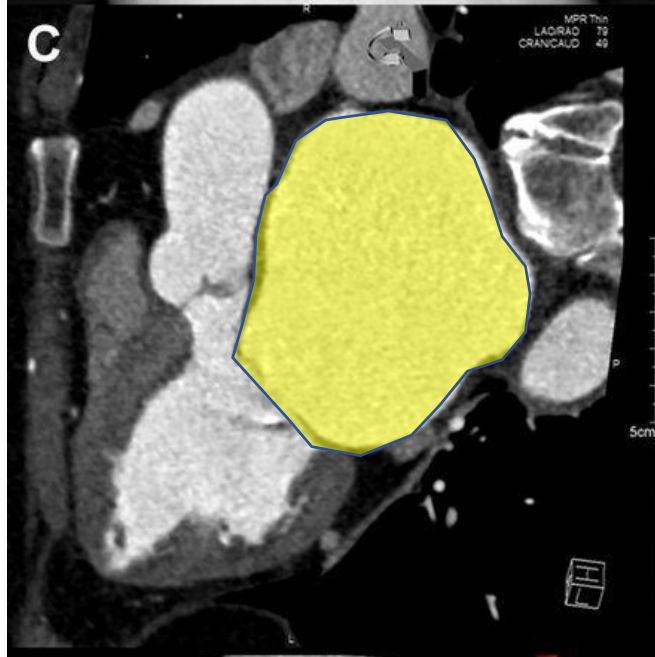
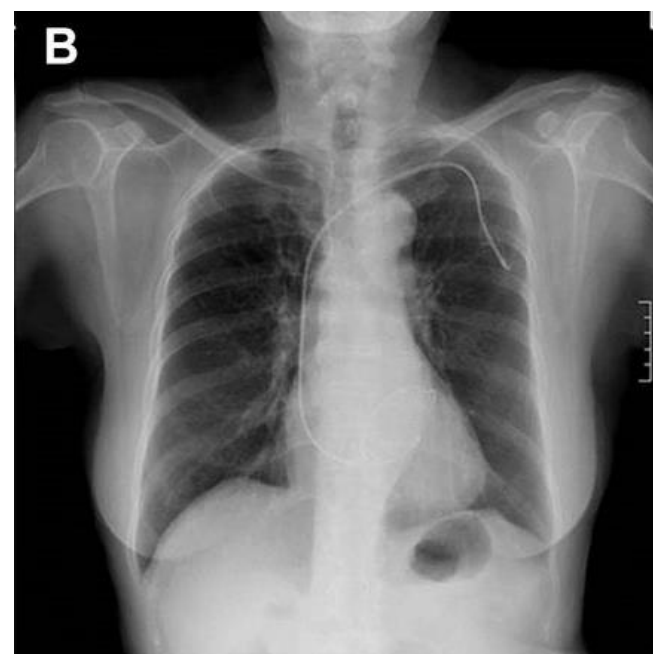
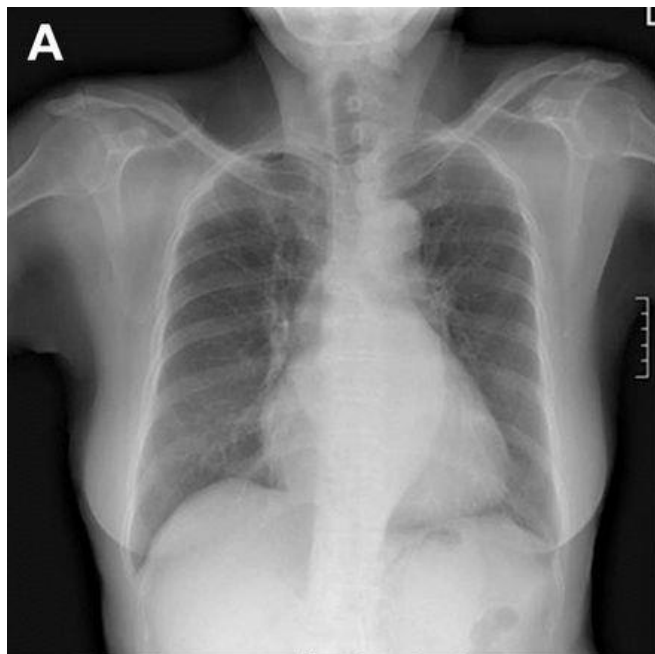
- ERO 0.10 cm²
- RV 23 ml
- Normal sinus R



- Mild MR
- Normal sinus R

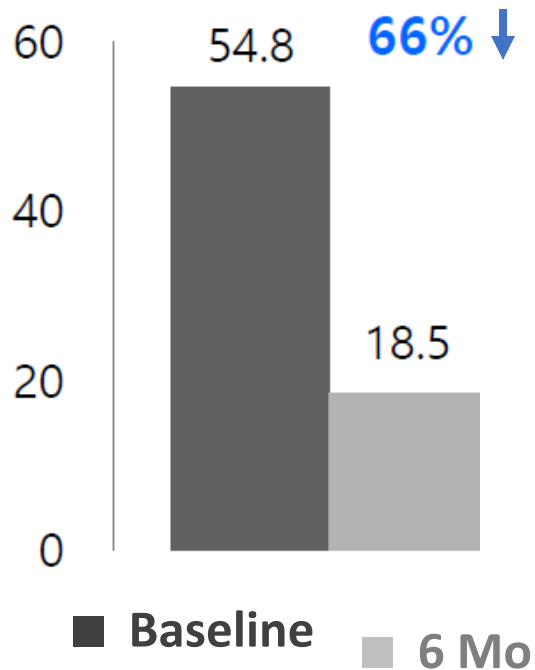
A Representative Case of MLC

74F, NICM, NYHA IV dyspnea despite aggressive medical therapy for 1yr

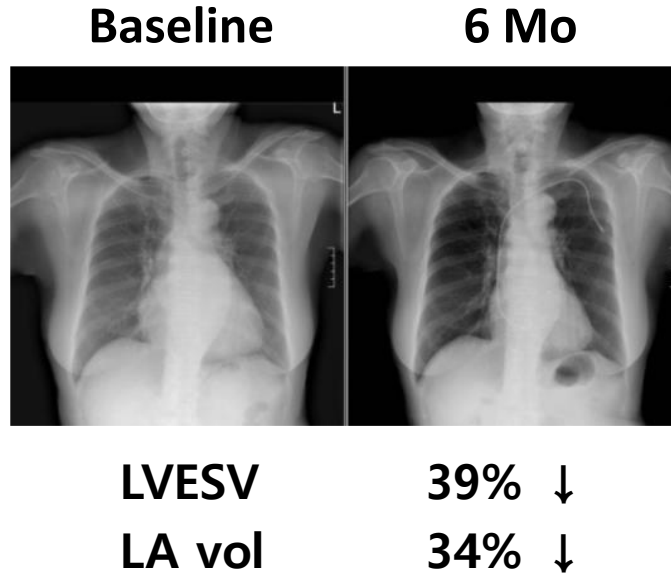


FIM result of Mitral Loop Cerclage (n=5)

(1) Regurgitant Volume (RV, mL)

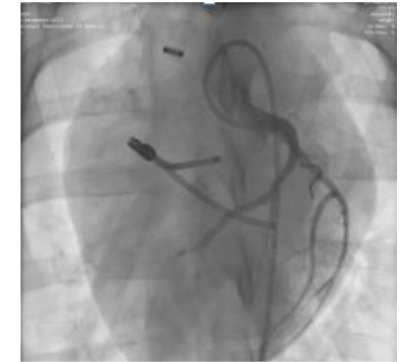

(2) Reverse remodeling

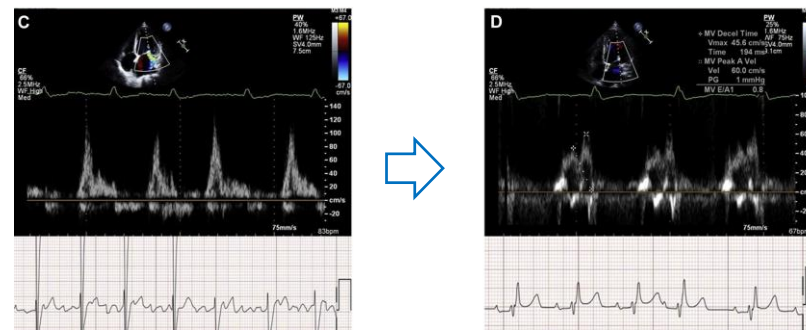


USA cerclage human trial in 2018

- NIH-Transmural IDE
- Intra-cardiac locking



(3) Electrical remodeling (n=2)



AF reverted to NSR in all cases of chr AF

2nd Clinical trial in Korea Underway

- Inclusion criteria
- Function MR with Chr AF

AFRICA study

: AF Reversion to sinus In Cerclage Annuloplasty

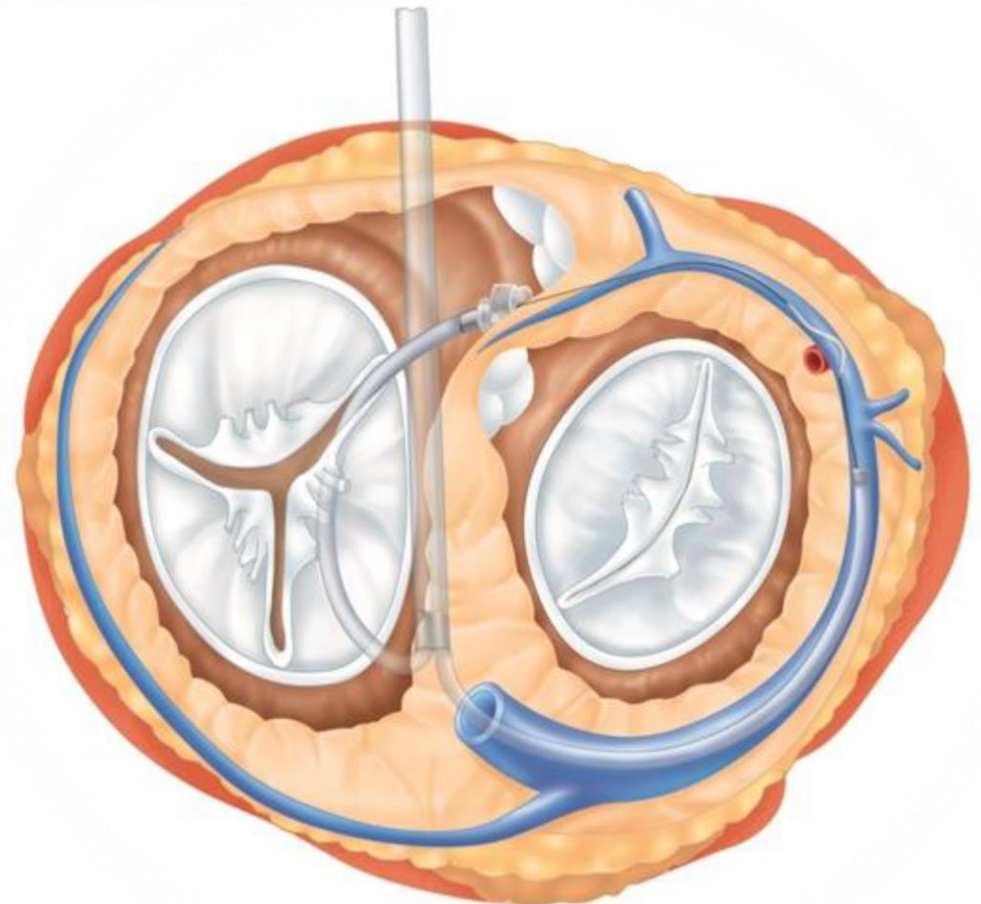
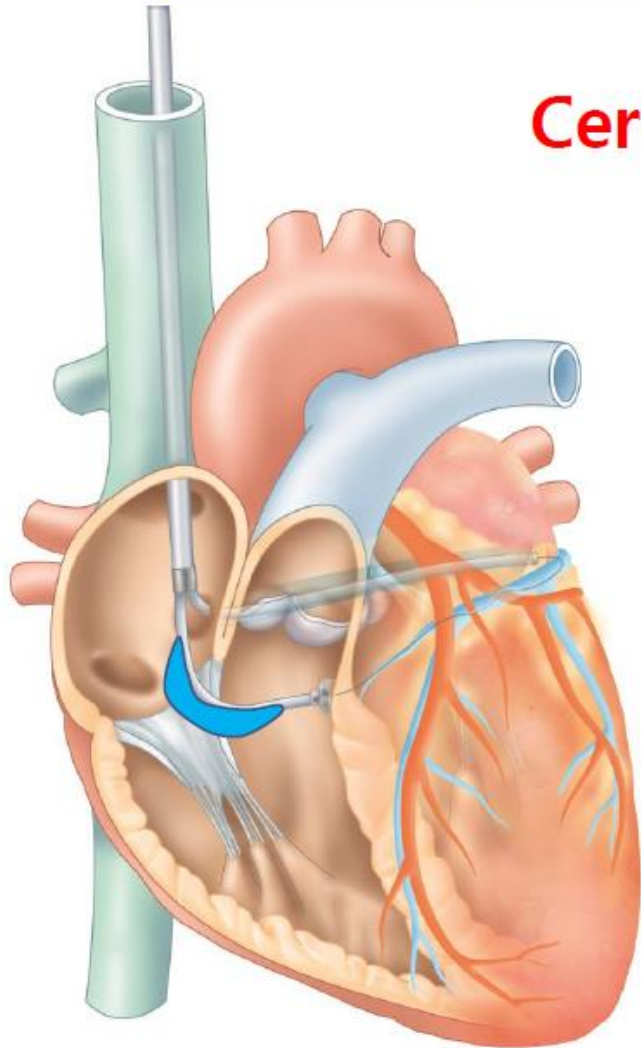
Extension of Mitral Loop Cerclage to treat TR

Mitral Loop Cerclage

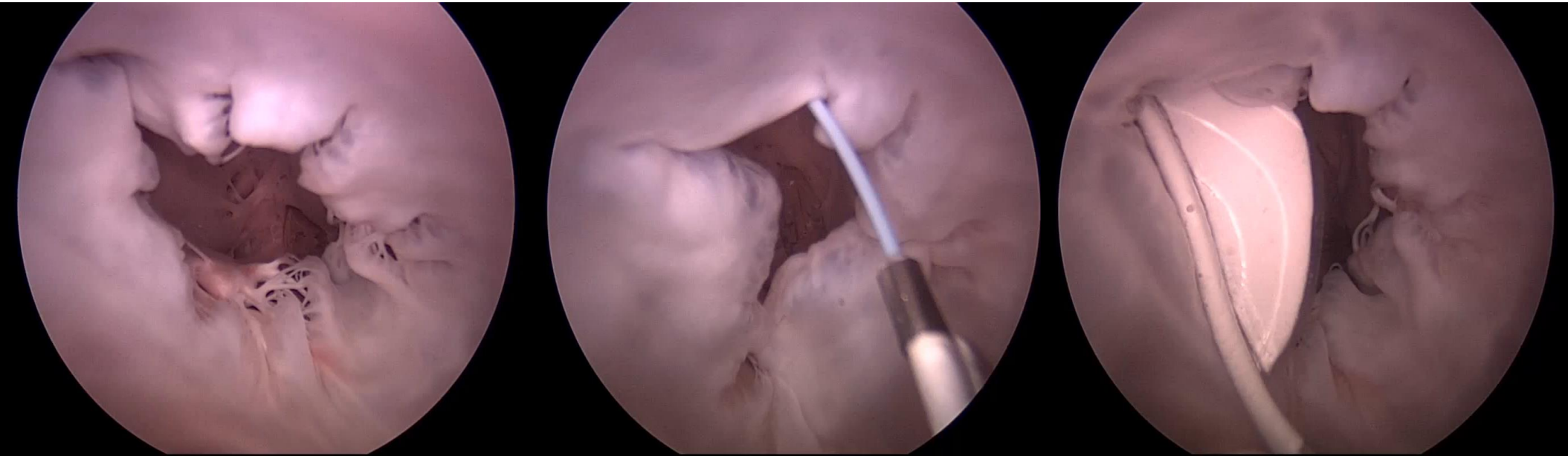
+

Septal leaflet extension on CSTV

Cerclage TR Block



Cerclage TR block for severe TR Functional TR model



Summary

- Mitral Loop Cerclage has shown significant reduction of functional MR & reverse remodeling of LV/LA
- Two studies for intracardiac locking and chronic AF
- Septal leaflet extension on Mitral Loop Cerclage may have potential to treat both MR/TR simultaneously

Thank you for your attention

