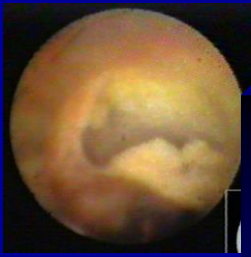
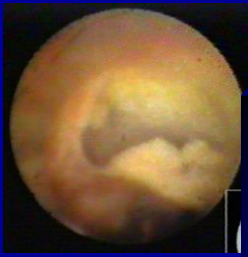


How to cross collateral channels

Ishikiri Seiki Hospital
Cardiovascular Division
Koshi Matsuo



I, Koshi Matsuo have nothing to disclose.



Wires for channel tracking

What kinds of wires should we use?

- Fielder FC
- SION, SION Blue, SION Black
- Fielder XT-R
 - SUOH
 - SUOH03



Septal channel

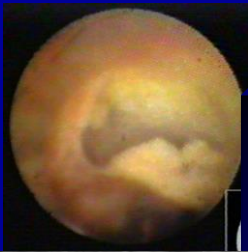Firstly you should choose septal channel.

Septal channel is safer compared with other channels.

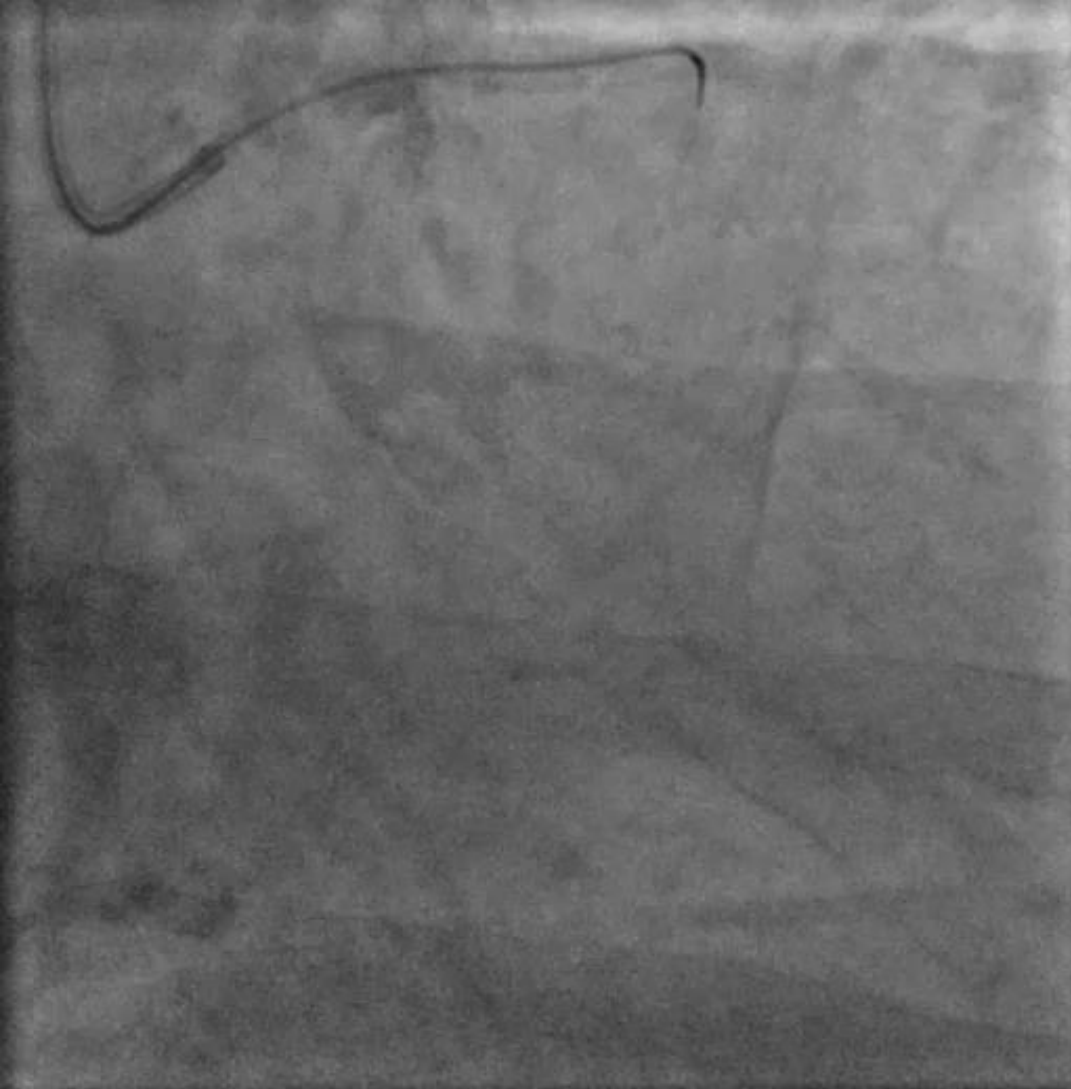
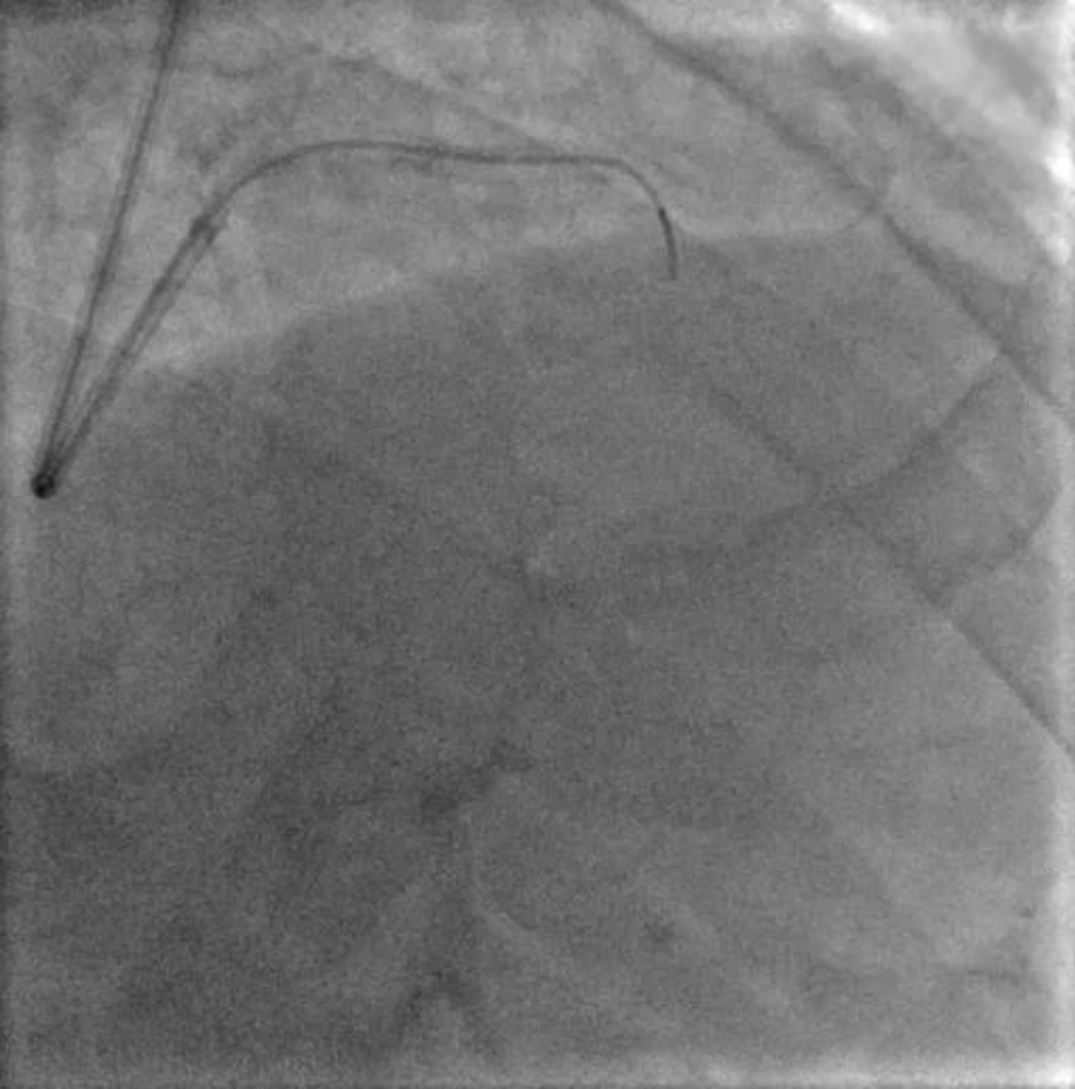
You should take angiogram both RAO cranial and caudal view.

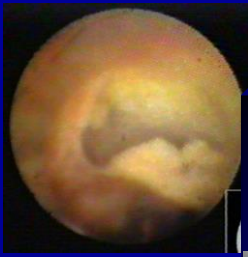You should choose straight channel as possible as you can.

Sometimes, we can cross misty channel using Fielder XT-R.

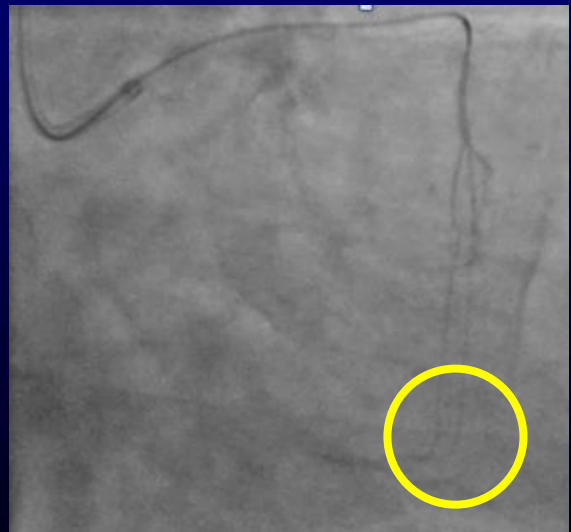
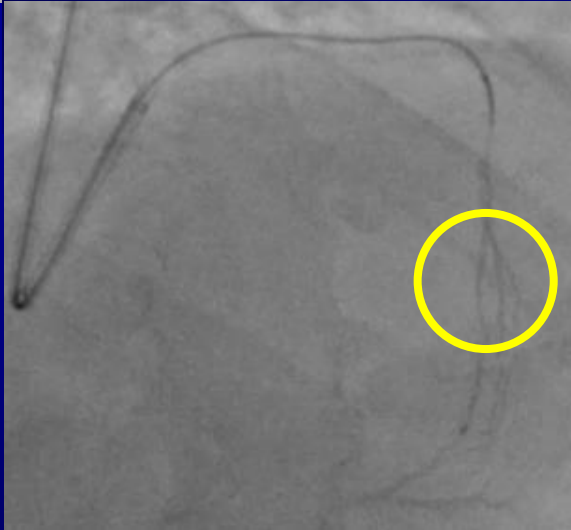


Septal channel

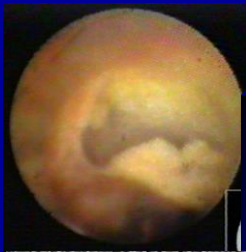



Septal channel




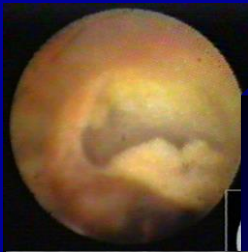
We must take both angiogram RAO Cranial and RAO Caudal view to asses we can use or not for retrograde approach.



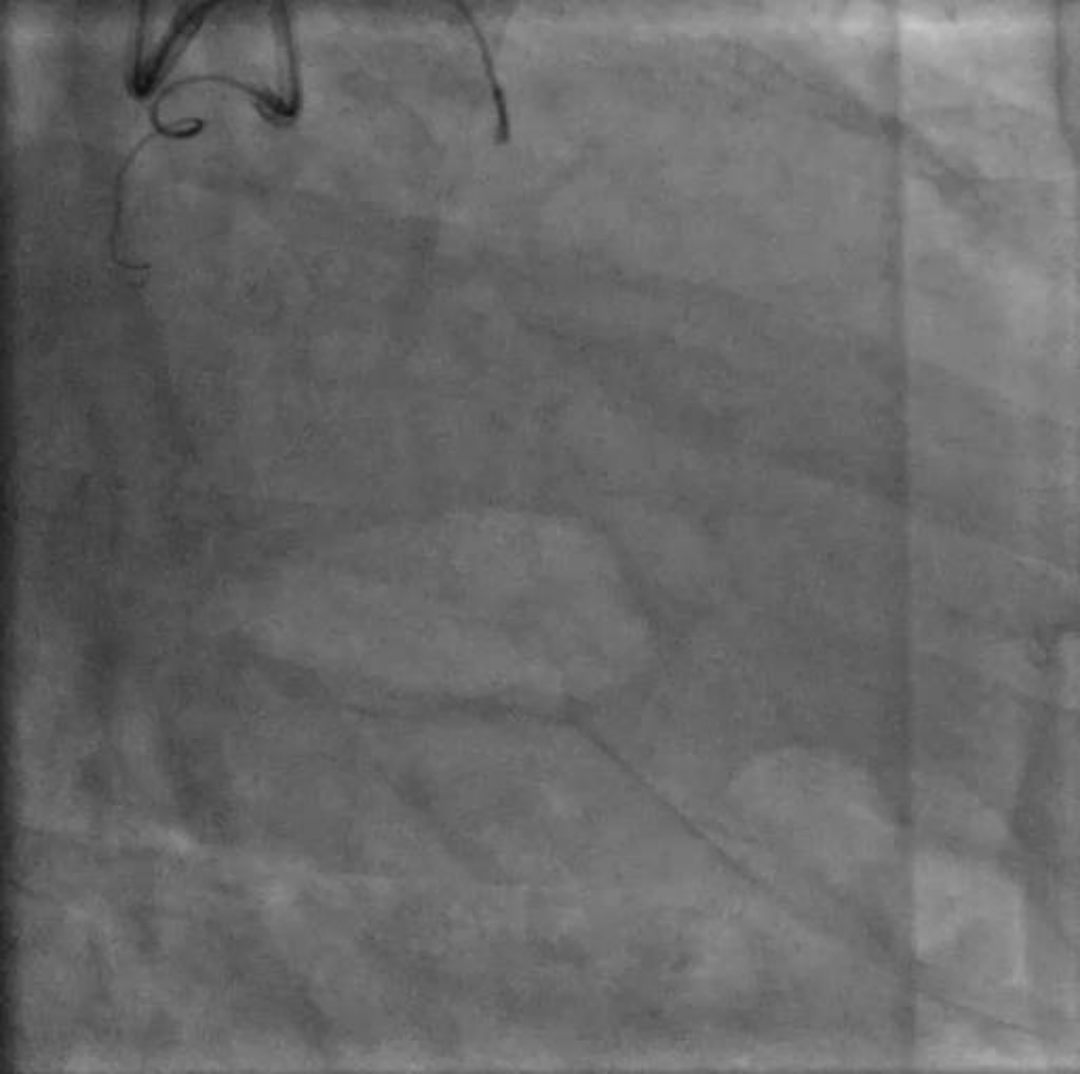
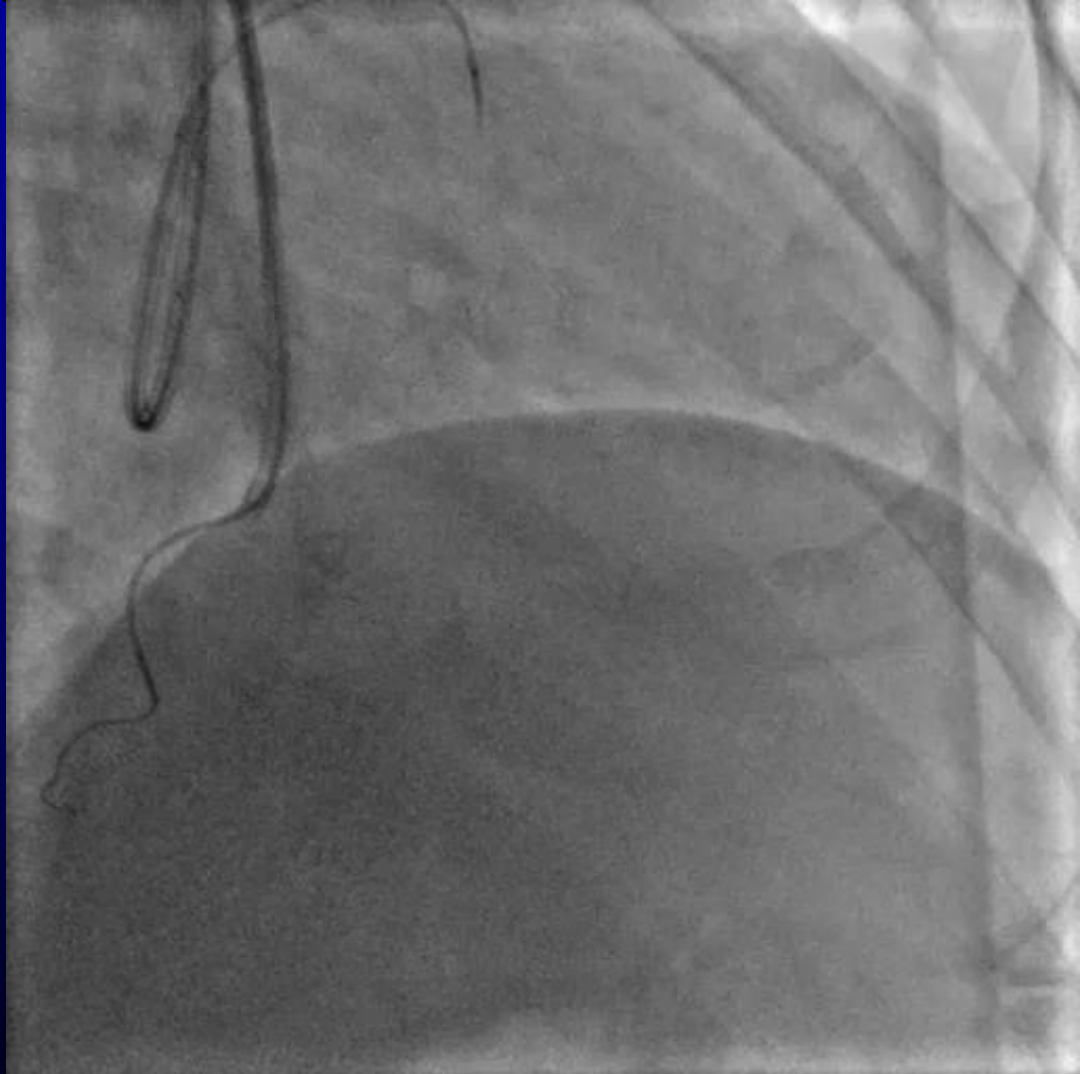
Septal channel

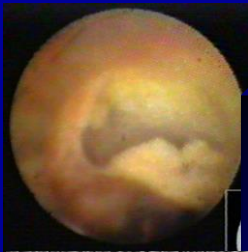
Corsair 150cm with SION






Septal channel





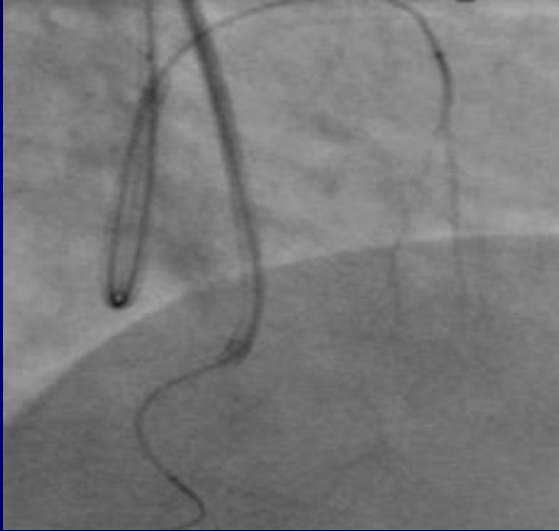Septal channel

Corsair 150cm with XT-R

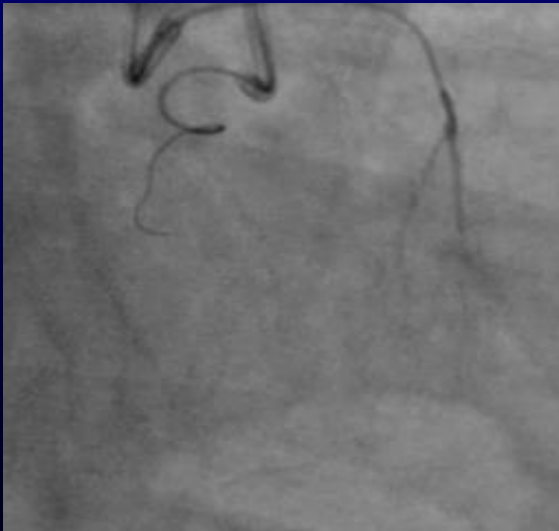



Septal channel

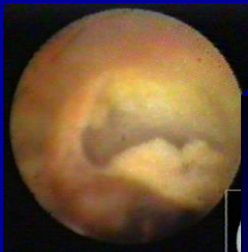


Sometimes we can cross misty septal channel using XT-R.



Sometimes it is difficult to advance Corsair after crossing the wire. Like this situation lower profile microcatheter is useful, for example Finecross and Caravel.

Using Corsair 135cm firstly is sometimes useful like this case.

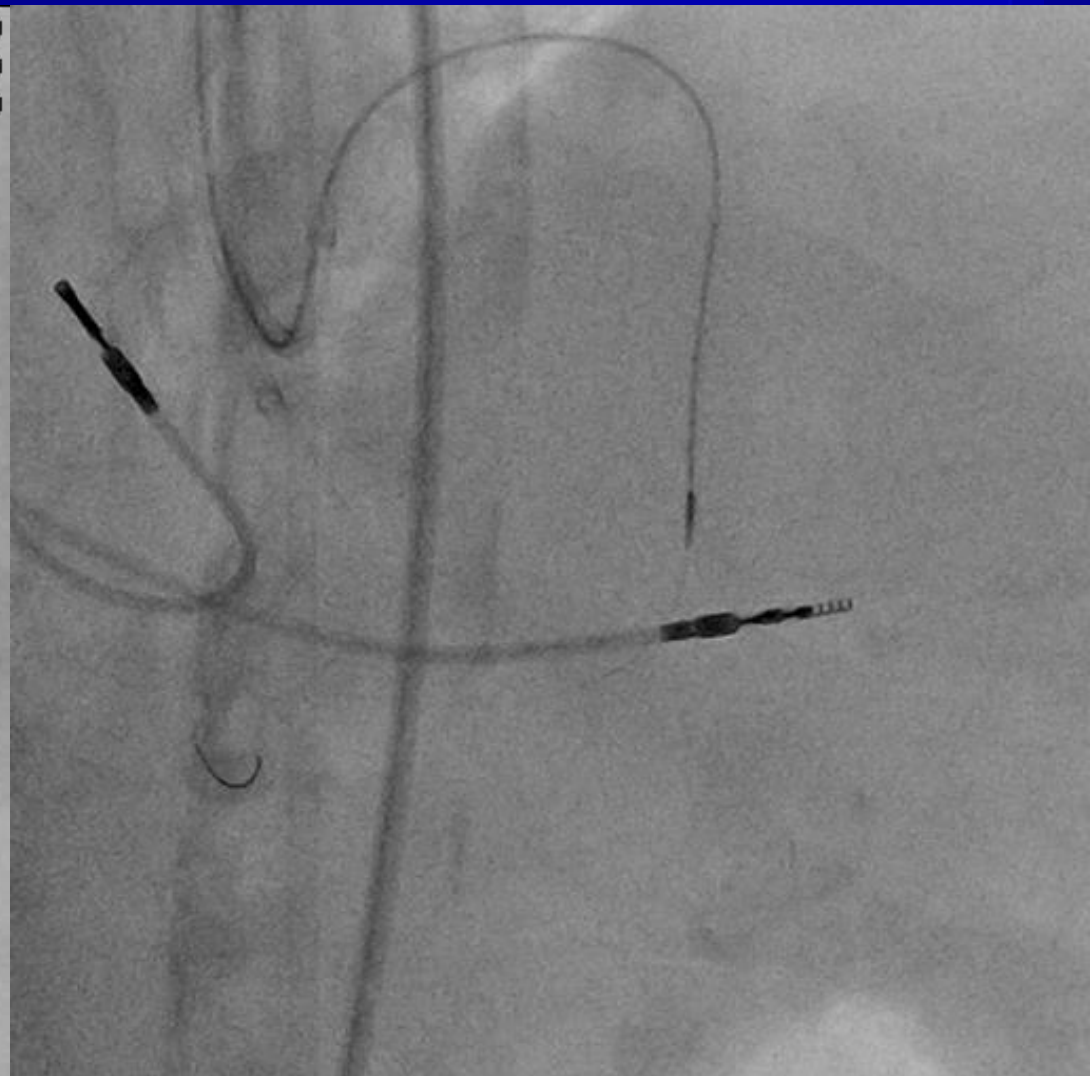
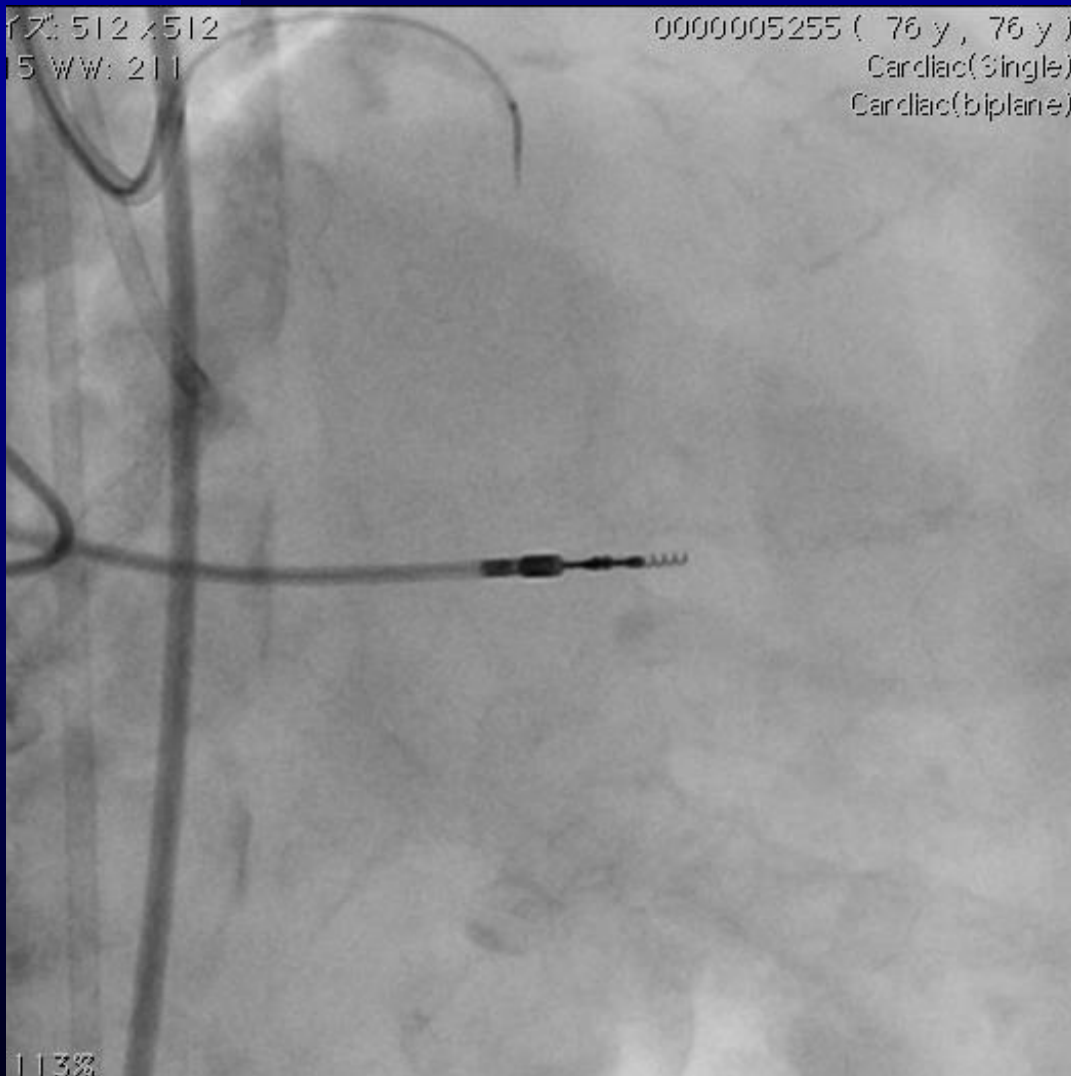


Septal channel

Corsair 150cm with SUOH03

7: 512 x 512
15 WW: 211

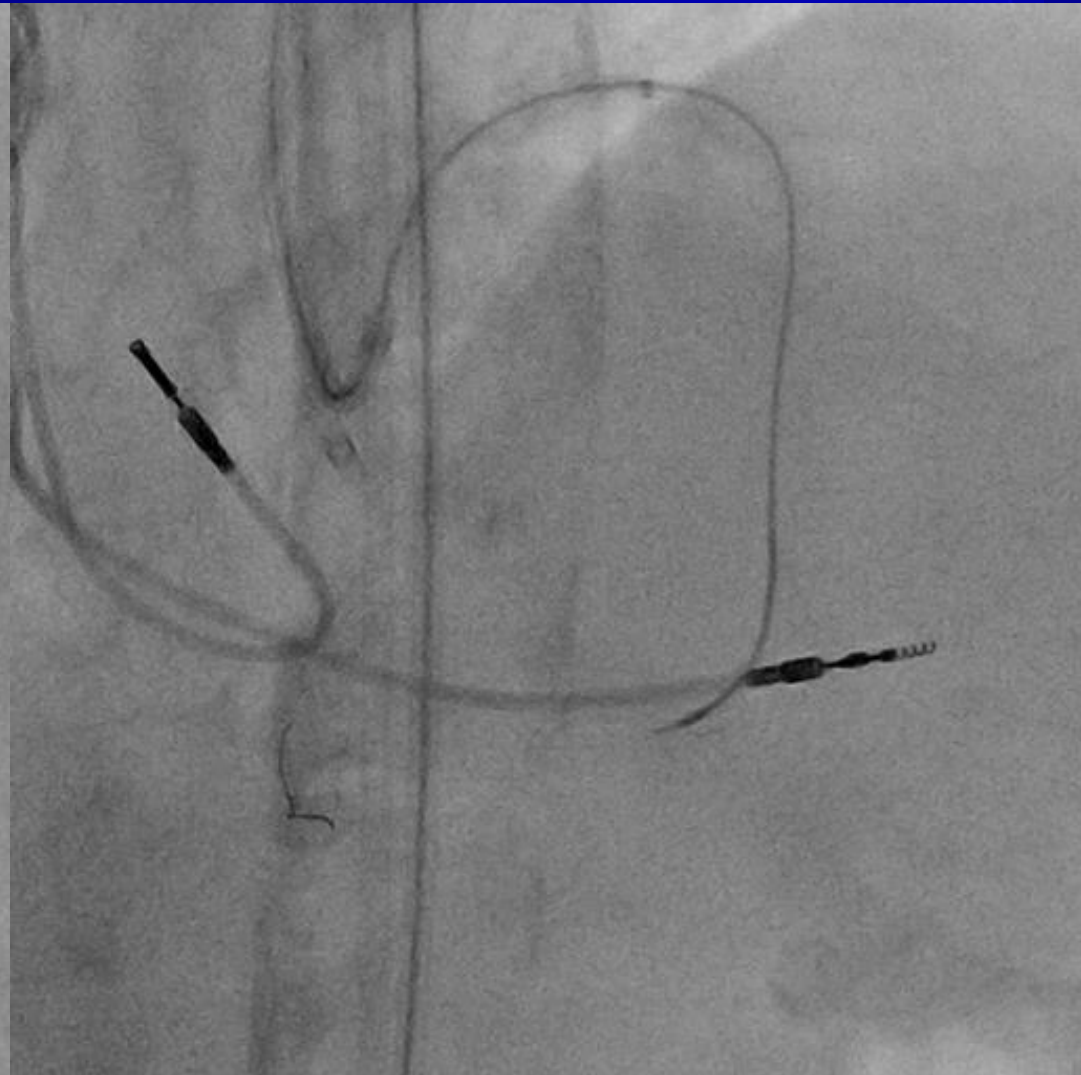
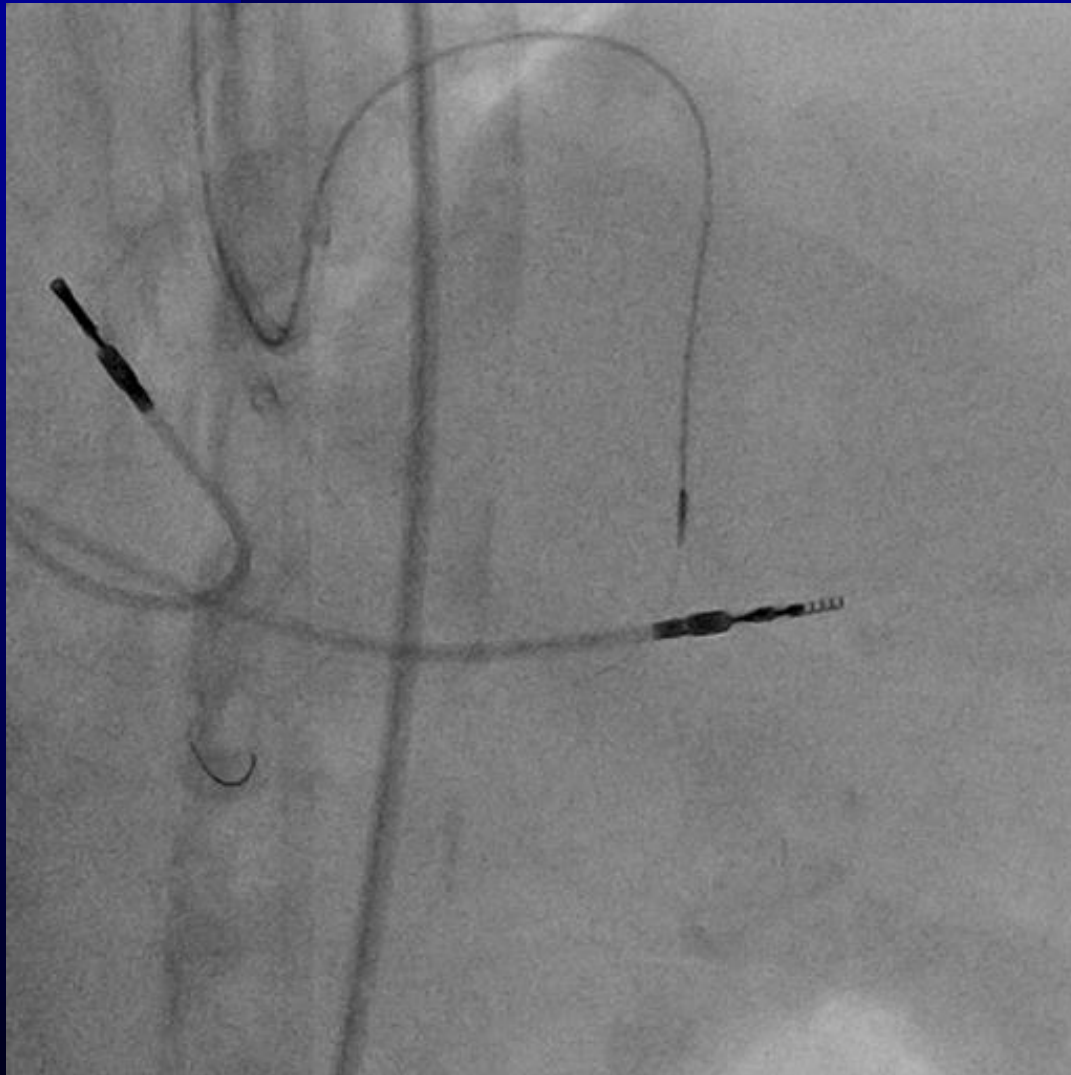
0000005255 (76 y , 76 y)
Cardiac(Single)
Cardiac(biplane)





Septal channel

Corsair 135cm with SUOH03 supported with 6Fr Guideliner





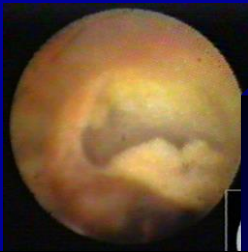Epicardial channel

You should advance wire and micro catheter carefully.

Epicardial channel is more risky compared with other channels.

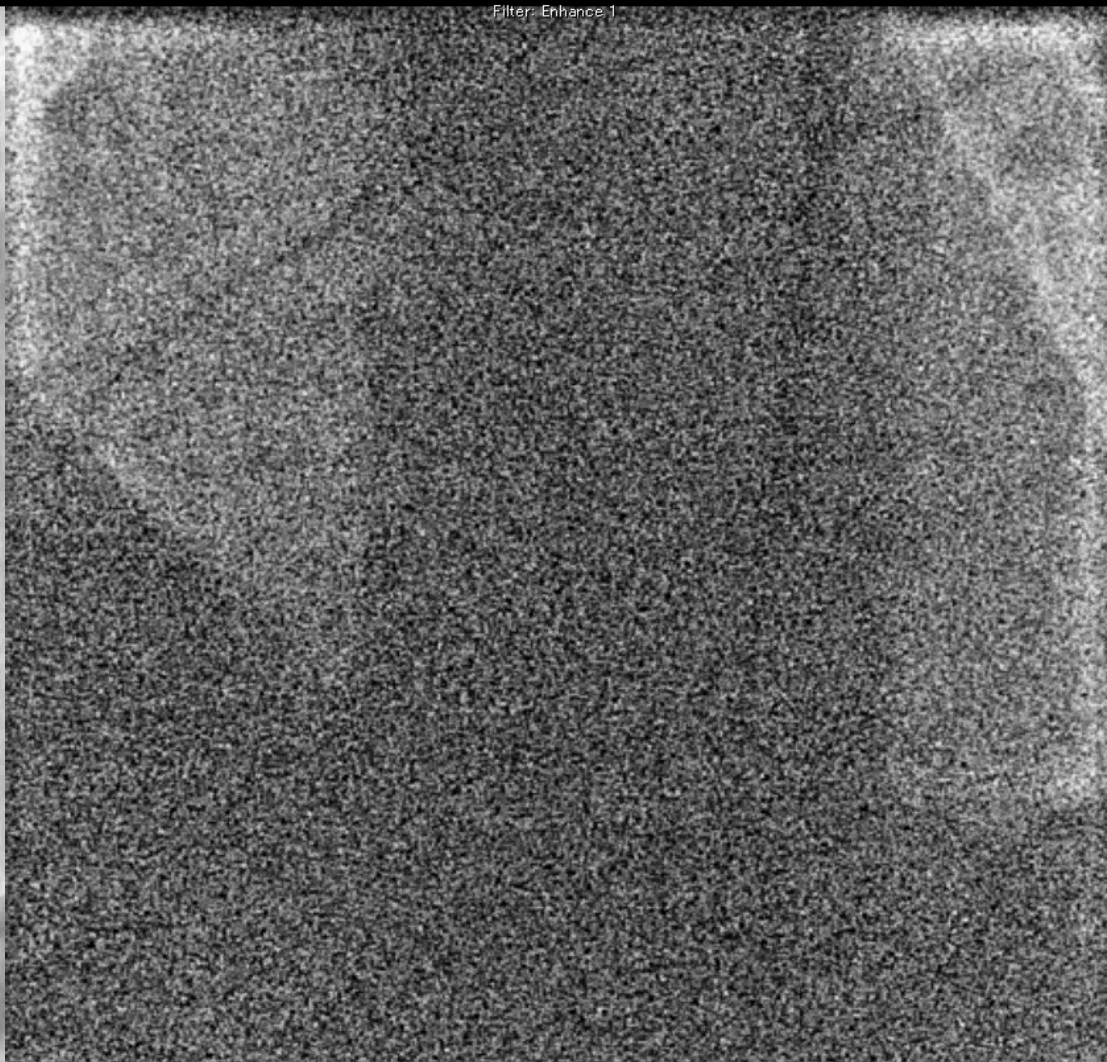
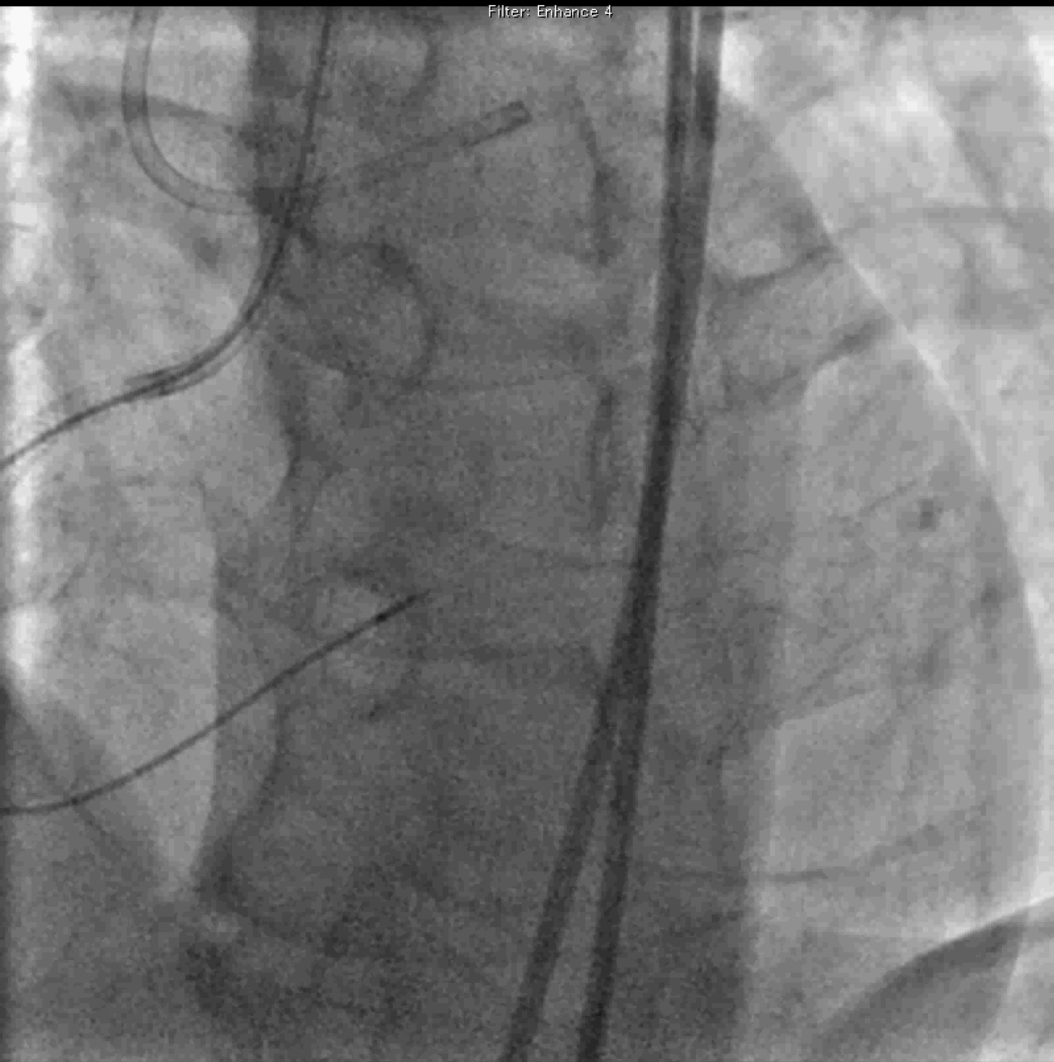
You should take angiogram both RAO cranial (caudal) and LAO cranial (caudal).

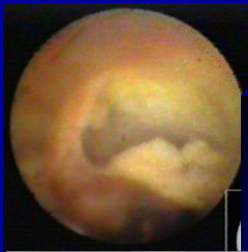
You can cross epicardial channel careful wiring and carefully advance microcatheter even though channel is so tortuous.



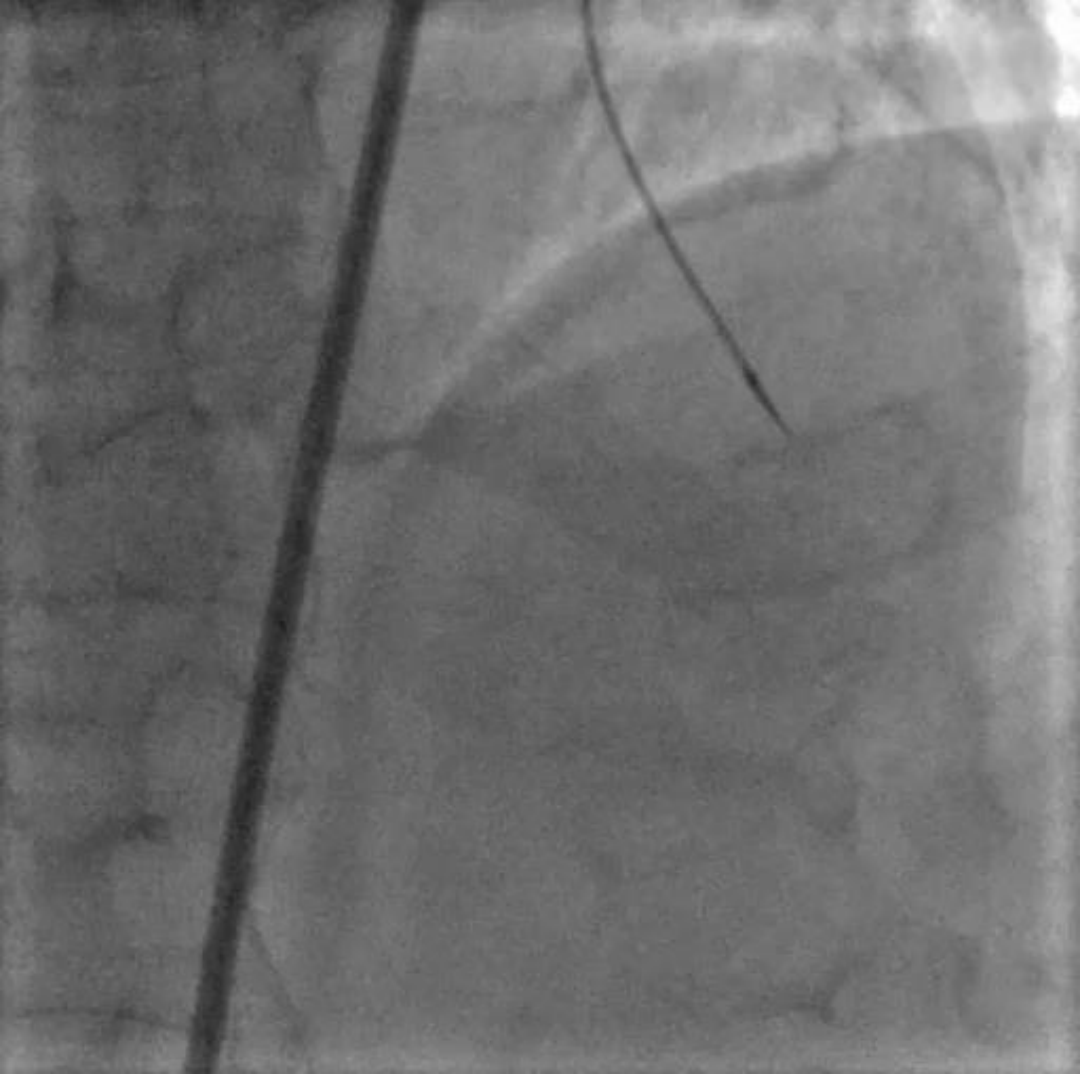
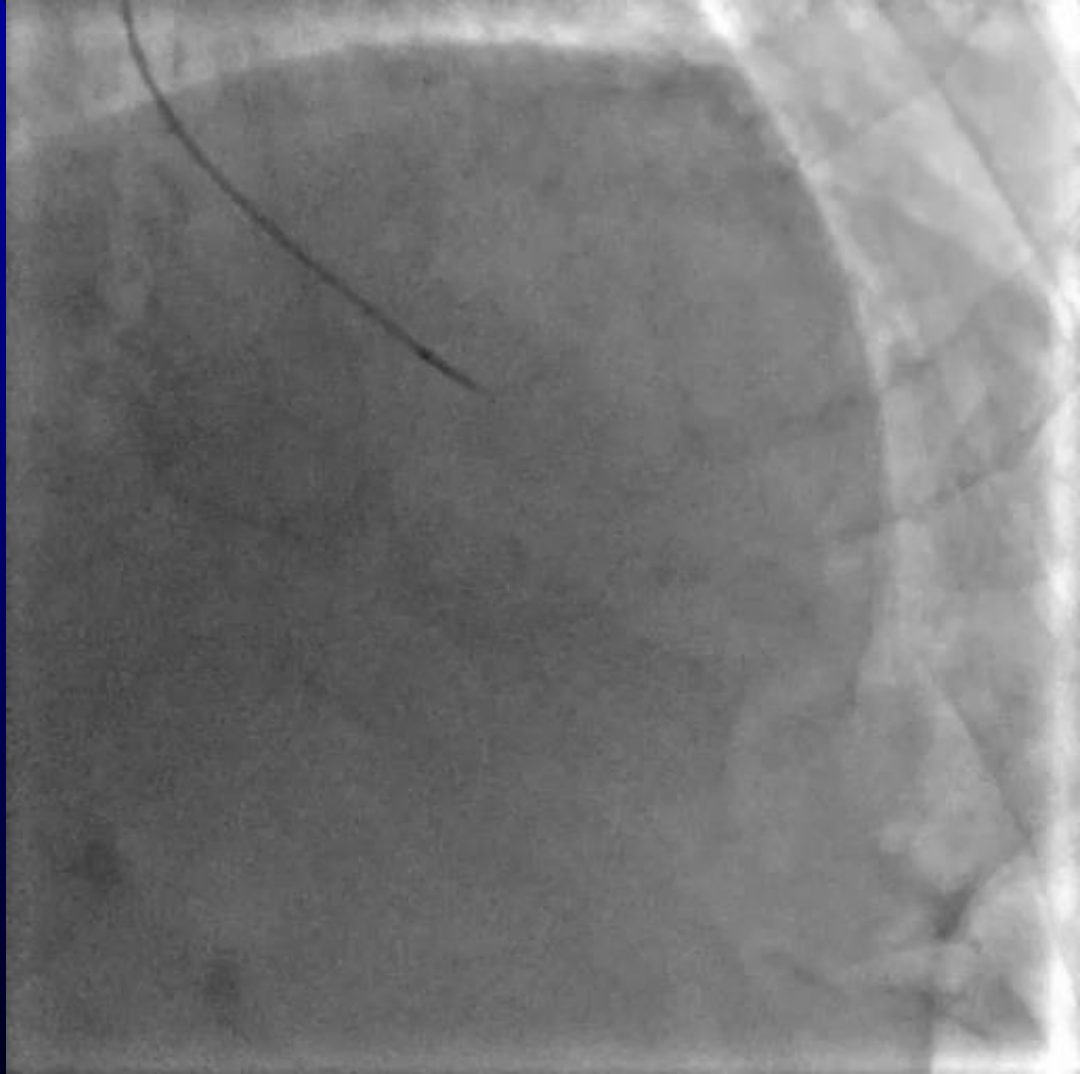
Epicardial channel

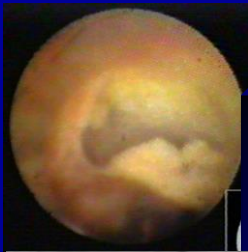
Corsair 150cm with SION





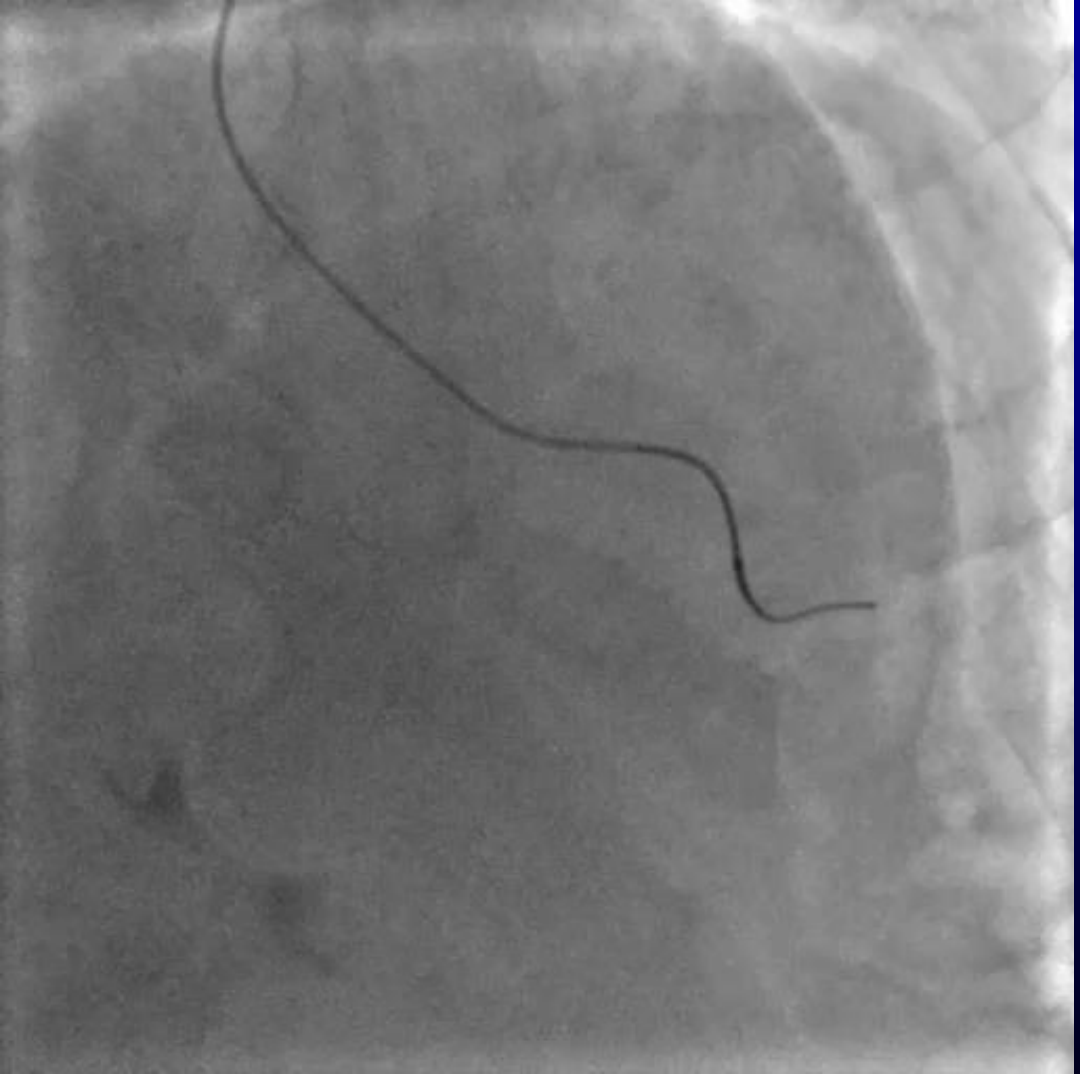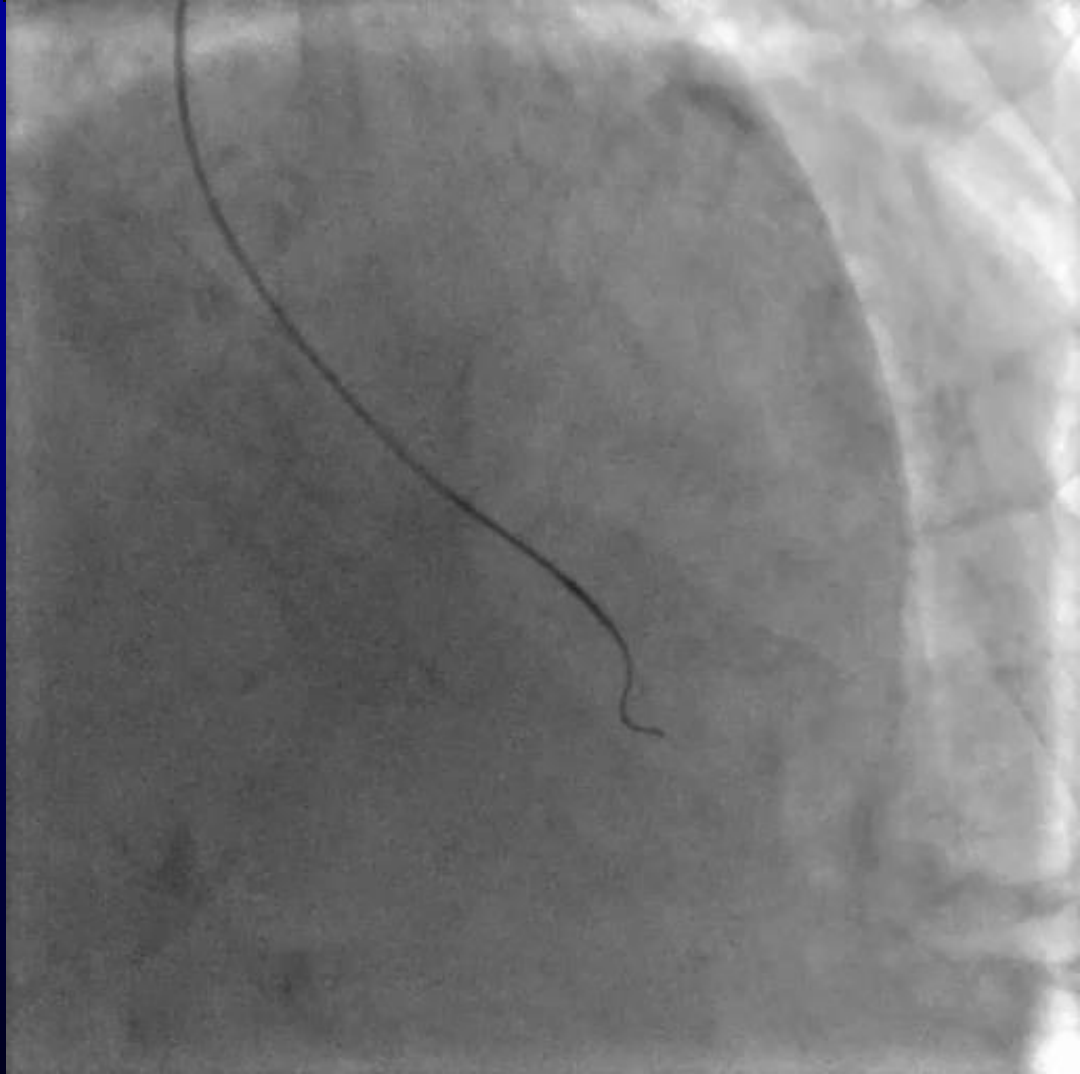
Epicardial channel

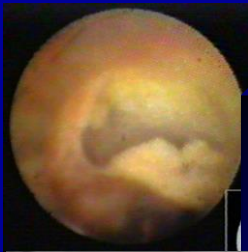



Epicardial channel

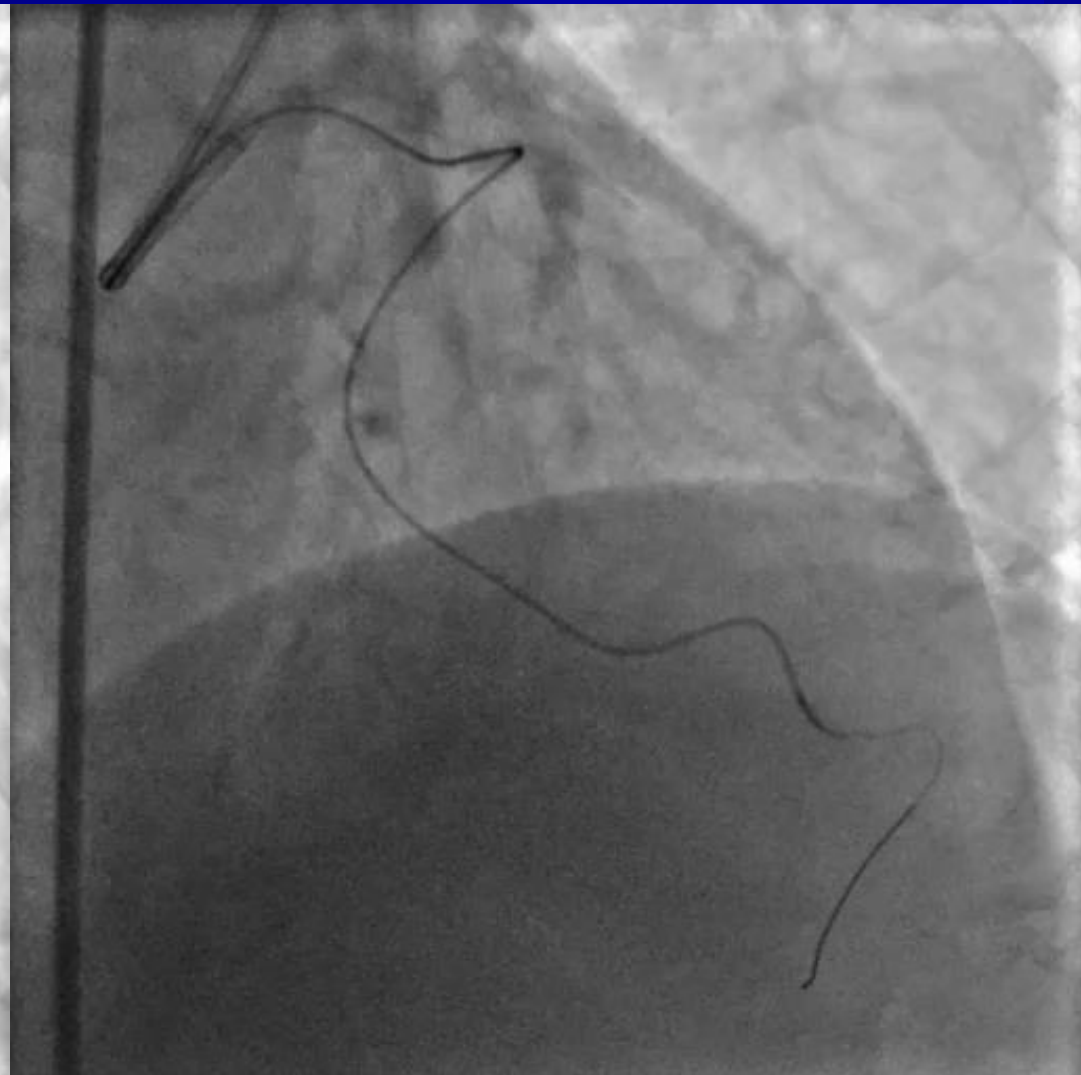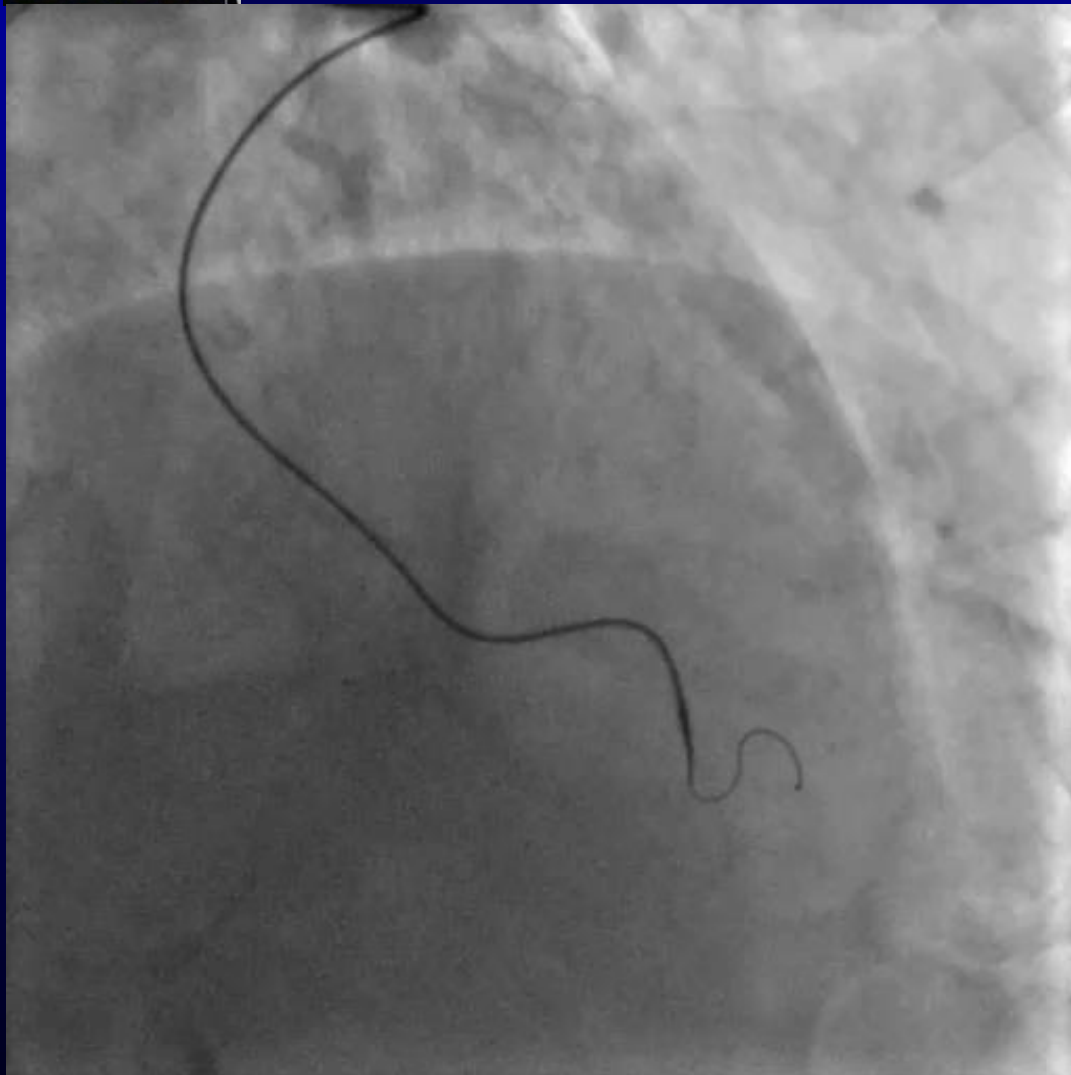
Corsair 150cm with SION

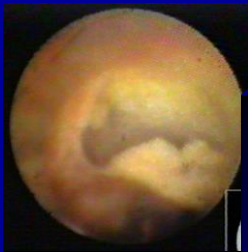




Epicardial channel

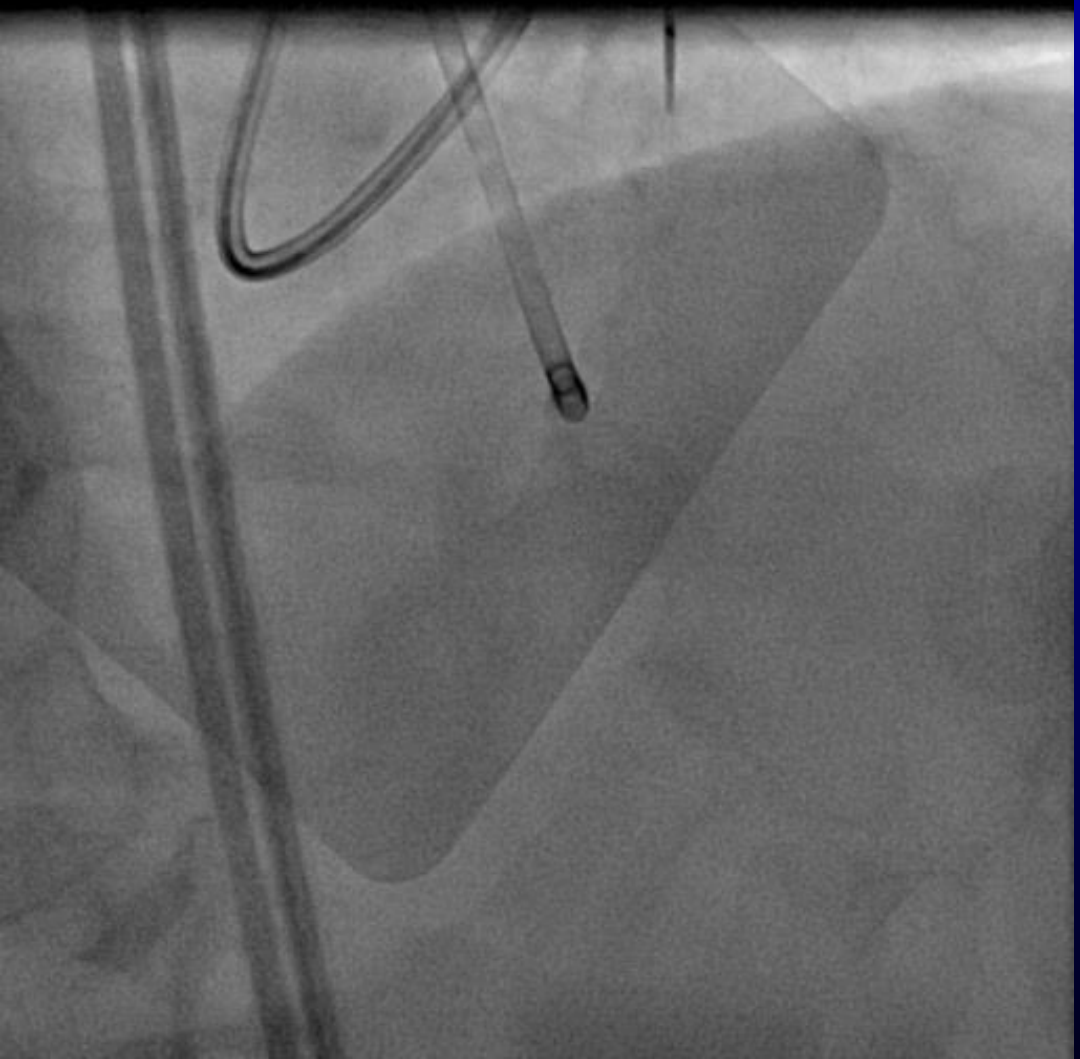
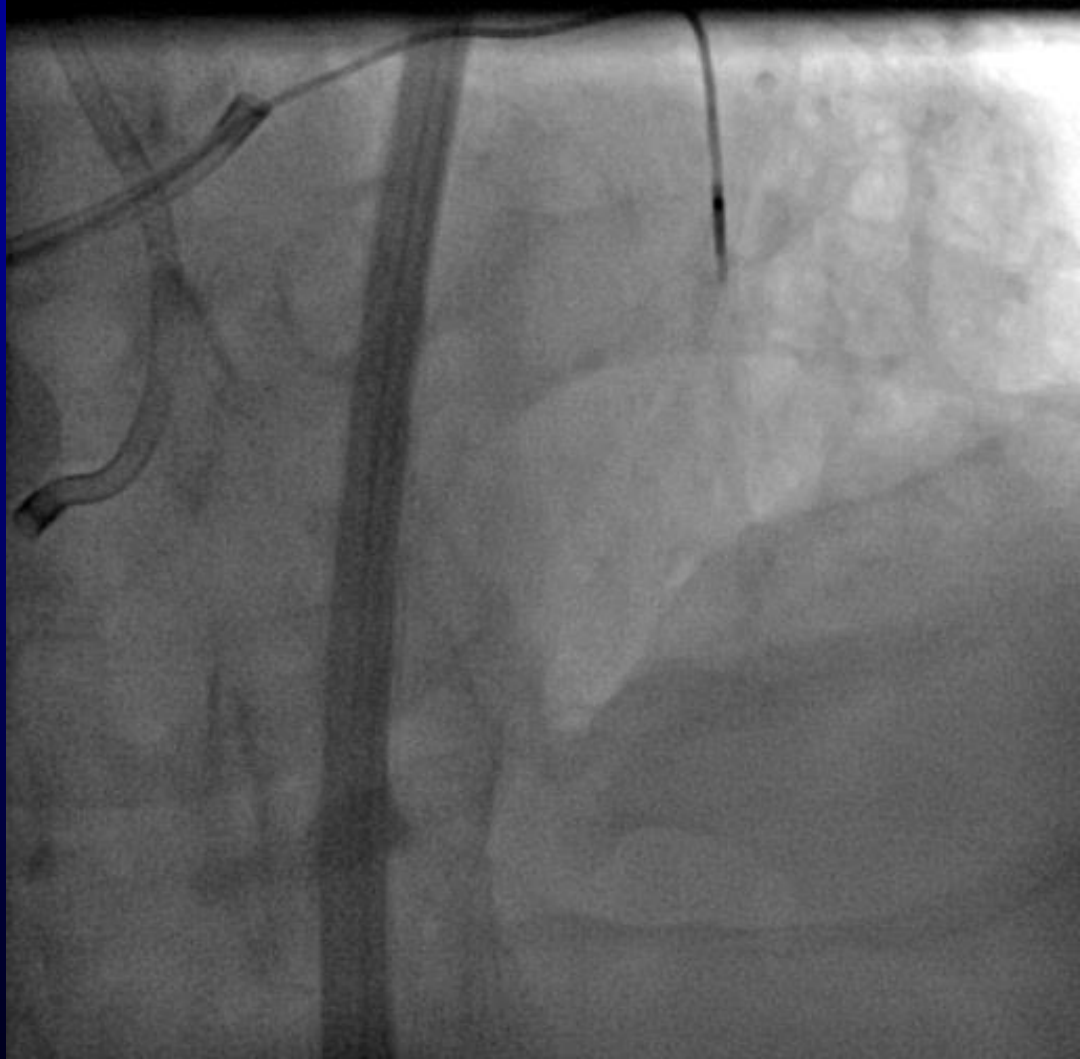
Corsair 150cm with SION





Epicardial channel

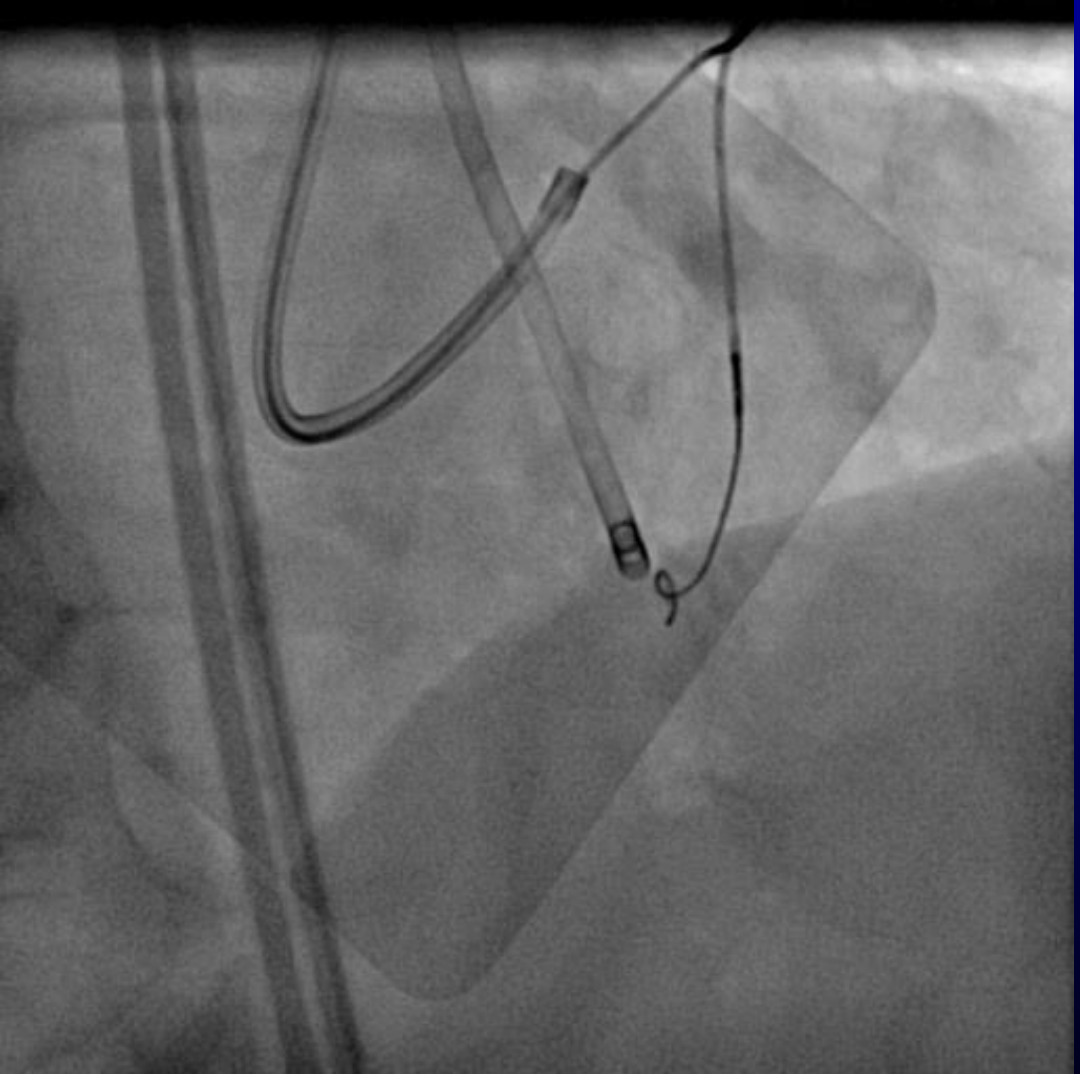
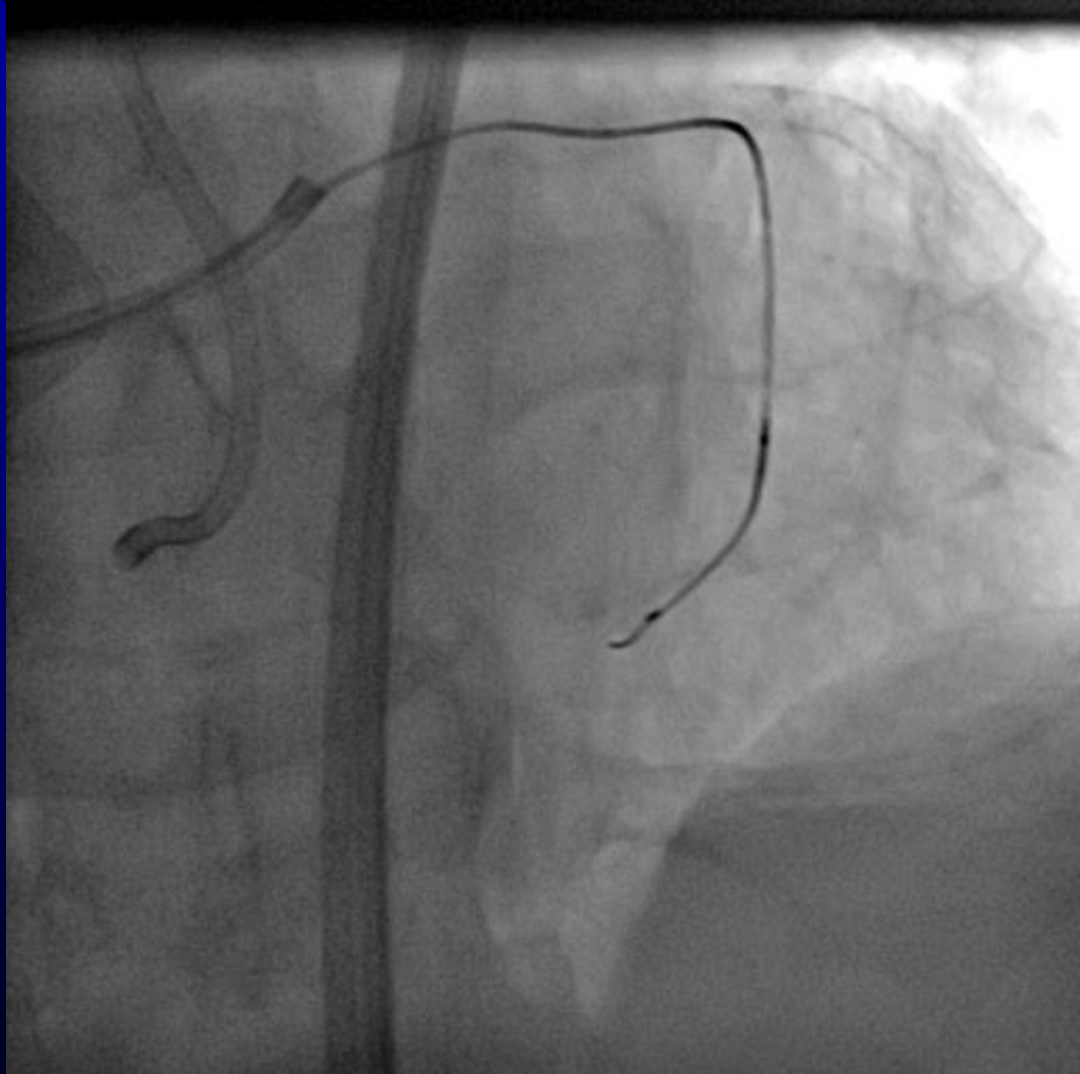
Corsair 150cm with SION





Epicardial channel

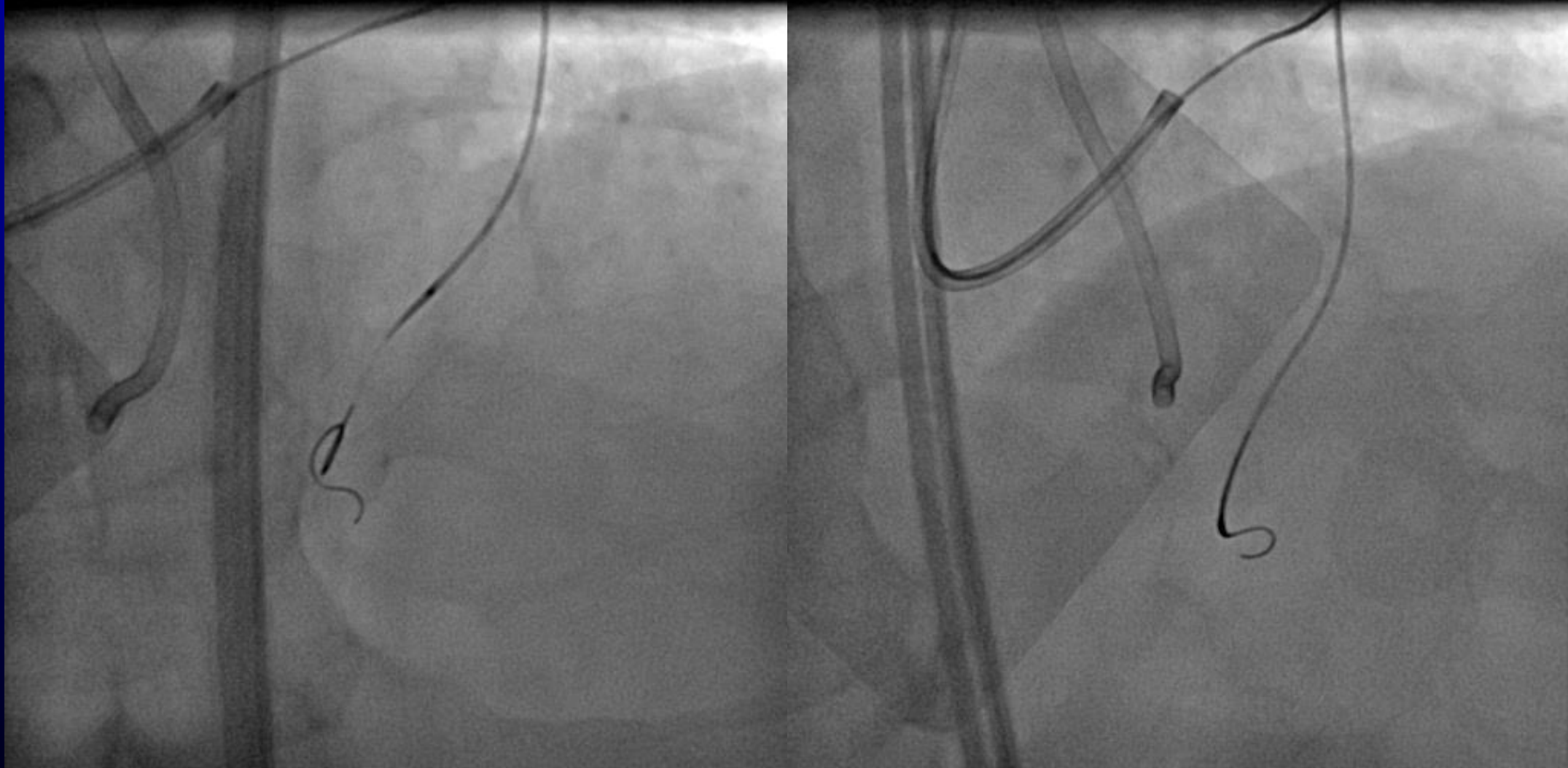
Corsair 150cm with SION





Epicardial channel

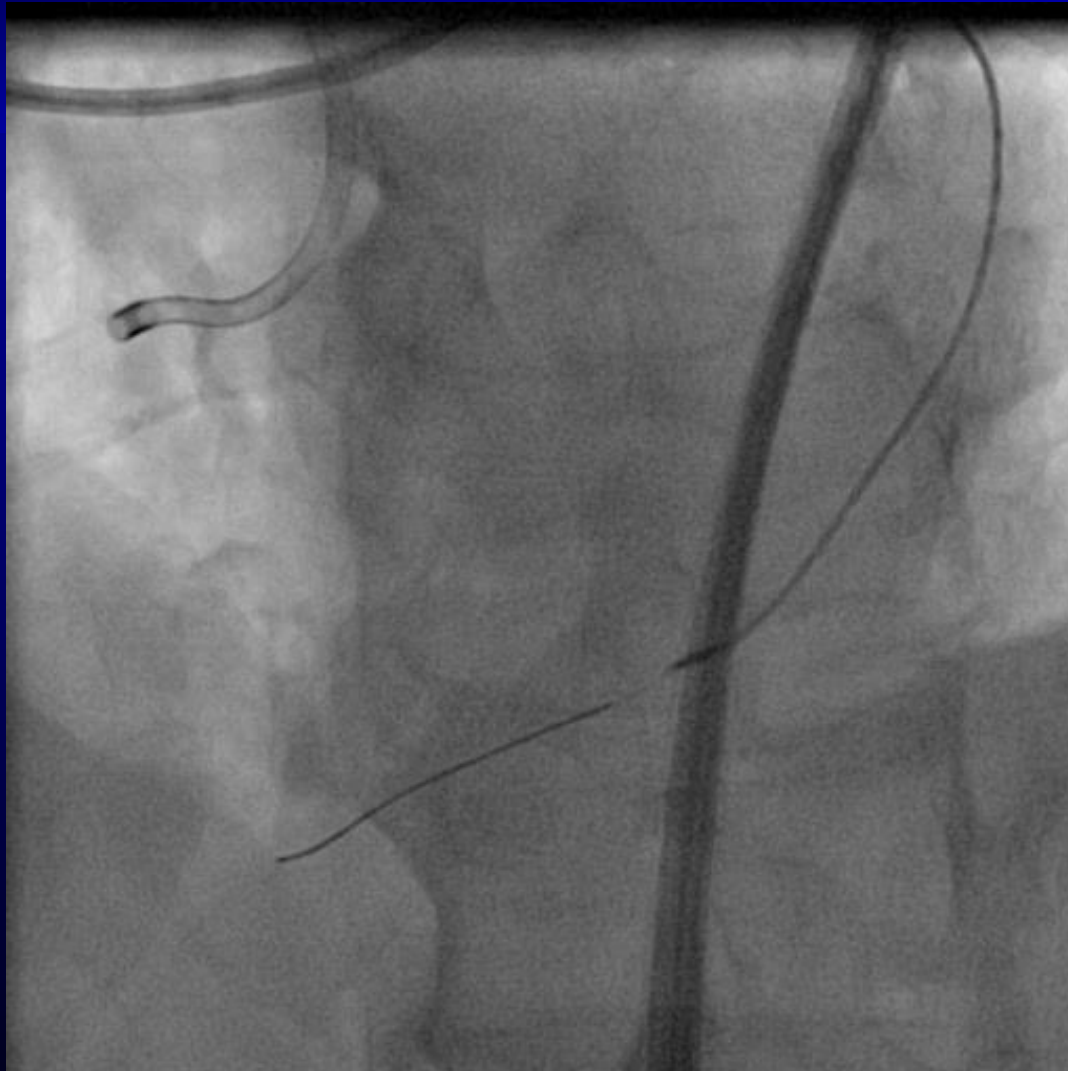
Corsair 150cm with SION





Epicardial channel

Corsair 150cm with SION



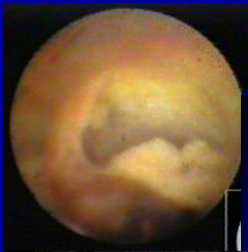

Epicardial channel

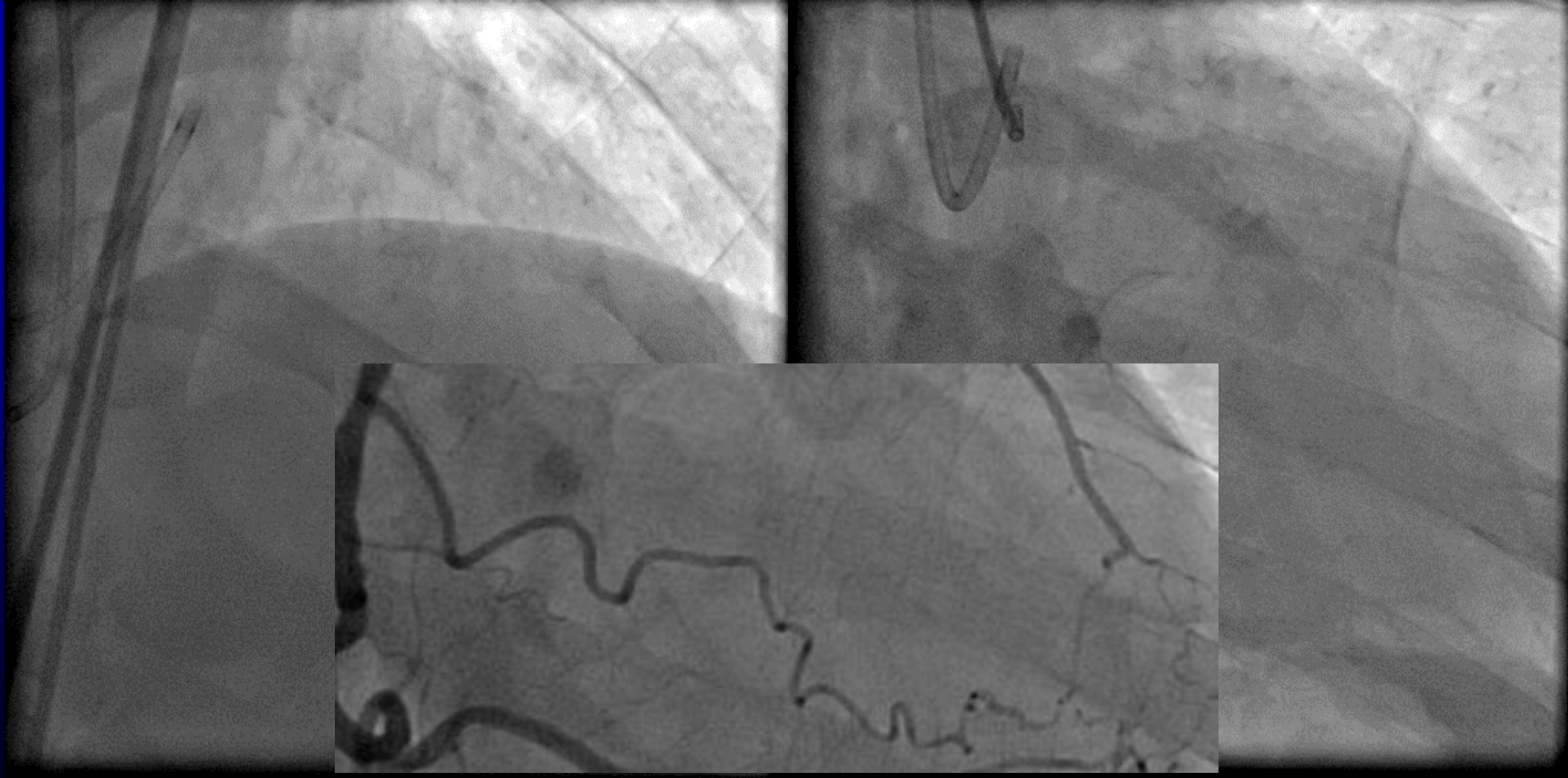
You should check wire route again and again, because advancing the wire and micro-catheter stretch collateral channel.

You must not advance micro-catheter strongly even though after crossing the wire.

You should advance micro-catheter gently and gradually.



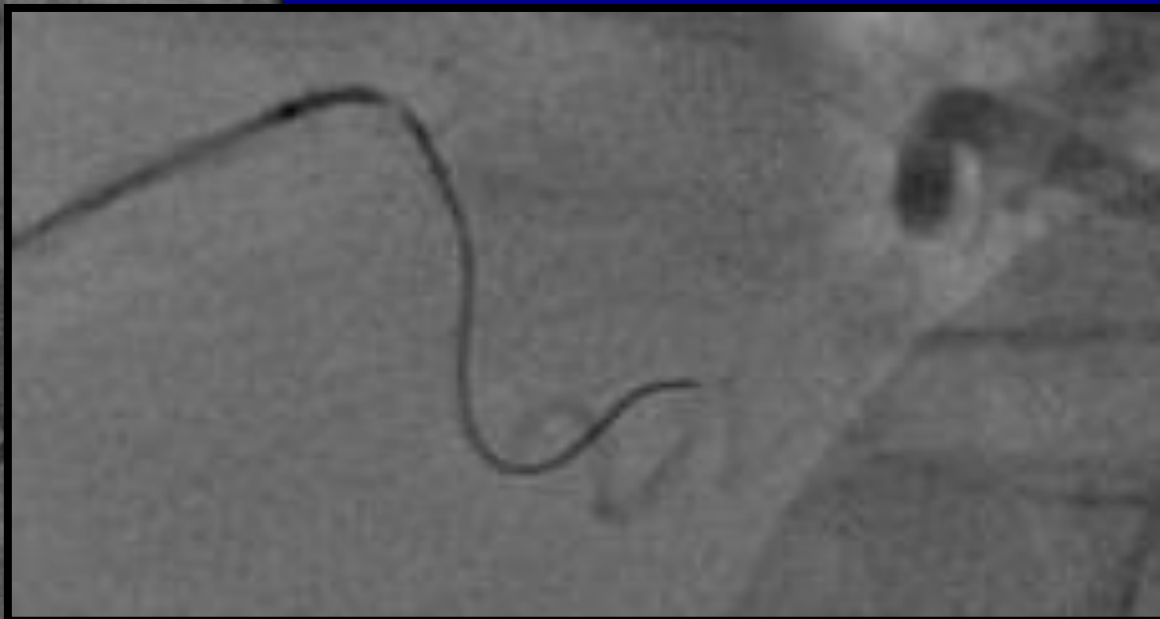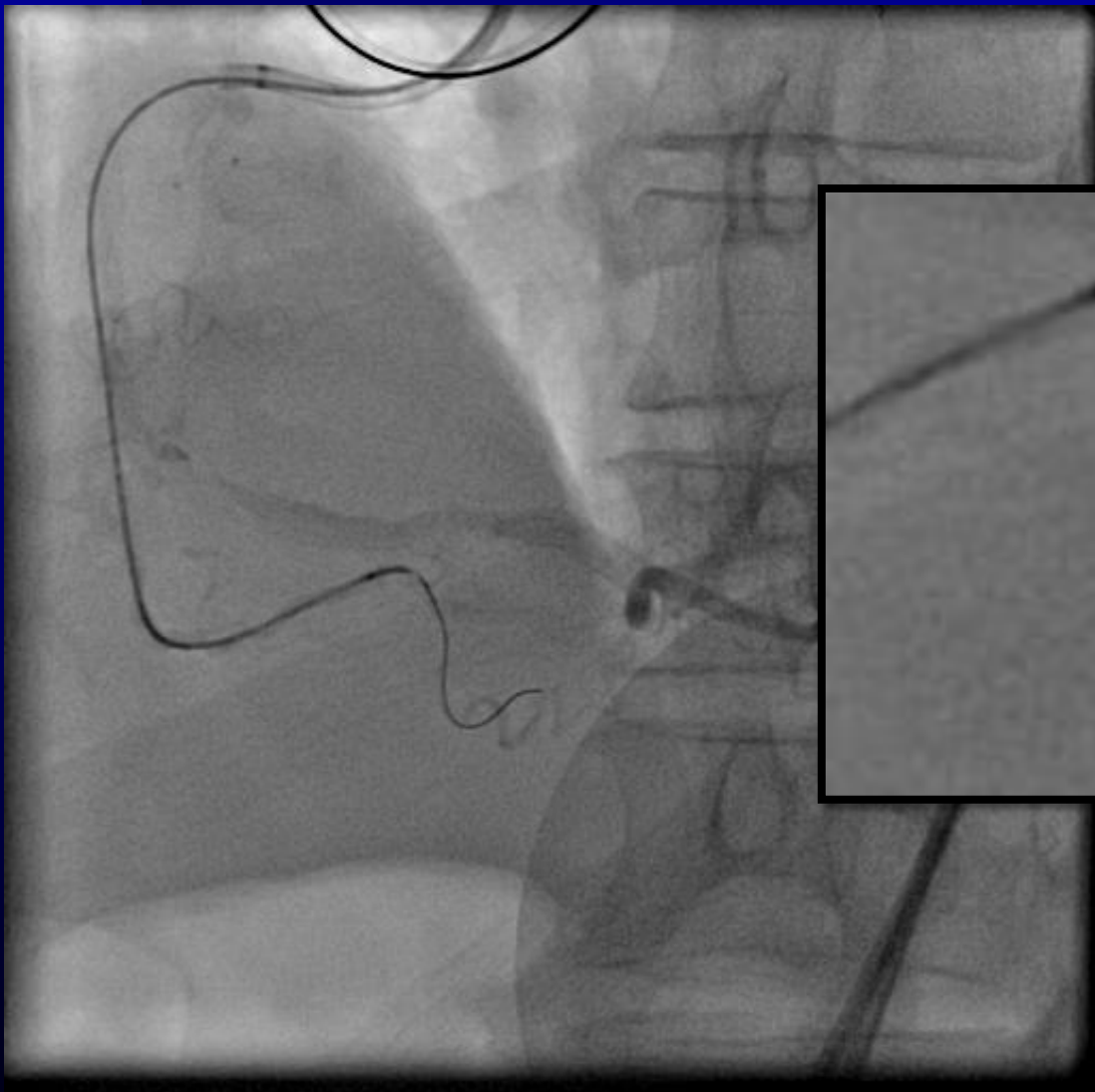
Epicardial channel





Epicardial channel

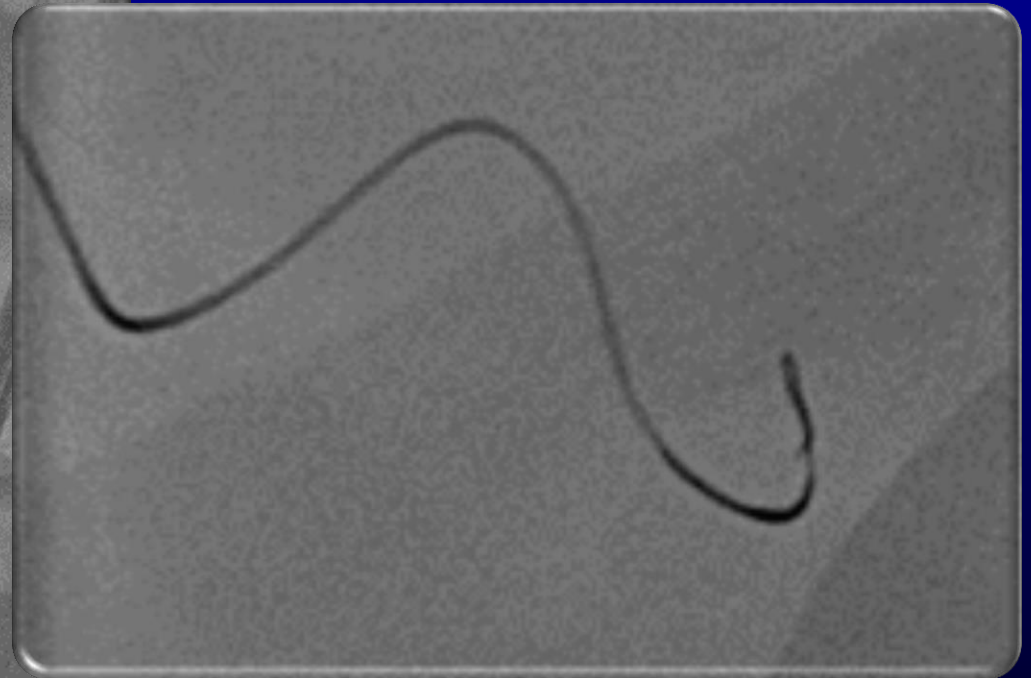
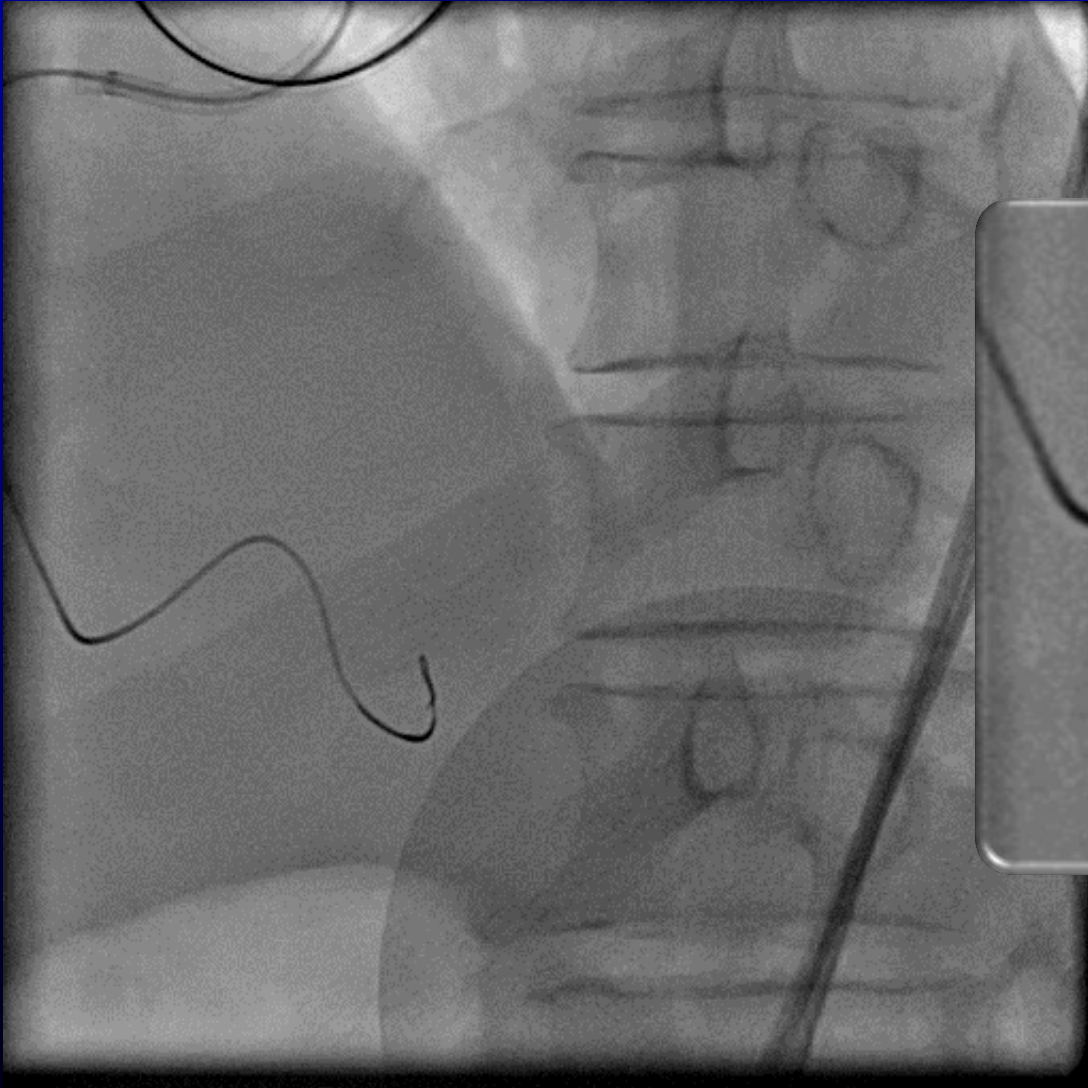
Corsair 150cm with SION

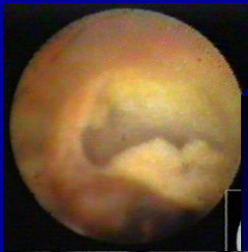



Epicardial channel

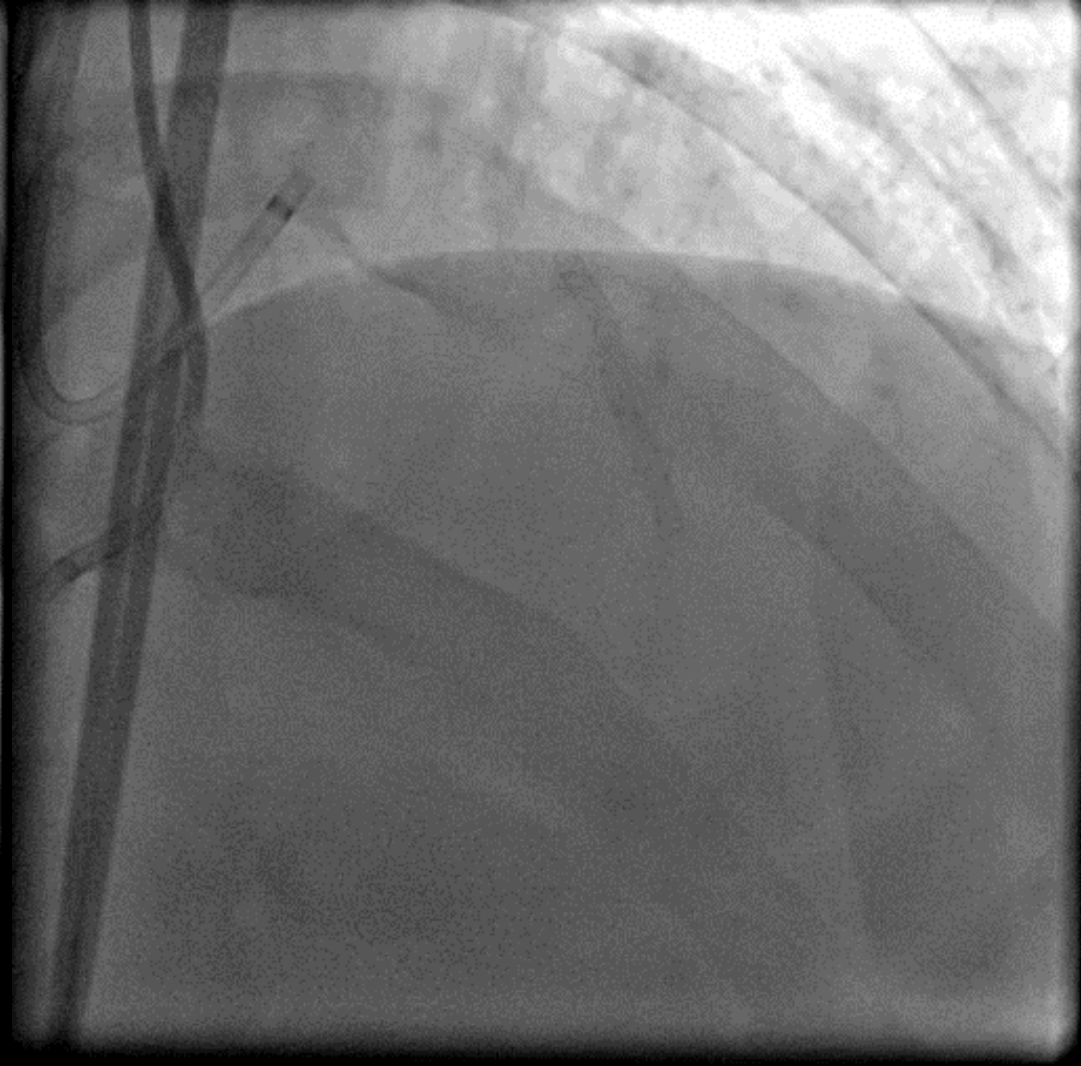
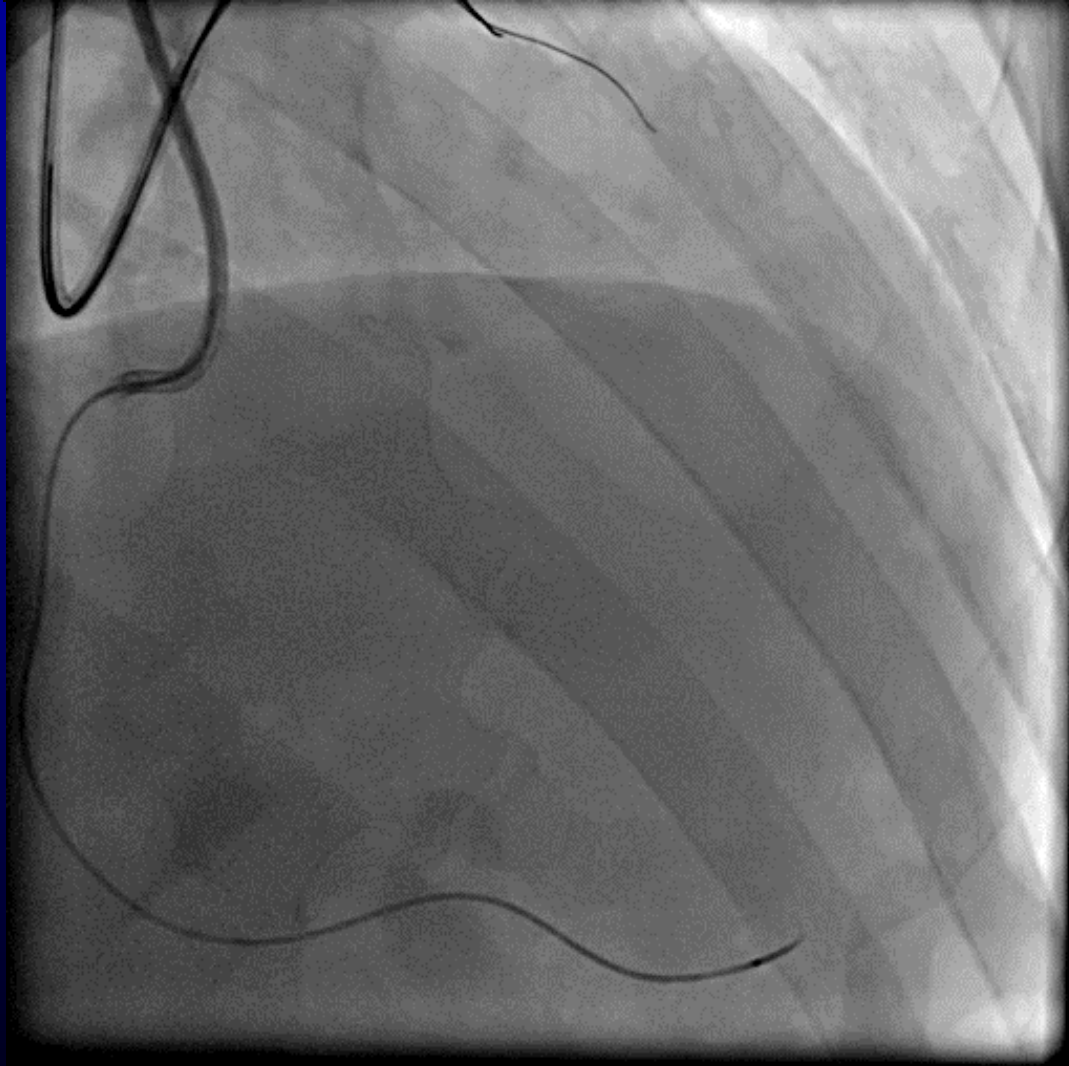
Corsair 150cm with SION

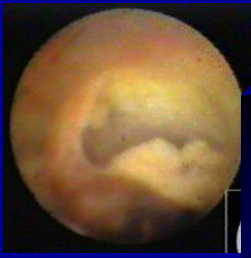



Epicardial channel

Corsair 150cm with SION





Epicardial channel

Sometimes we must use severe bending channel, but negotiating is very difficult.

Knuckle wire tip shape is sometimes useful, but must not perform easily.



Take Home Message

- You should choose SION firstly, depend on cases choose SUOH or Fielder XT-R.
- Appropriate angiogram and estimate channel size is important, sometimes rotation angiogram is very useful.
- Careful wiring and gradually advance microcatheter is important.
 - Checking wire position again and again is very important, especially epicardial channels.
 - Sometimes knuckle wire technique is safe.

Of course, success is important ,but safety is most important, we should choose most safety method.



Thank you for your attention!