

# What happened here ???

Lee Sang-Hyun MD.

Cardiovascular center

Pusan National University Yangsan Hospital

# 47-years-old female

- **Sx.**

- Effort related chest pain for 10 years
- New onset resting chest pain for 1 month

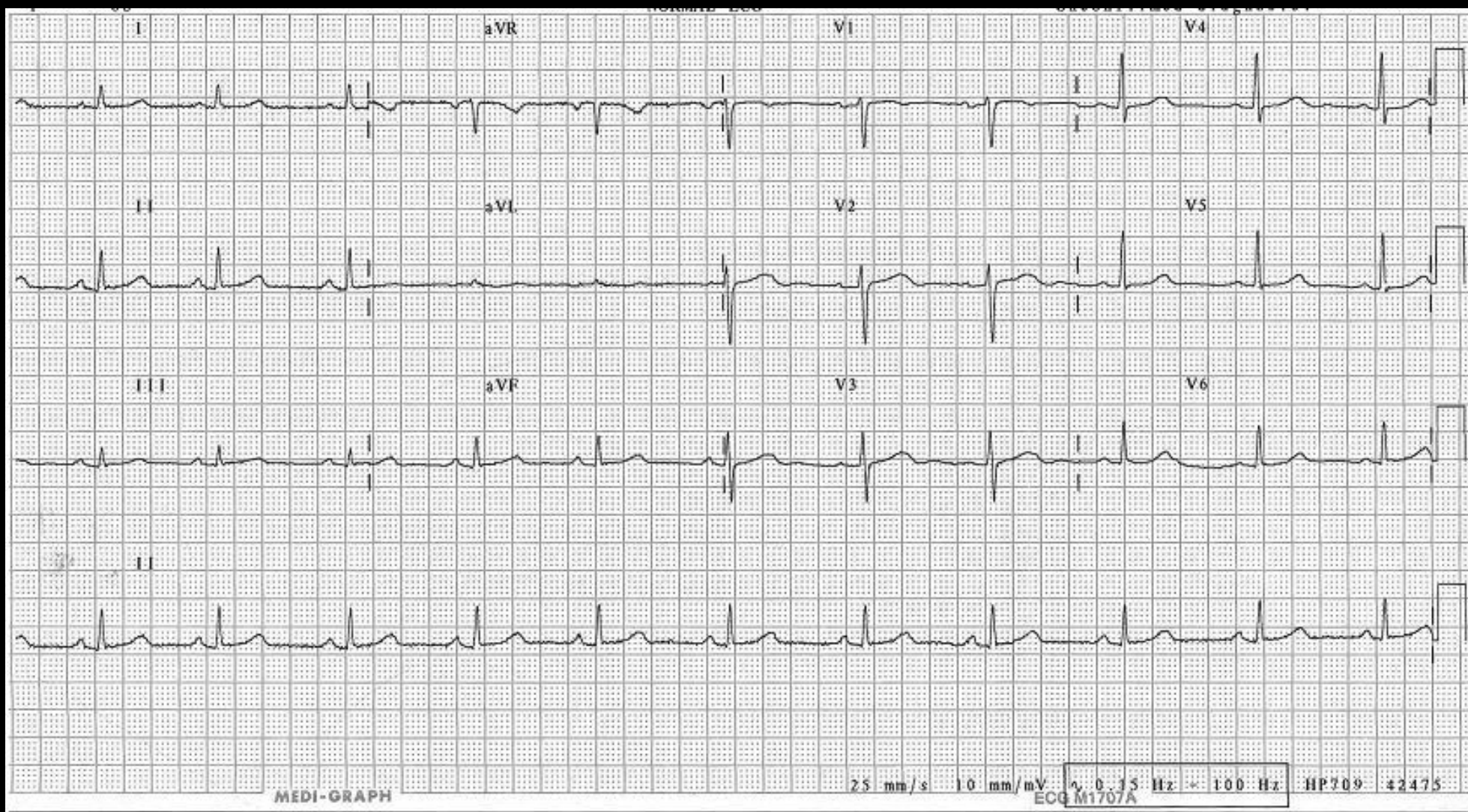
- P.Hx : none

- BMI : 21.5 (normal)

- Non-smoker

- **Total cholesterol / LDL / TG / HDL : 240 / 160 / 163 / 50**  
(mg/dL)

# Initial ECG

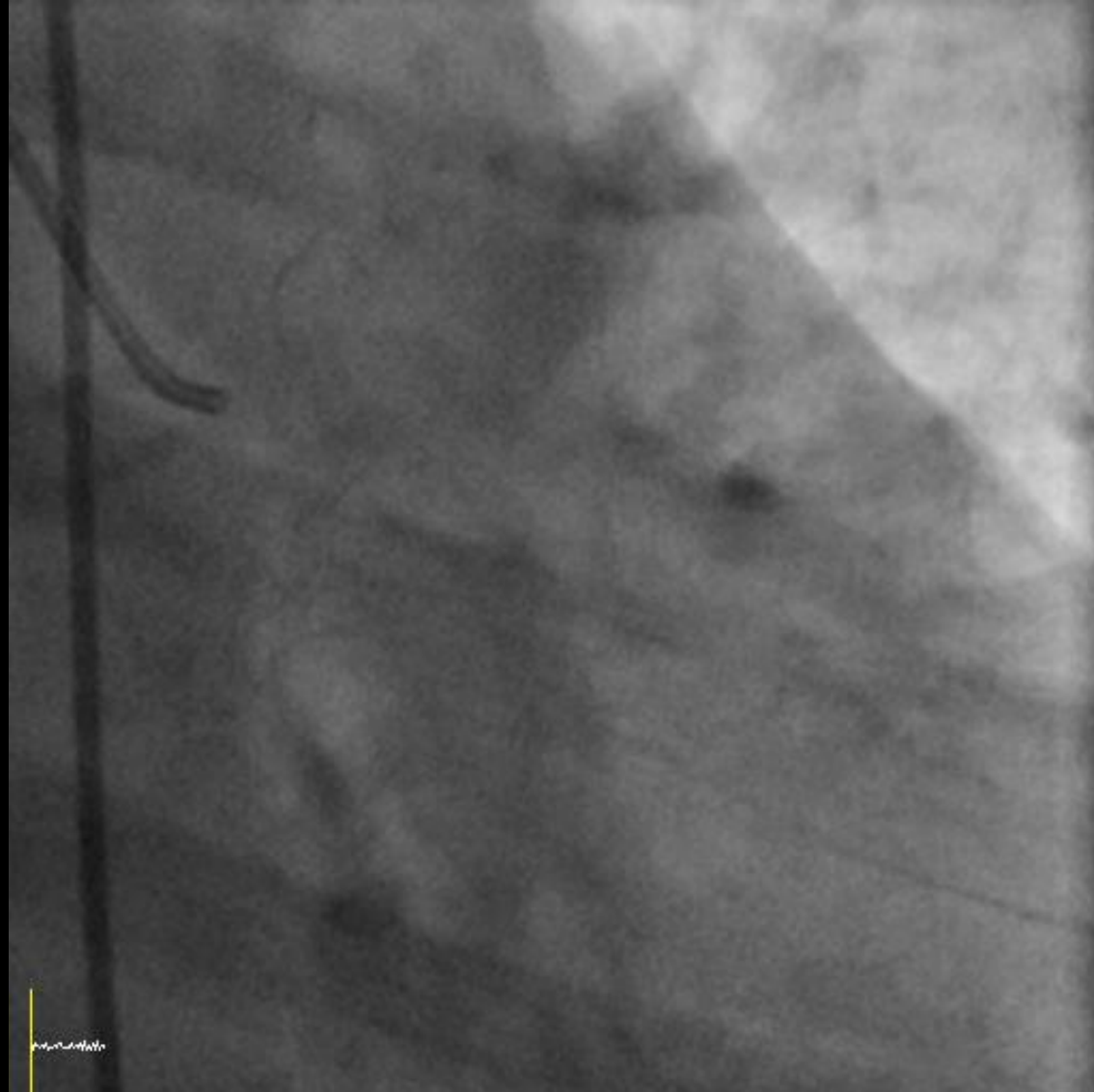

# Assessment

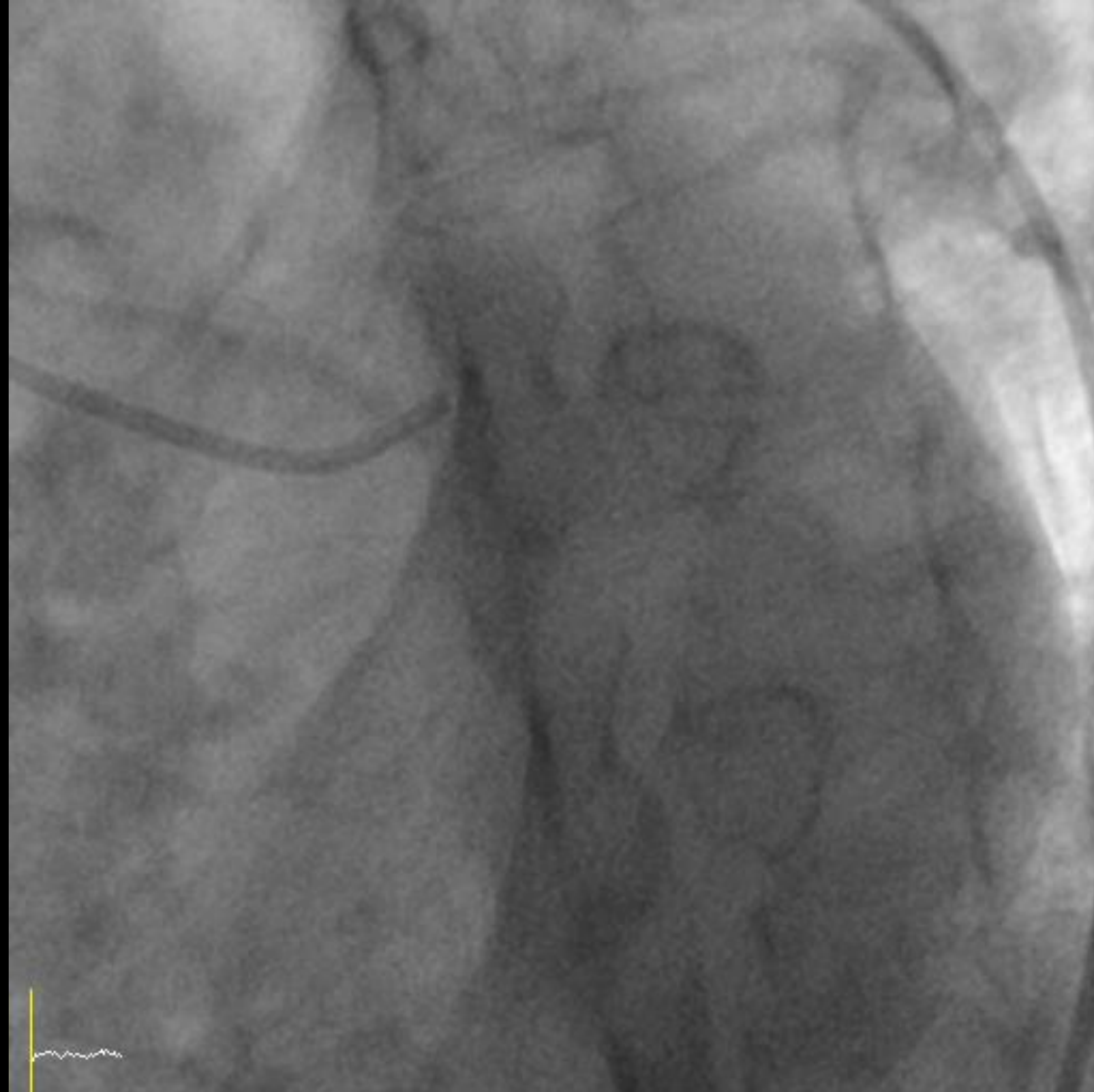- Unstable AP
- Dyslipidemia

→ Elective CAG

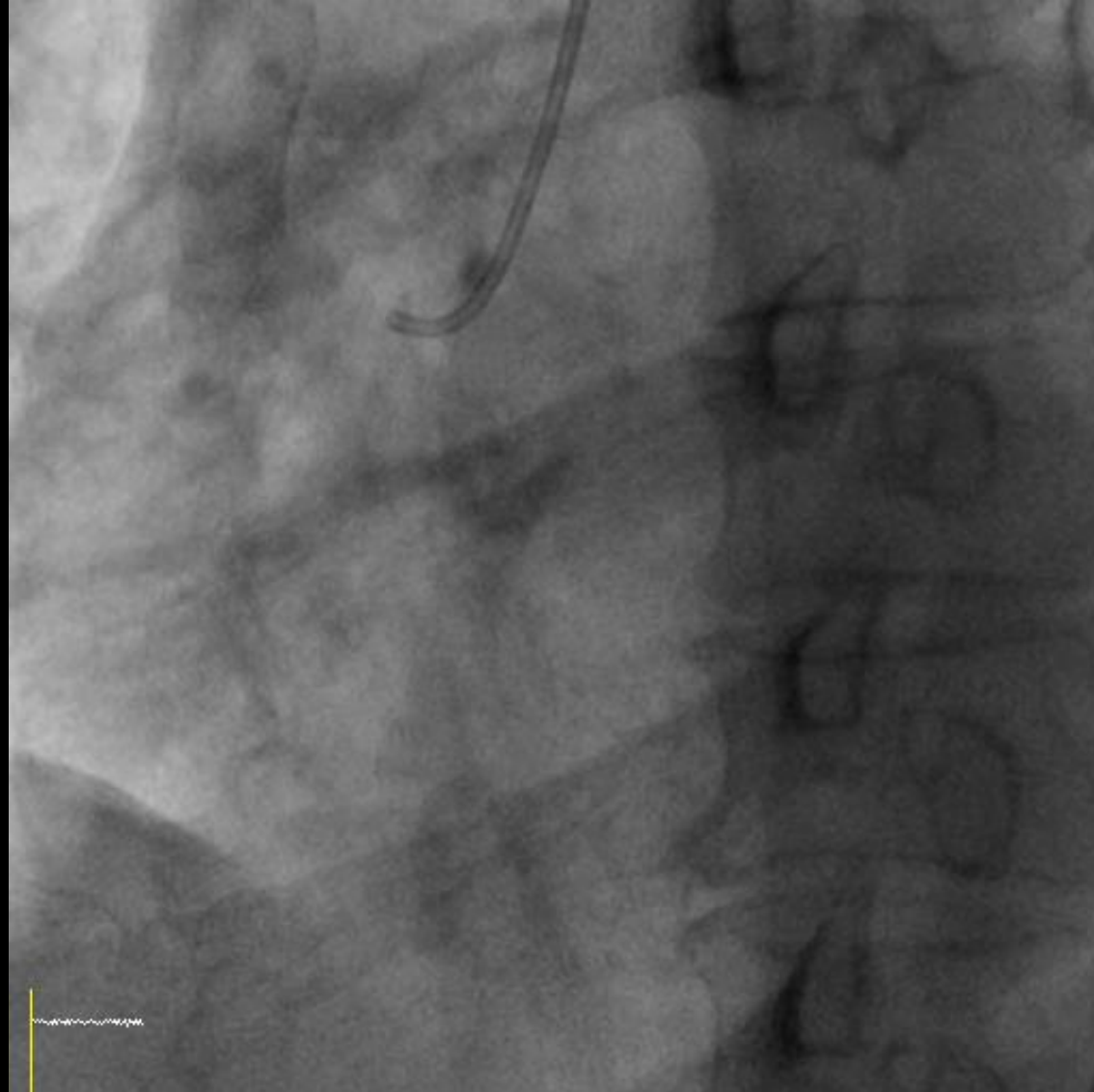
# Coronary Angiography



# Coronary Angiography



# Coronary Angiography



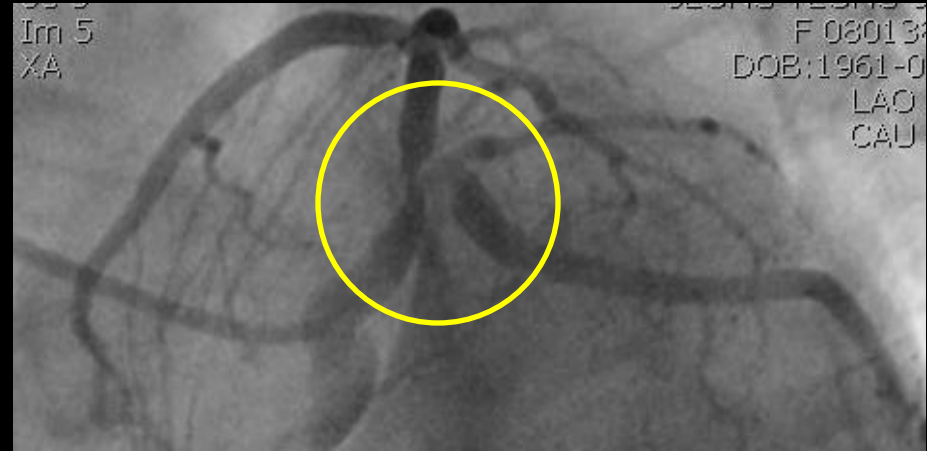# Next Plan ?

- **Left main bifurcation lesion**

**a. Medical Tx.**

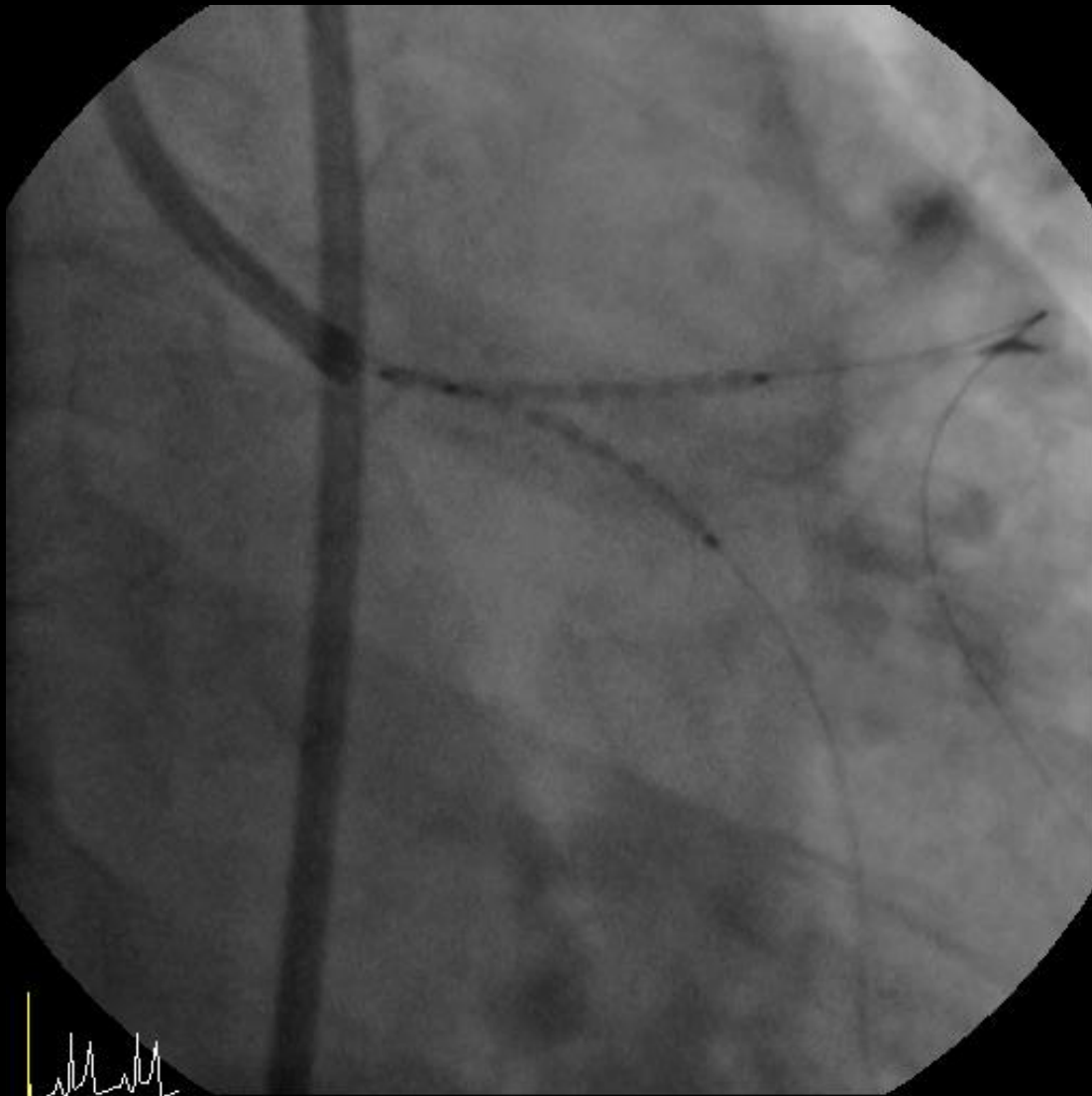**b. Percutaneous coronary intervention**

**c. Call cardiac surgeon**



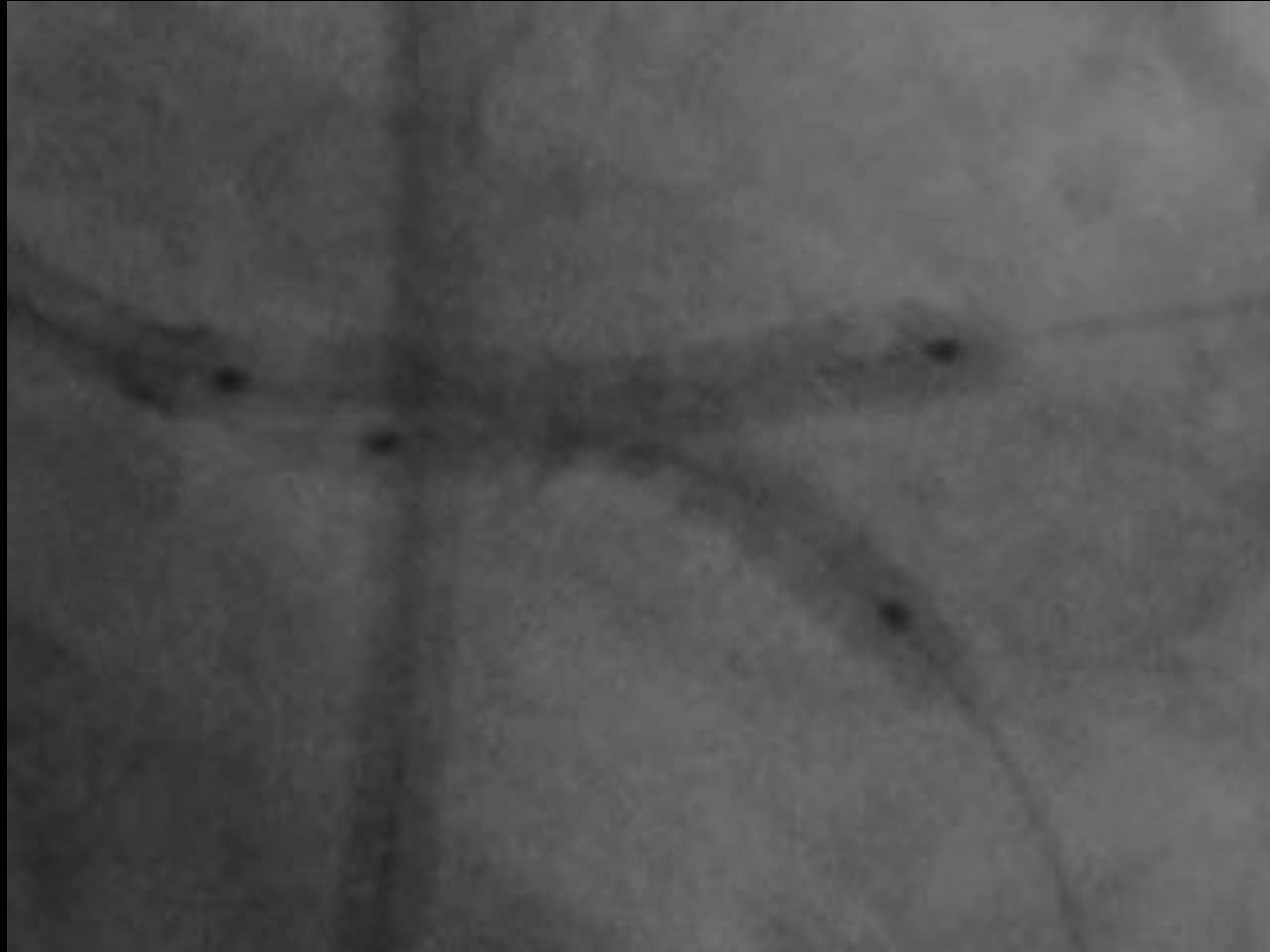


# PCI : two stenting with crushing tech

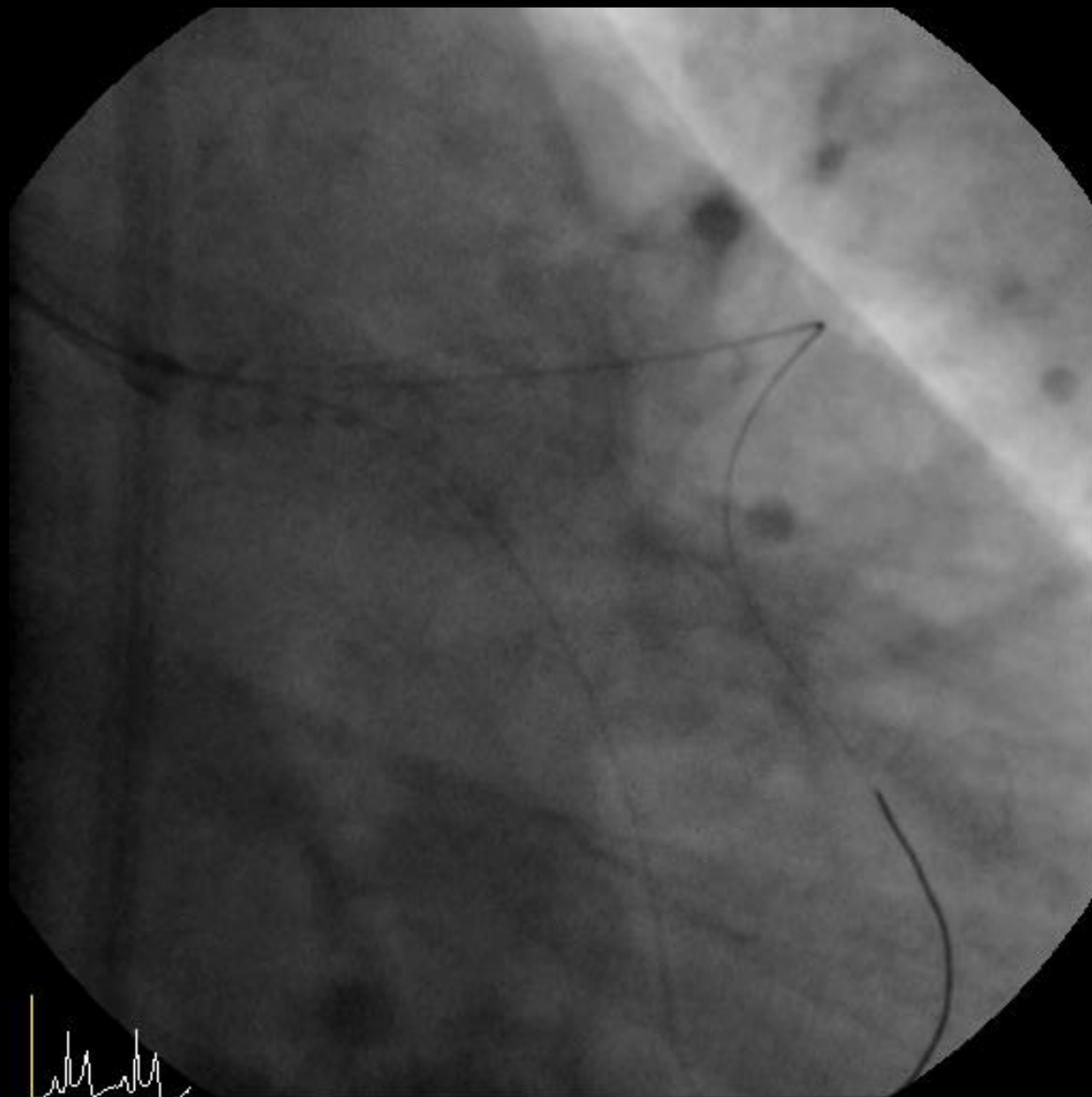


- Femoral (8Fr)
- G/C : EBU 3.0  
(side hole)
- Wire
  - BMW<sup>®</sup> (LAD)
  - Runthrough<sup>®</sup> (LCx)
- Stent
  - Cypher<sup>®</sup>  
3.5\*23mm (LAD)
  - Cypher<sup>®</sup>  
2.75\*18mm (LCx)

# PCI : Final Kissing balloon



# PCI : Final CAG



*Handwritten signature*



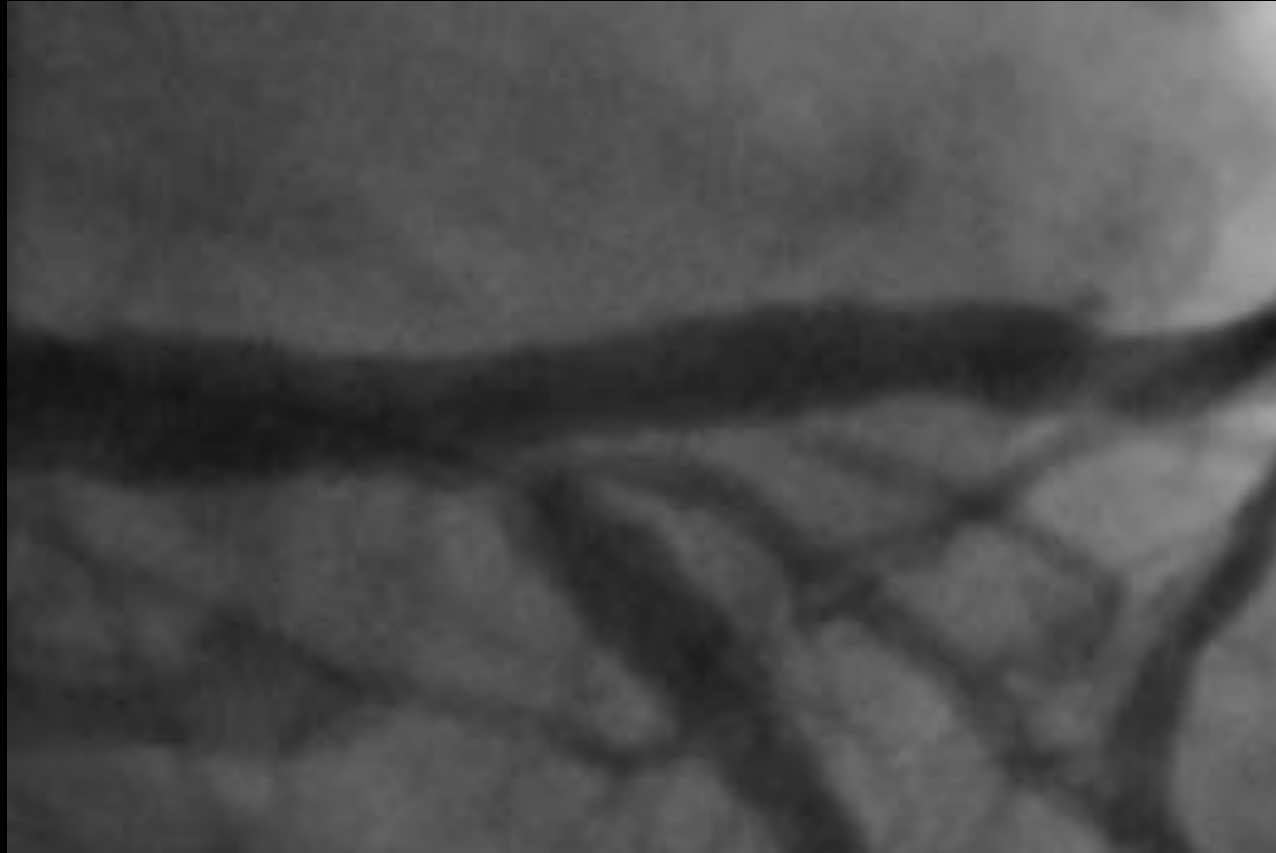
DID I DO  
SOMETHING  
WRONG?

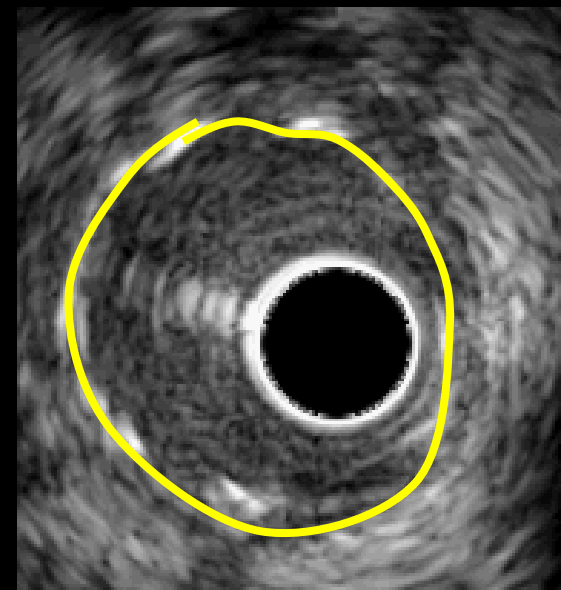
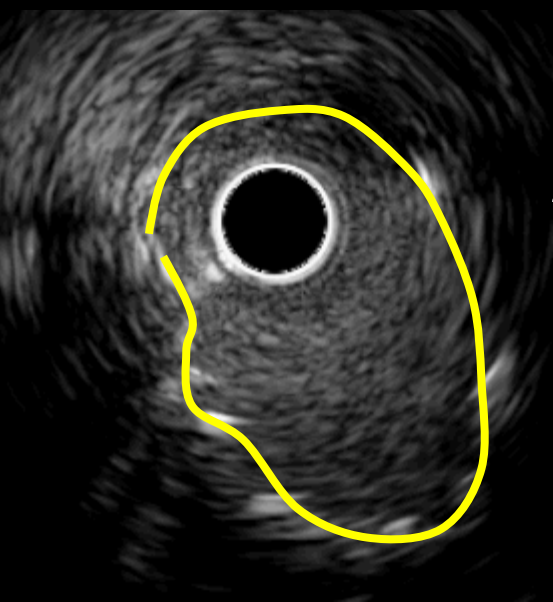
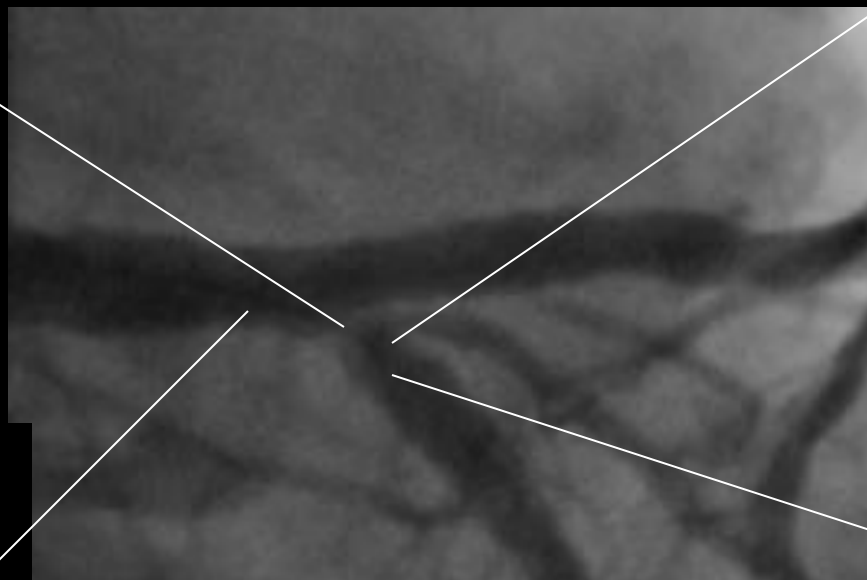
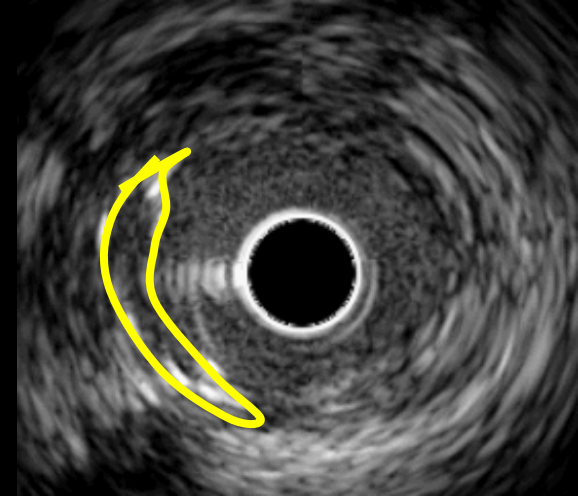
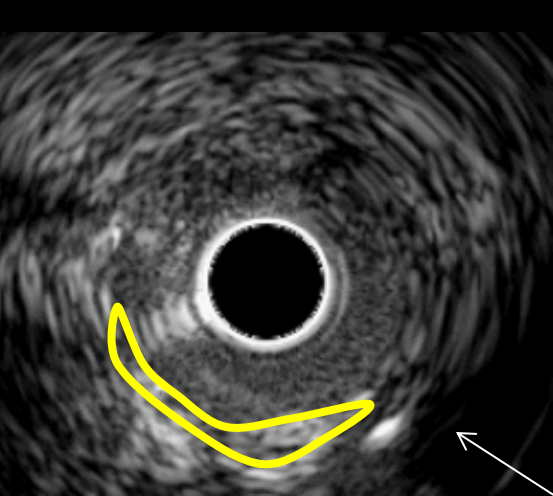
We were.....



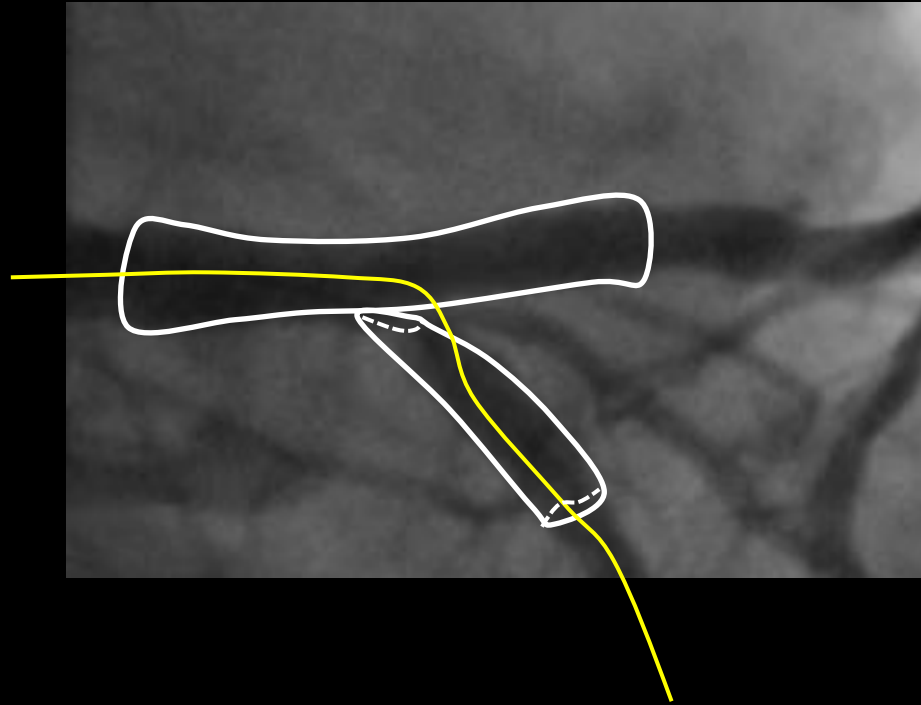
Panic !!

**What happened here???**



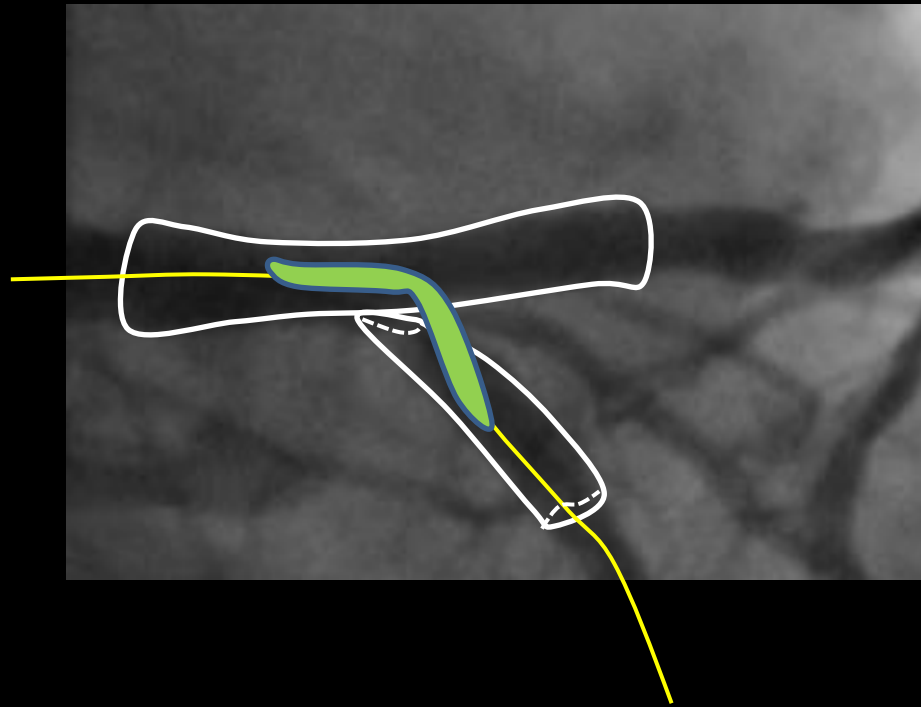


**What happened here???**

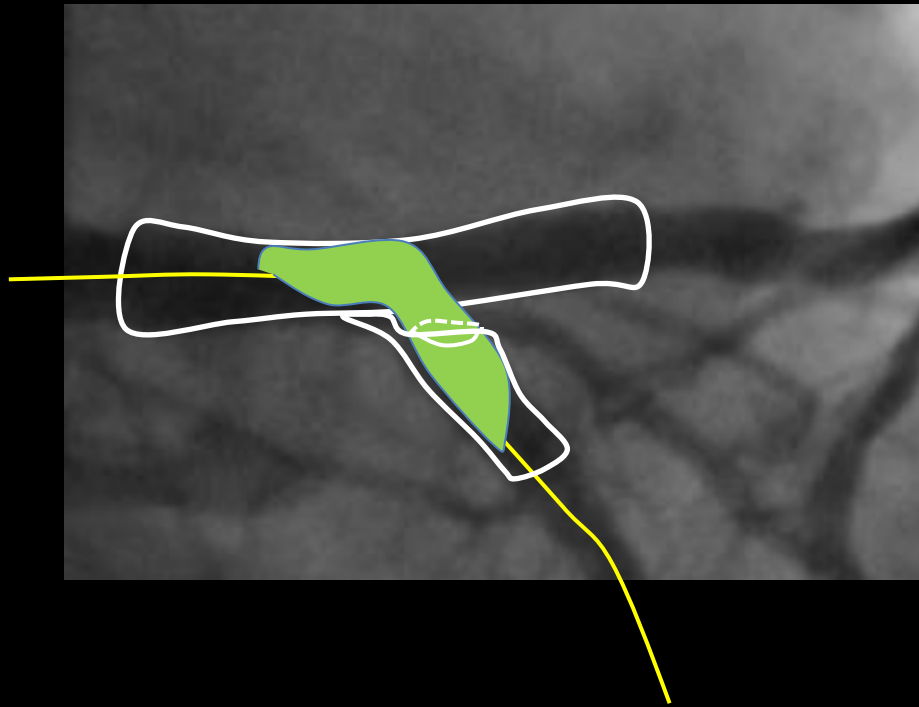




What happened here???




What happened here???



# What would do in this case?

Put an another stent ??

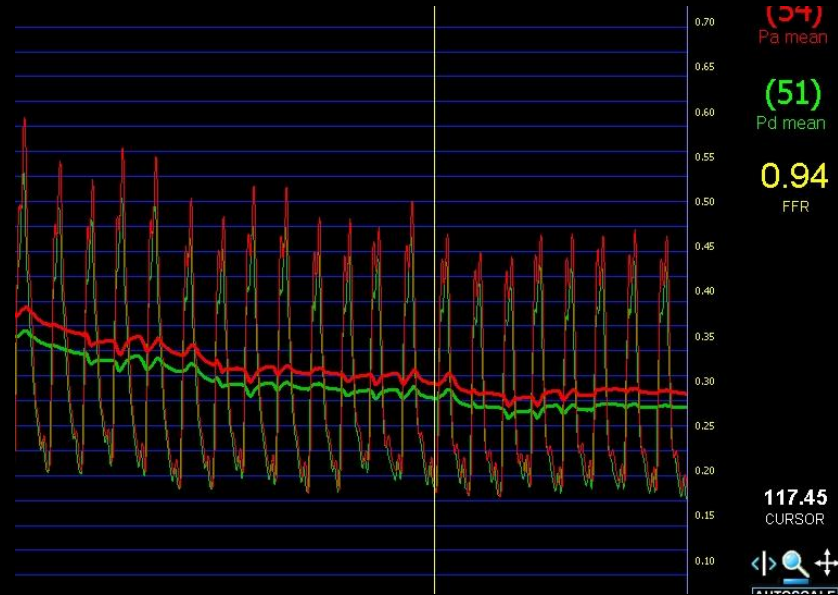
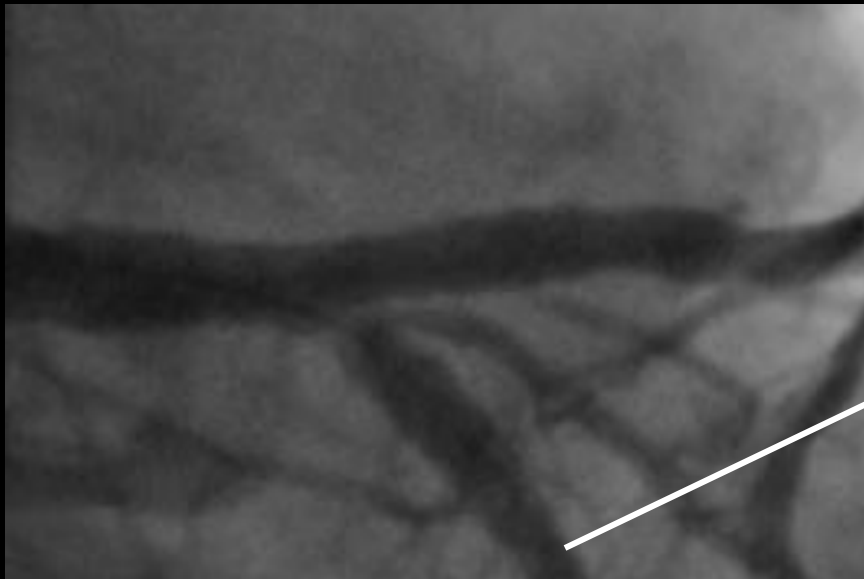


Send her to OP room ??

I did FFR !!

# FFR

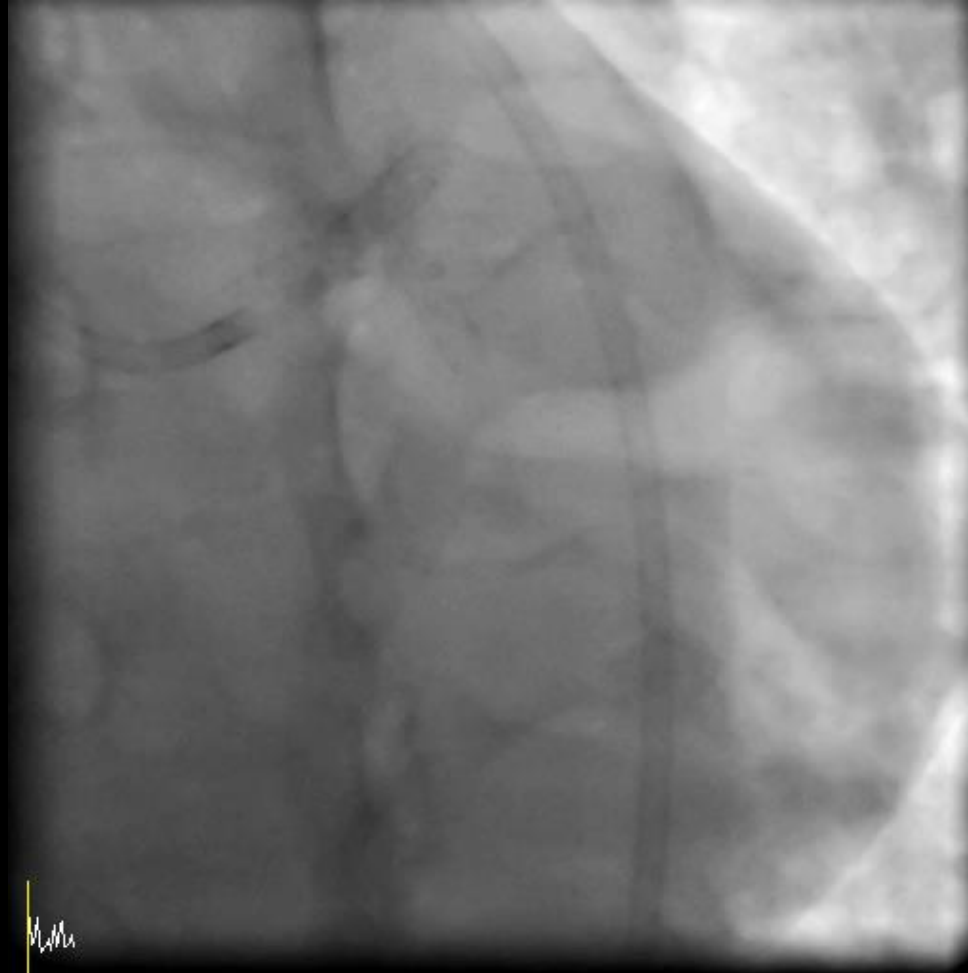
# Simply leave it alone!!!



# 0.94

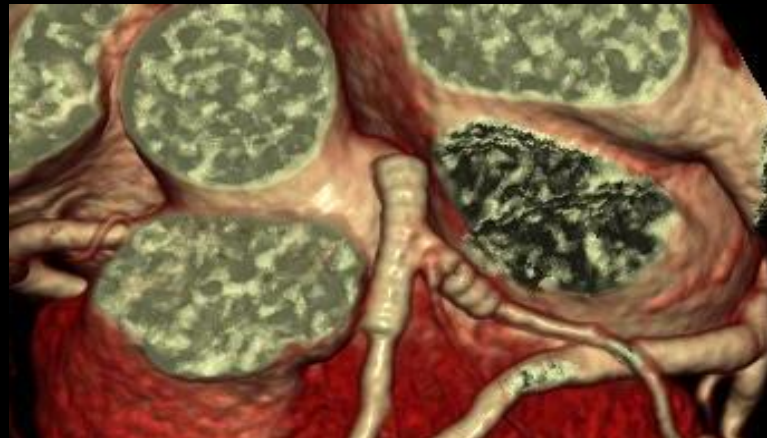
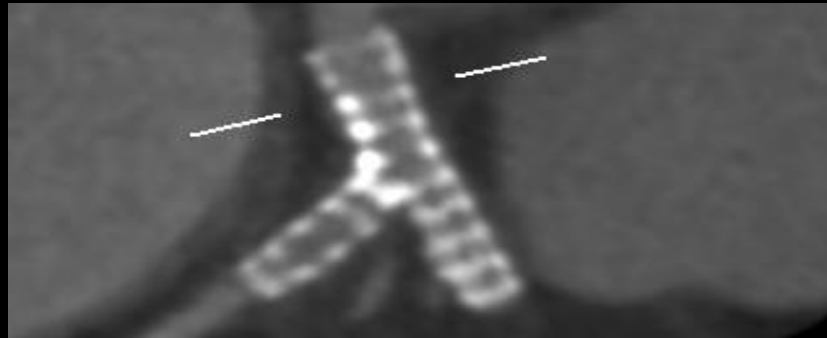
# No event up-to 5 yr F/U

1 yr F/U CAG, same FFR value (0.94)



# No event up-to 5 yr F/U

3 yr FU of CT with adenosine stress  
perfusion



Adenosine stress perfusion : negative

# Summary

- In complex cases with a special situation in which you don't know what to do, FFR may give you a valuable information for guiding the procedure

**Thank you for your  
attention**