



Video Live : Technique of Abdominal Aortic Aneurysm

**Han Cheol Lee MD. PhD.
Department of Cardiology
Pusan National University Hospital**

CASE : AAA



윤O M/75

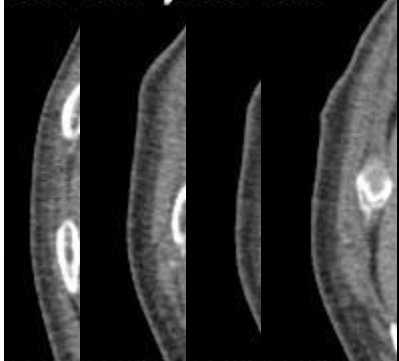
- Chief Complaint : Known AAA
- We plan to operate on Klastkin tumor
- Patient has AAA(6cm)
- Past History : HT(+), DM(+)
Hyperlipidemia(+), CVA(-)
- Social History : Smoking (+)

CT



Idx 1
SMS Definition AS+
Se 801
Im 1
S:CT
Ir0.0thk
C:0.0
FI
2.0t|2.0thk|2.0t|2.0thk|2.
APPIAPPLIAPPIAPPLIEA
0.0 0.0 0.0 0.0 0.

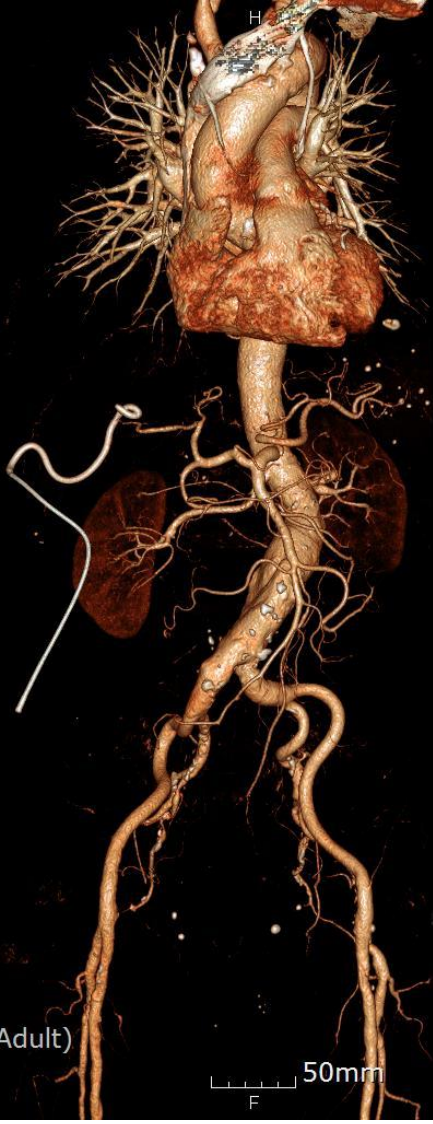Idx 17
SMS SMS DSMS SMS DefS
Se 5Se 5 Se 5Se 5 S
Im 1Im 17Im 1Im 178 Ir
CT CT CT CT C
FFS FFS FFS FFS FI
2.0t|2.0thk|2.0t|2.0thk|2.
APPIAPPLIAPPIAPPLIEA
0.0 0.0 0.0 0.0 0.



FOV FOV 3 FOV FOV 310FI
TP 3TP 40TP 4TP 415TI
TI 5TI 500TI 5TI 500 T
kVp kVp 1kVp kVp 120k
mAsmAs 1mAsmAs 11m
GT GT 0 GT GT 0 GkVp 0.0
Thor ThoraThor Thorax^TlmAs 0
Aort Aorta Aort Aorta alA
201(2010-201(2010-112

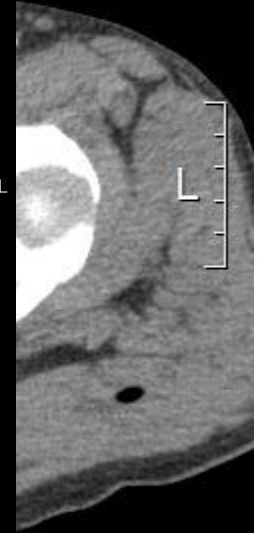Idx 178
SMS SMS DSMS SMS DefS
Se 801
Im 178
S:CT
Ir0.0thk
C:0.0
FI
2.0t|2.0thk|2.0t|2.0thk|2.
APPIAPPLIAPPIAPPLIEA
0.0 0.0 0.0 0.0 0.

Thorax^08_Aorta_all (Adult)
VRT Collection
2010-11-19/12:05:26



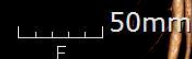
PNUH
RES/CROB/SHADE/SURF
2010-11-19
ANONYMIZED
M 068Y ANONYMIZED
DOB:UNKNOWN

PNUH
2010-11-19
ANONYMIZED
ANONYMIZED
DOB:UNKNOWN



W 400
L 40
Z 100%
mpression 3:1

W 255
L 127
B 100
O 100
C 220
Z 100%
Compression 7:1



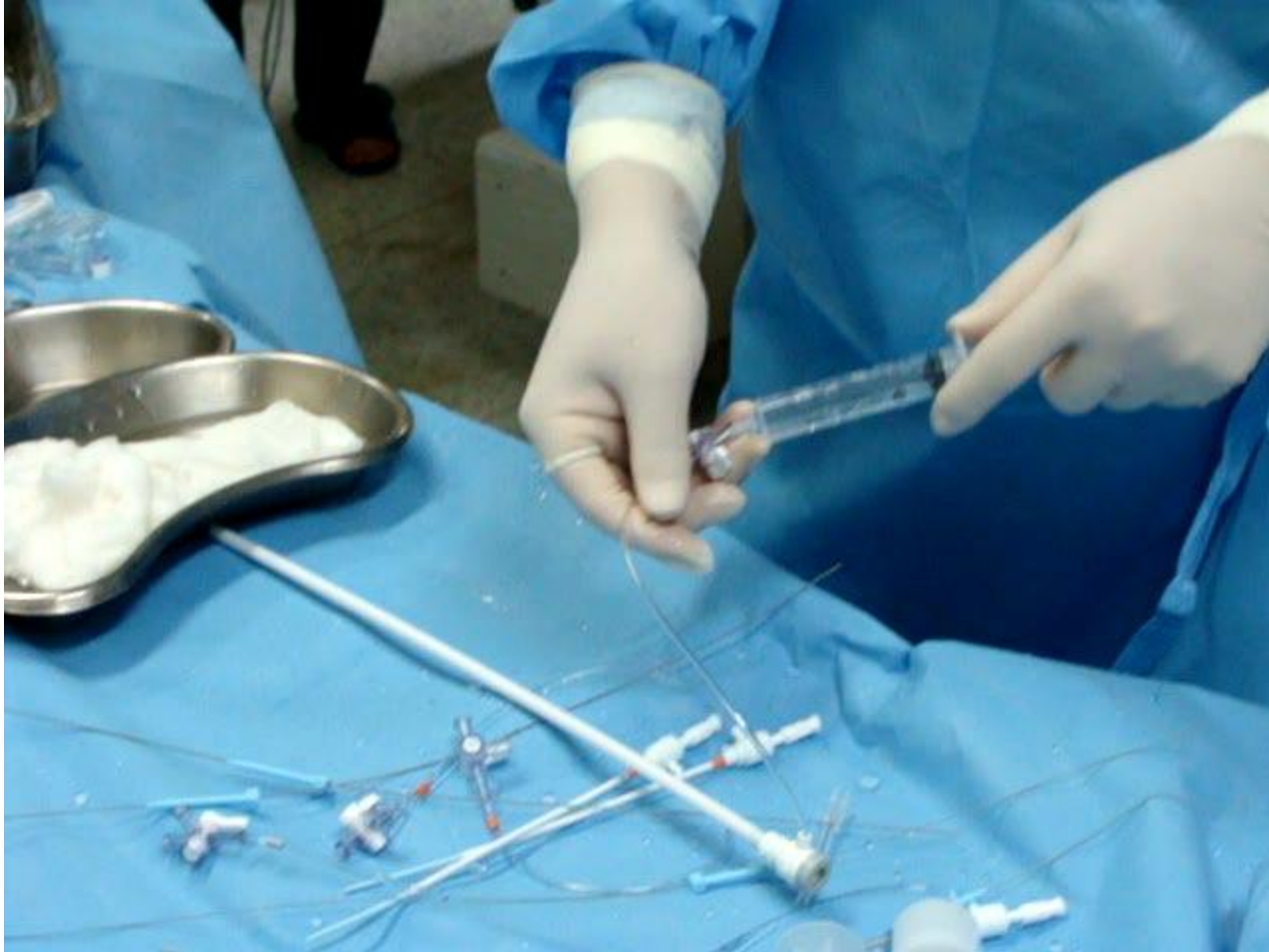Assessment

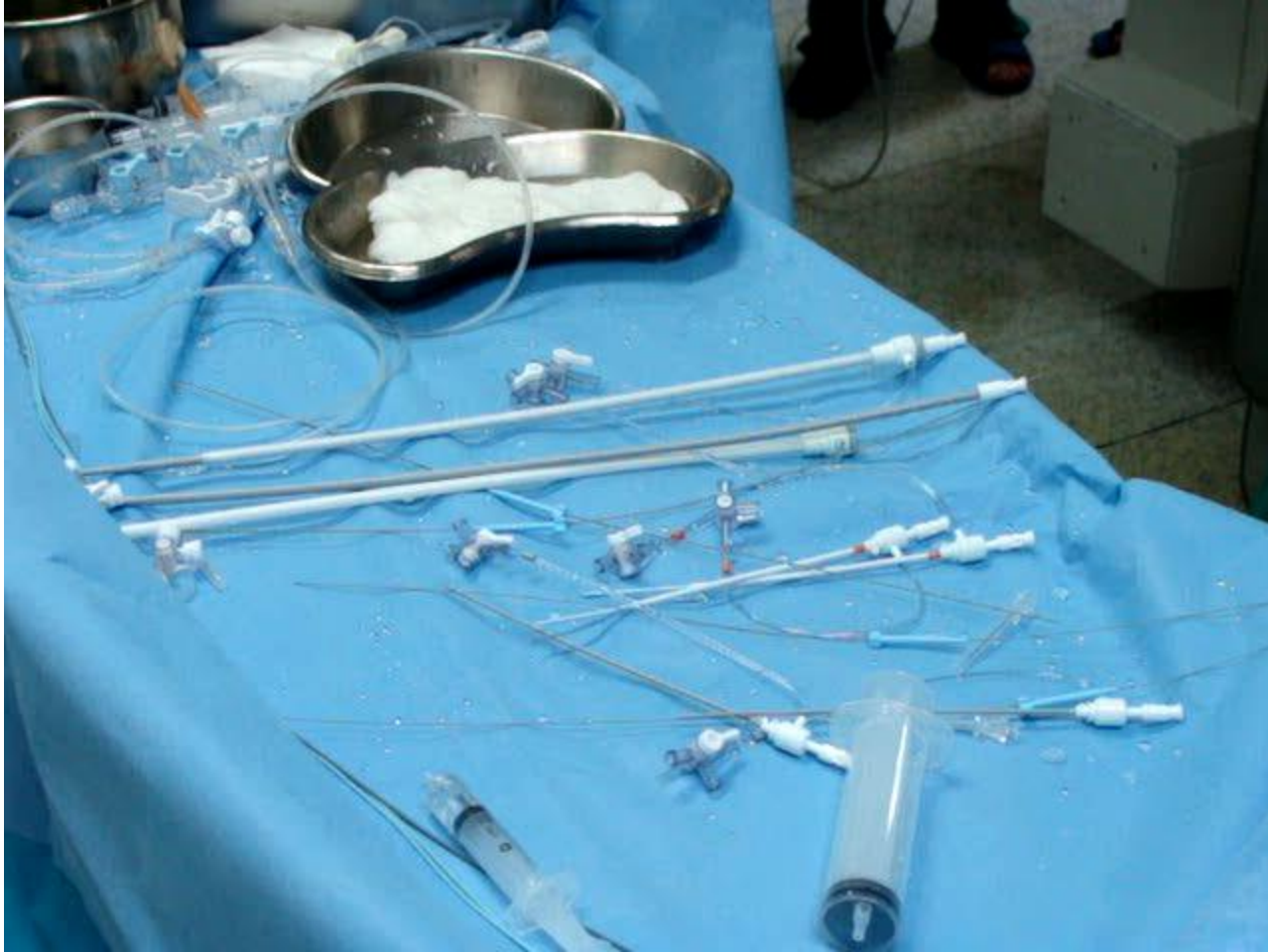

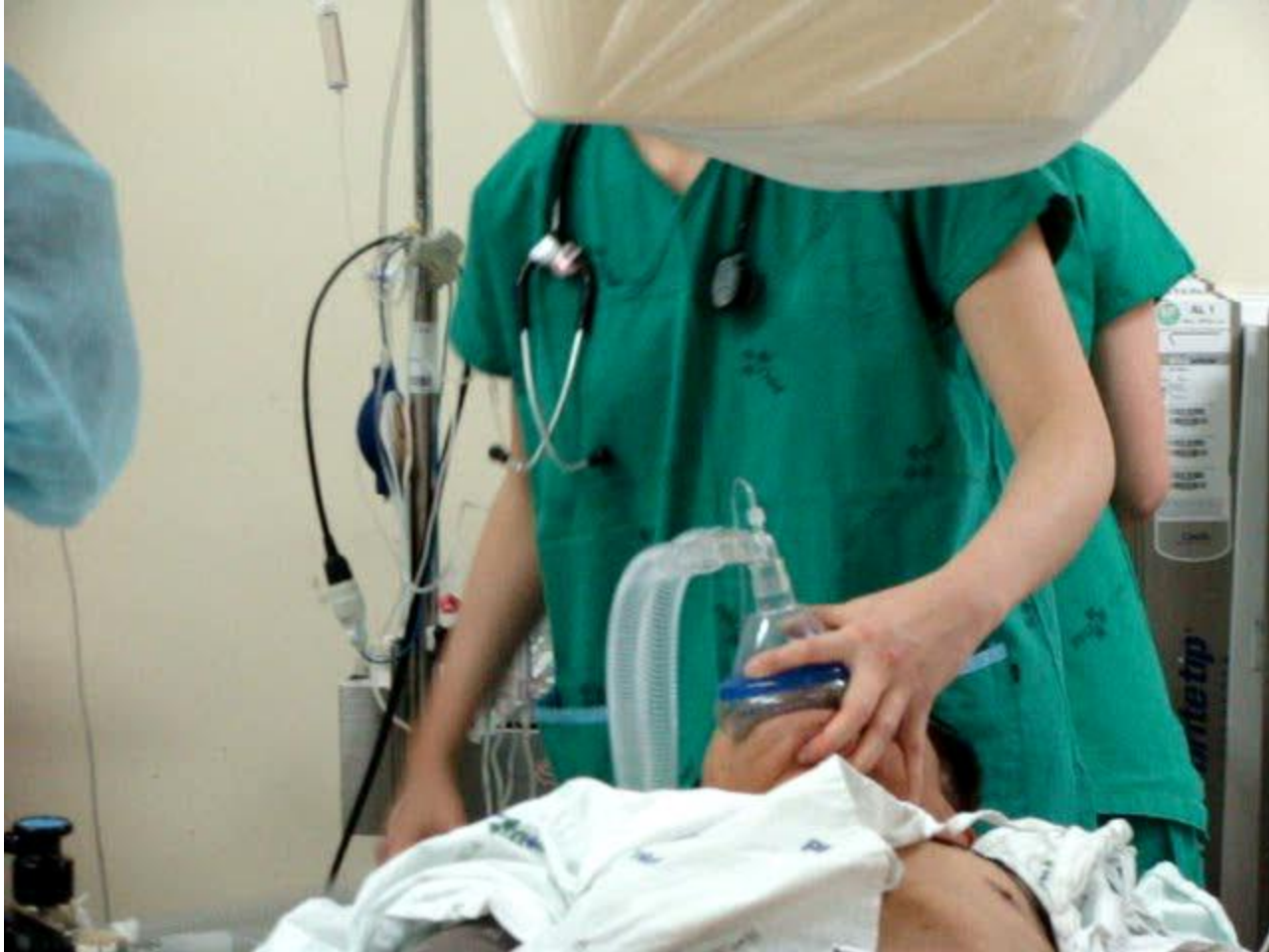1. AAA
2. Klastkin tumor

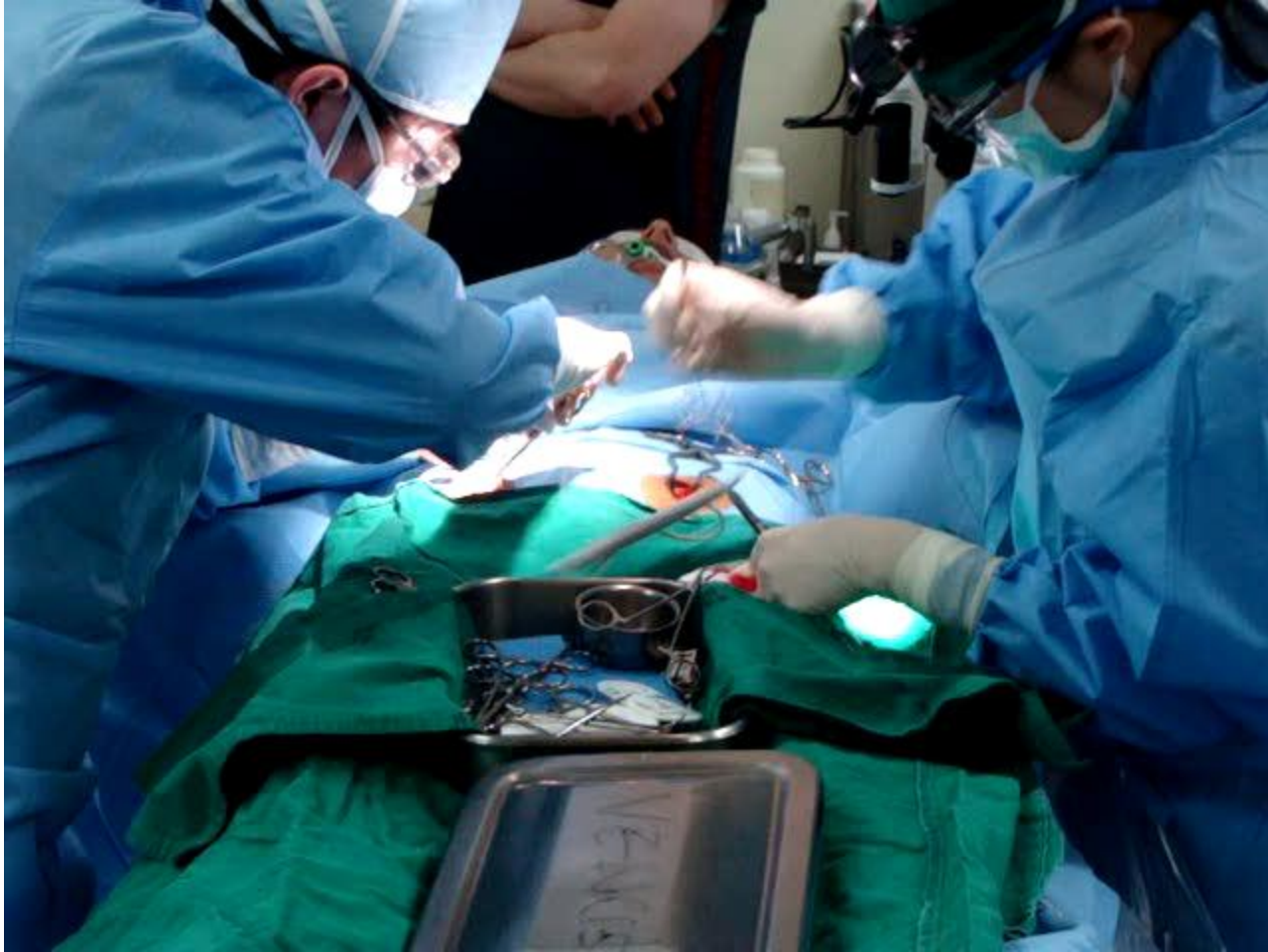Plan

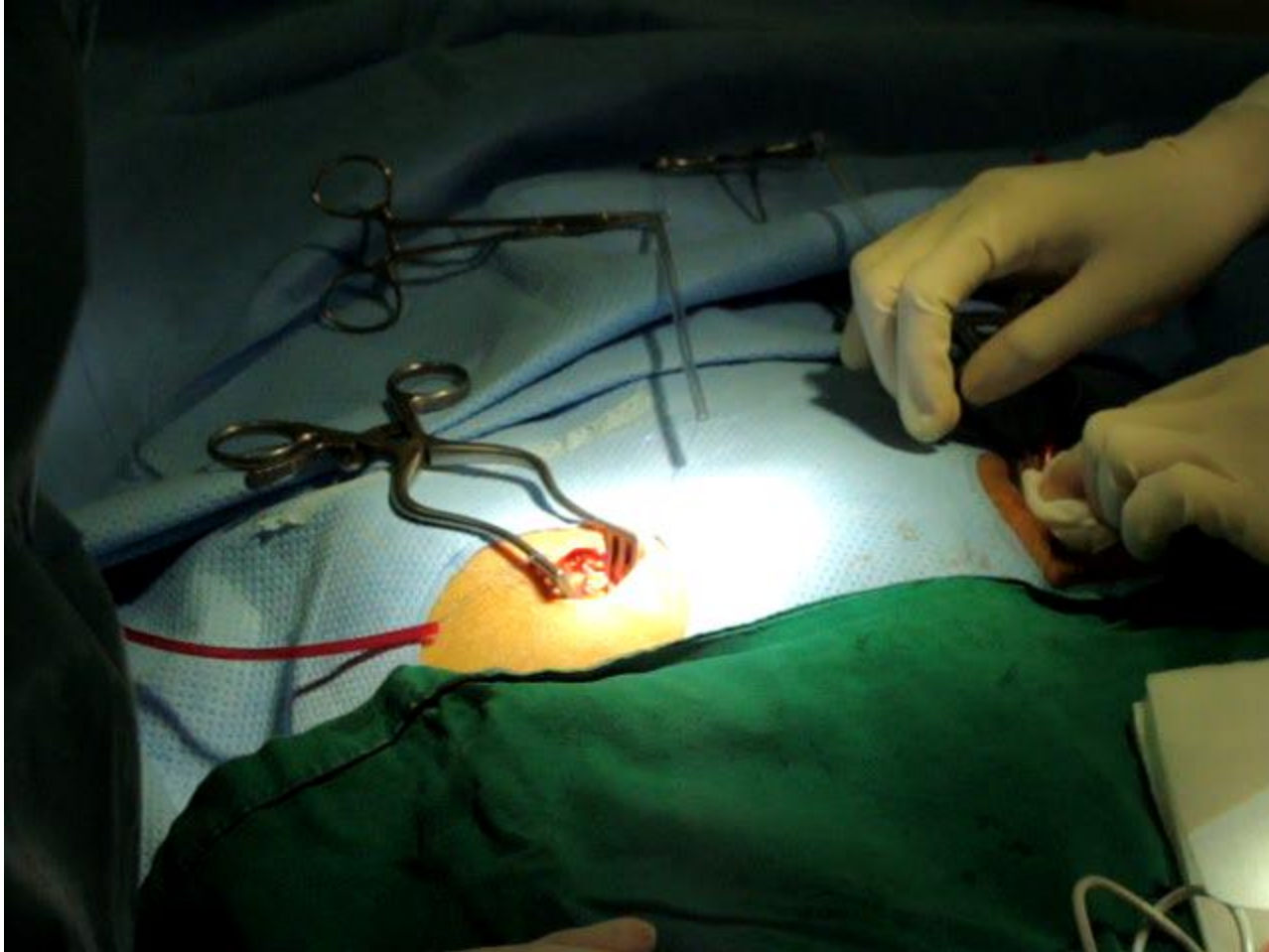1. EVAR for AAA
2. Left lobectomy of Liver after EVAR

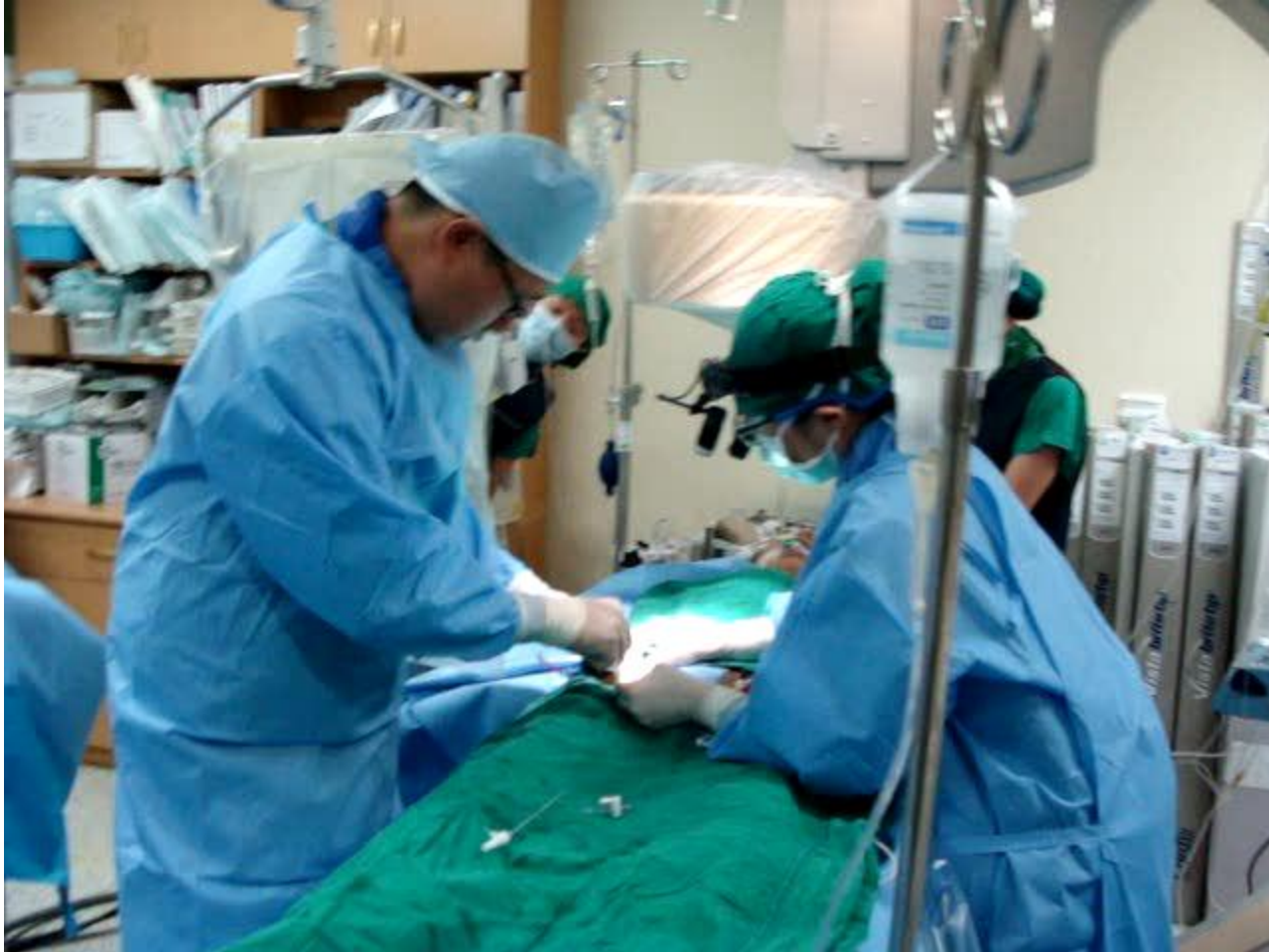


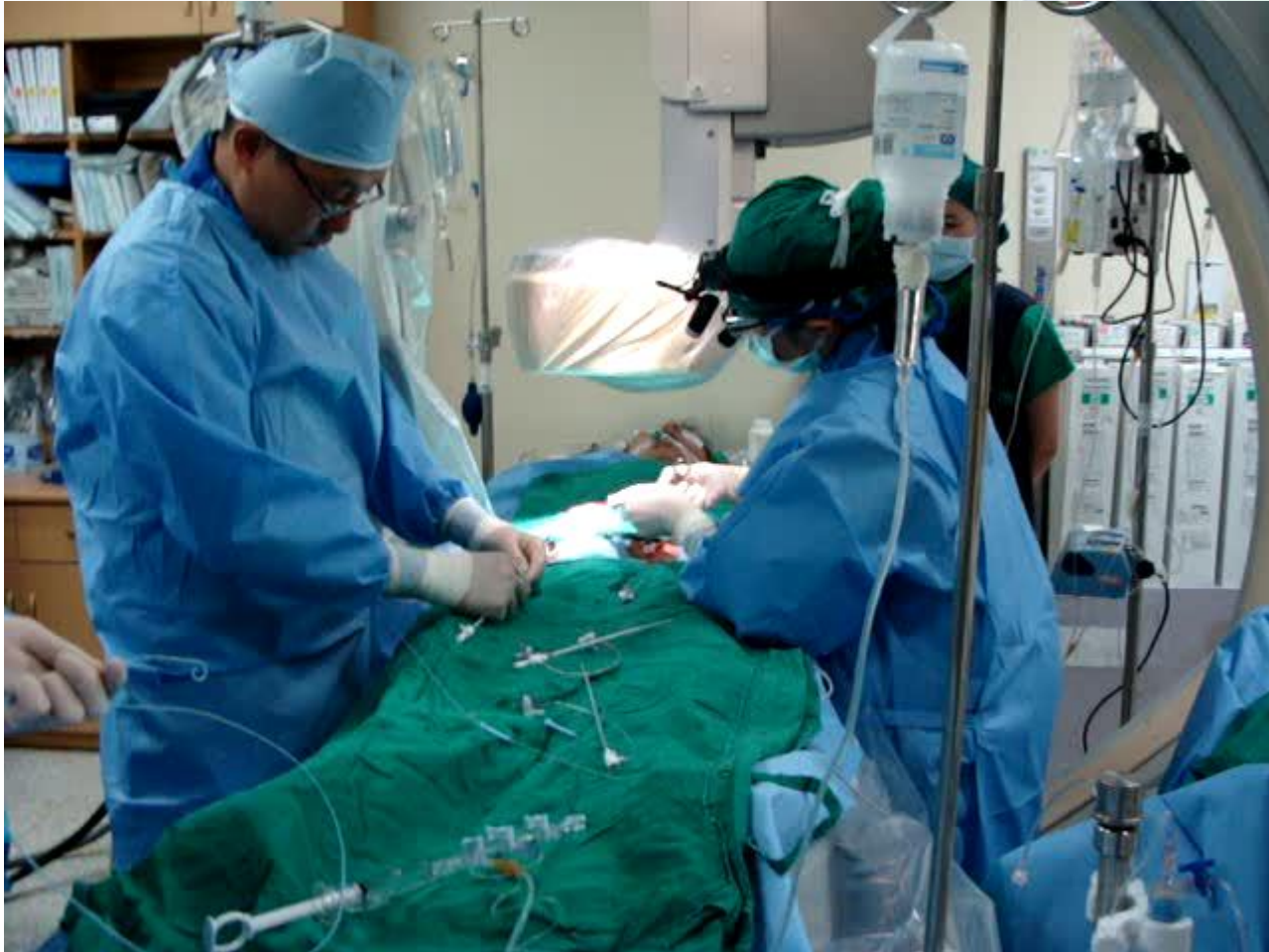


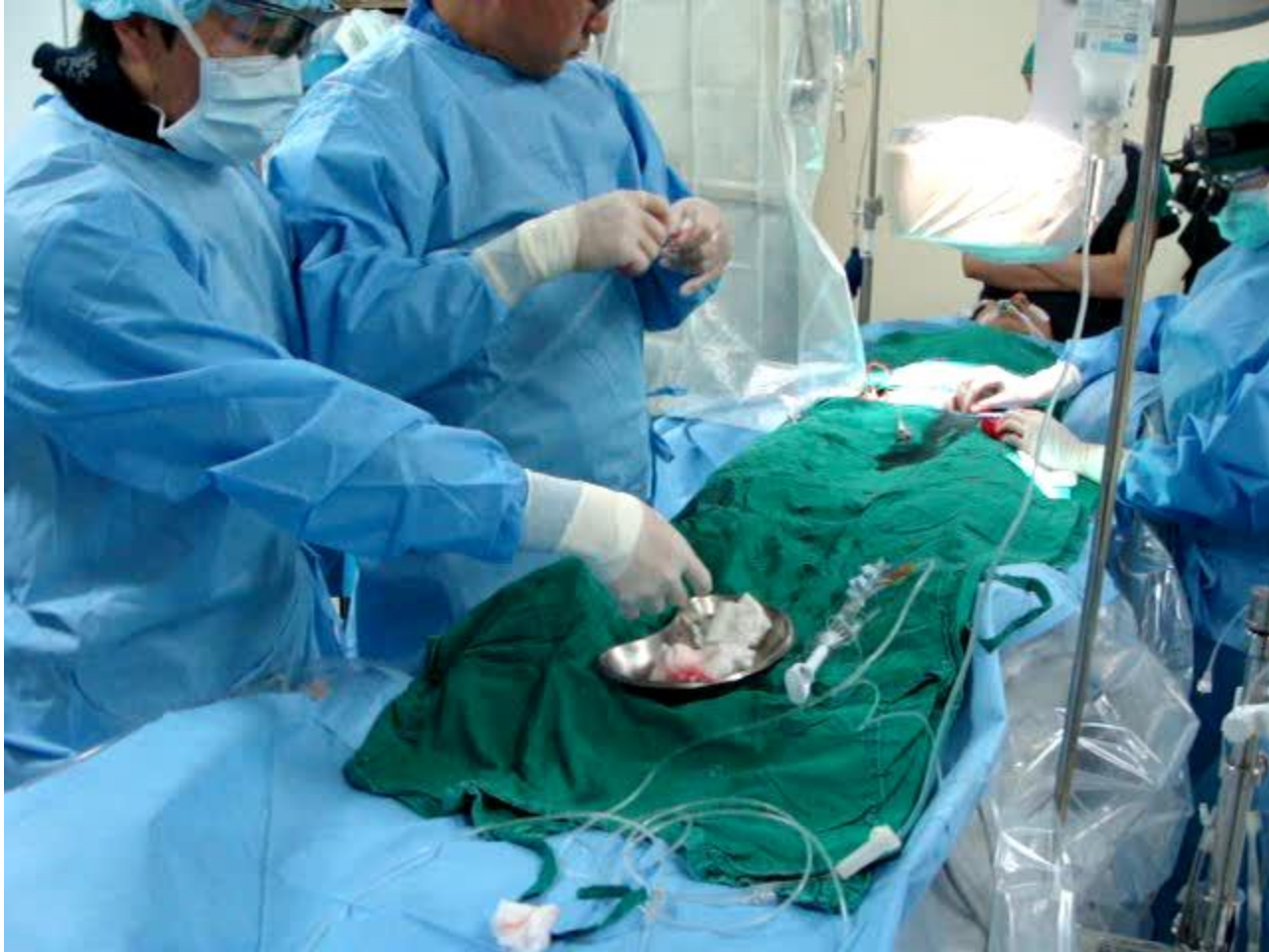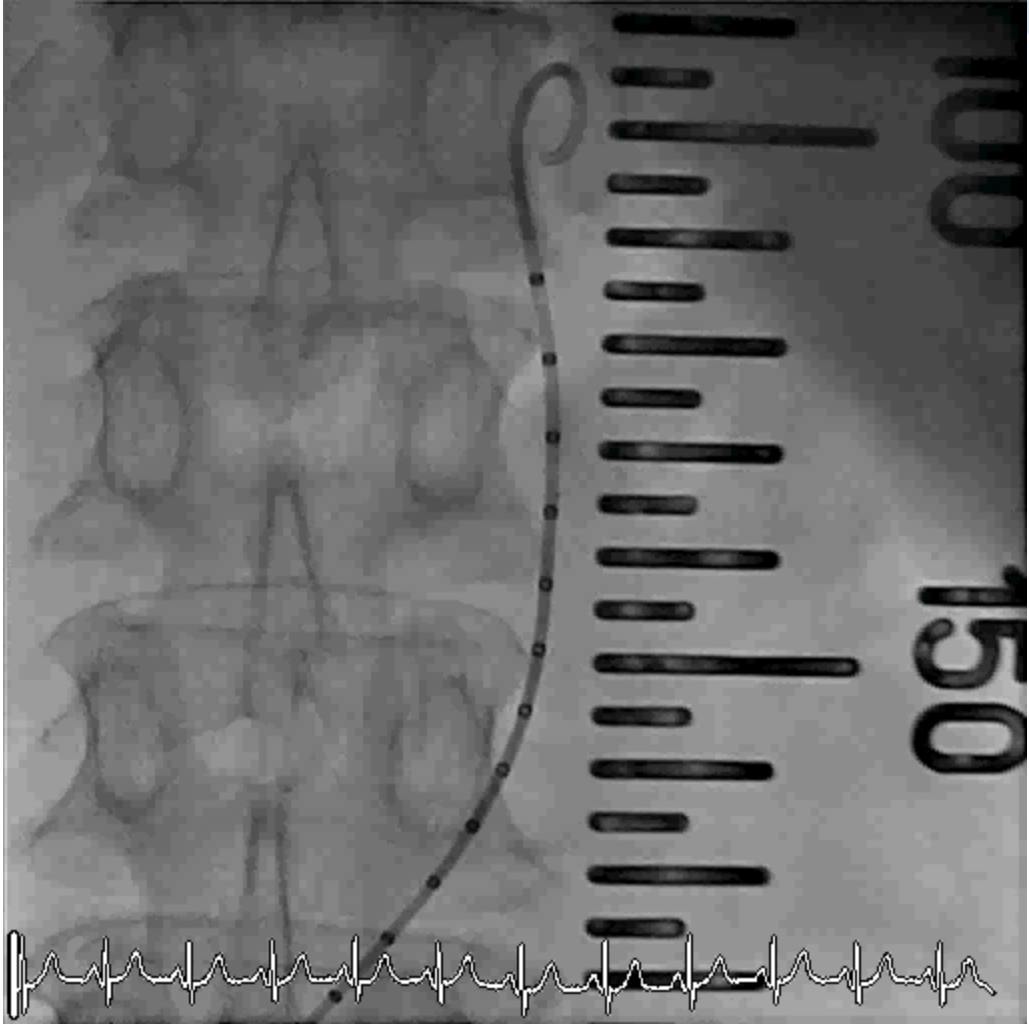


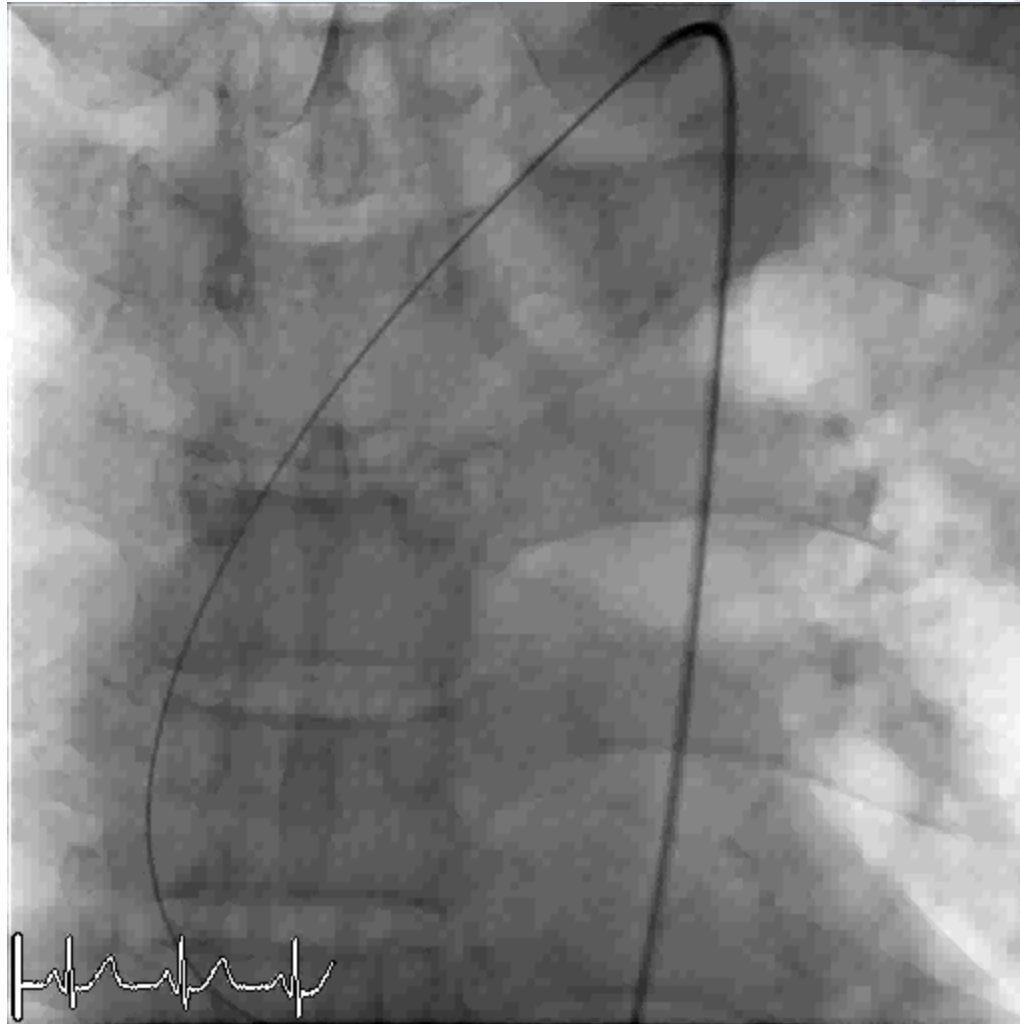


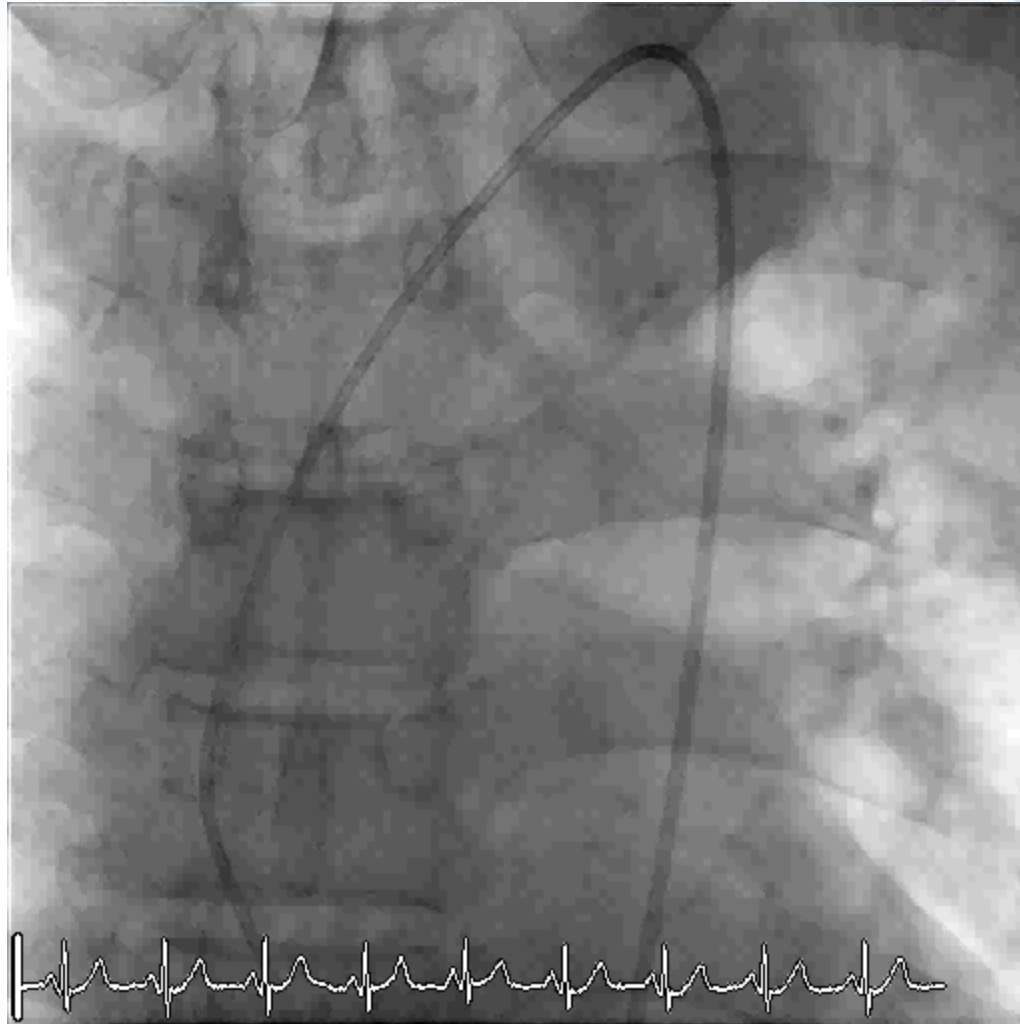


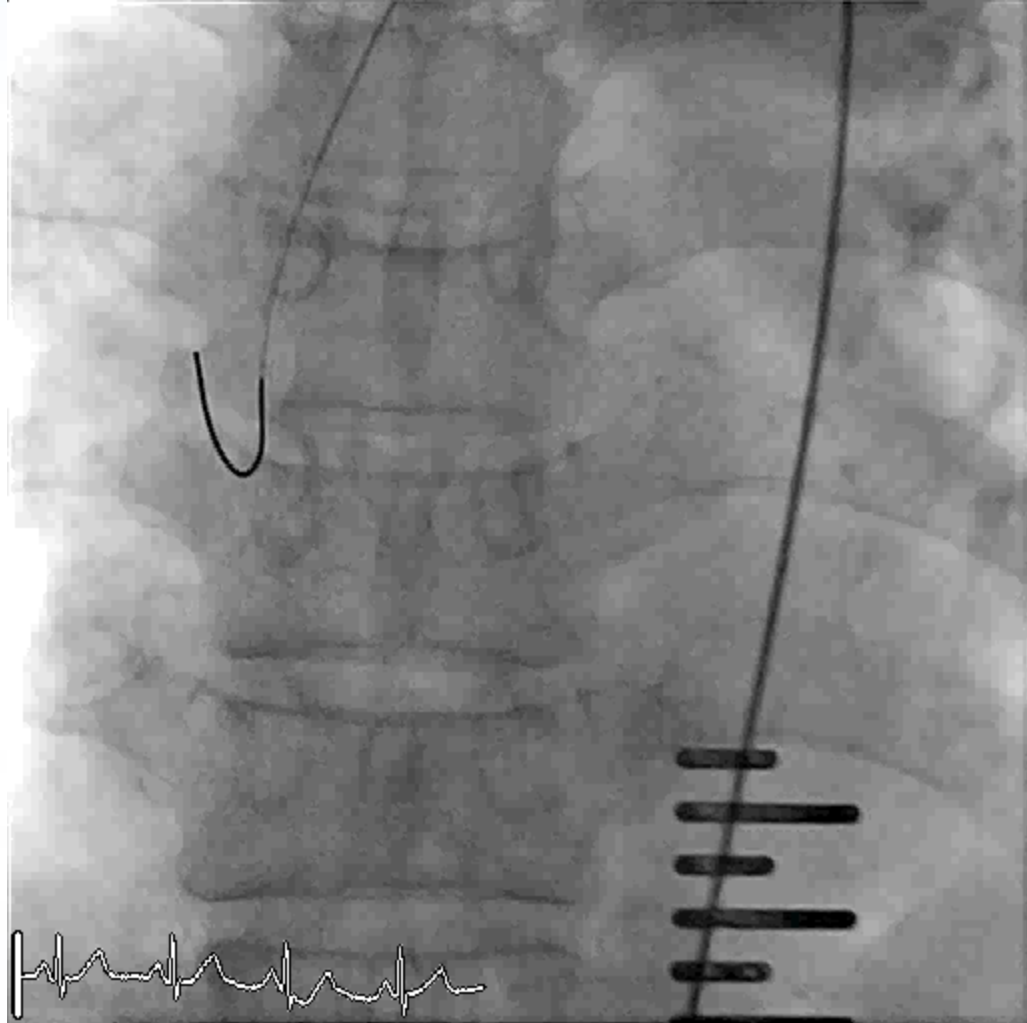




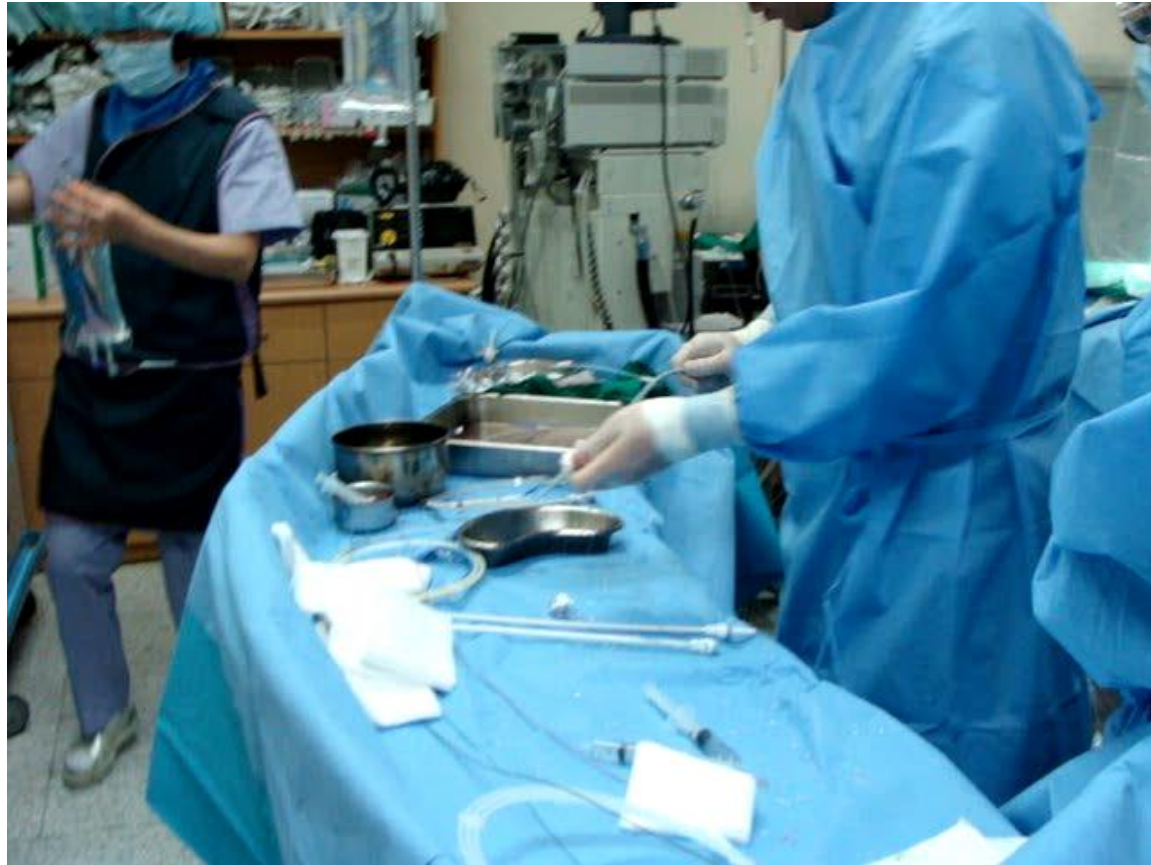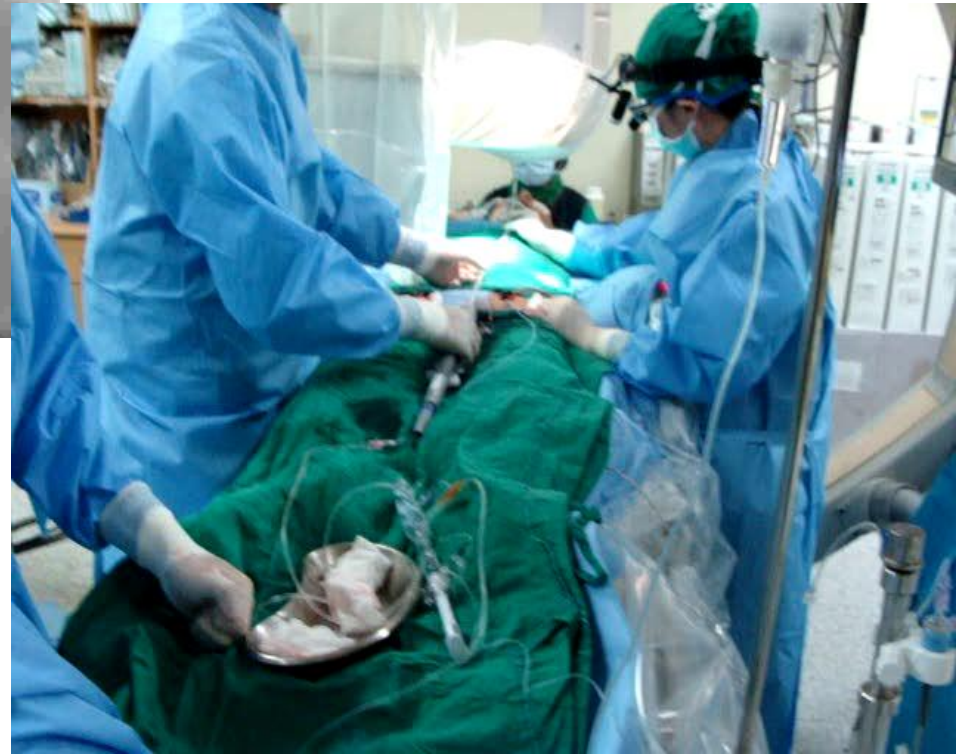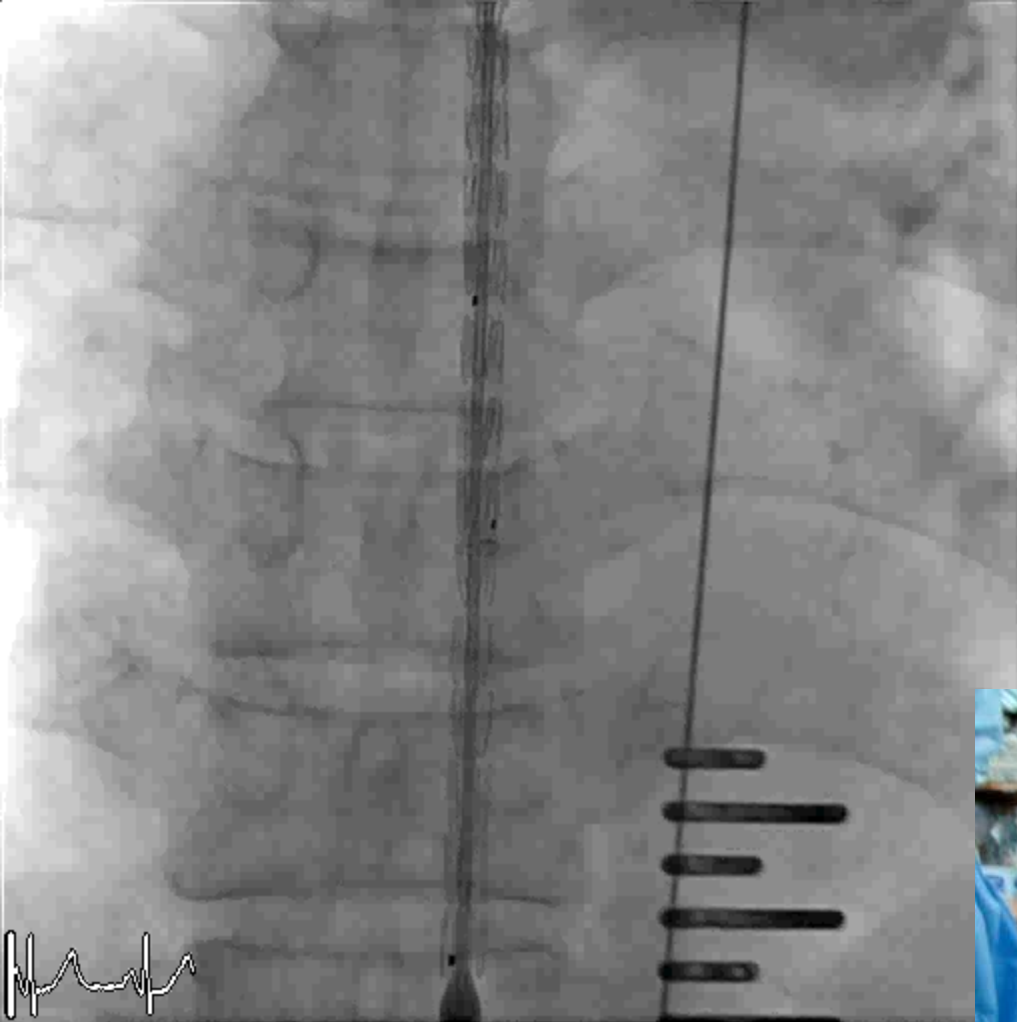


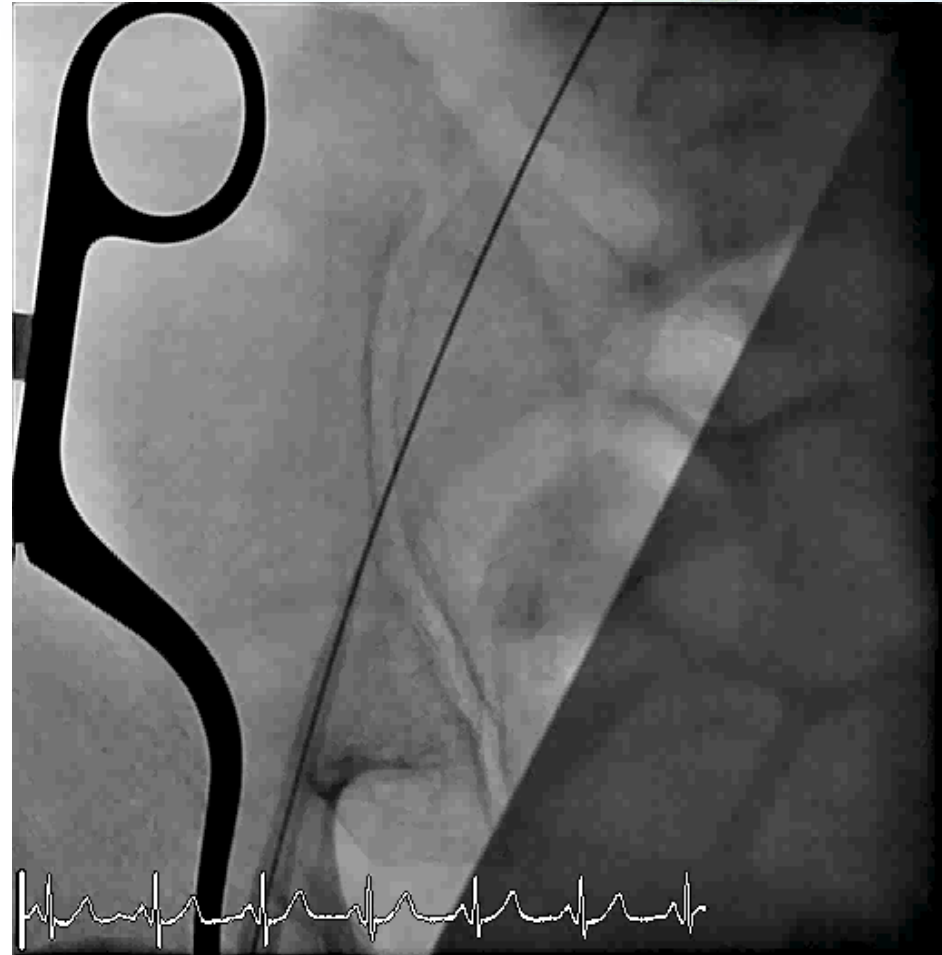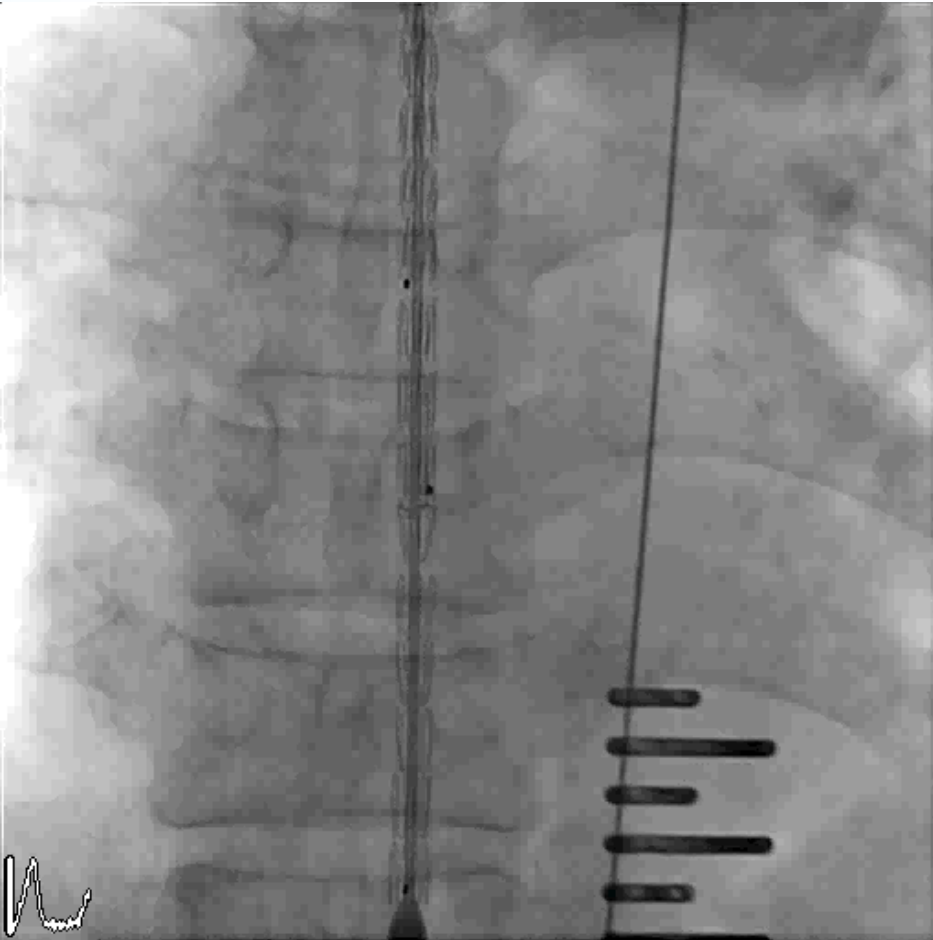


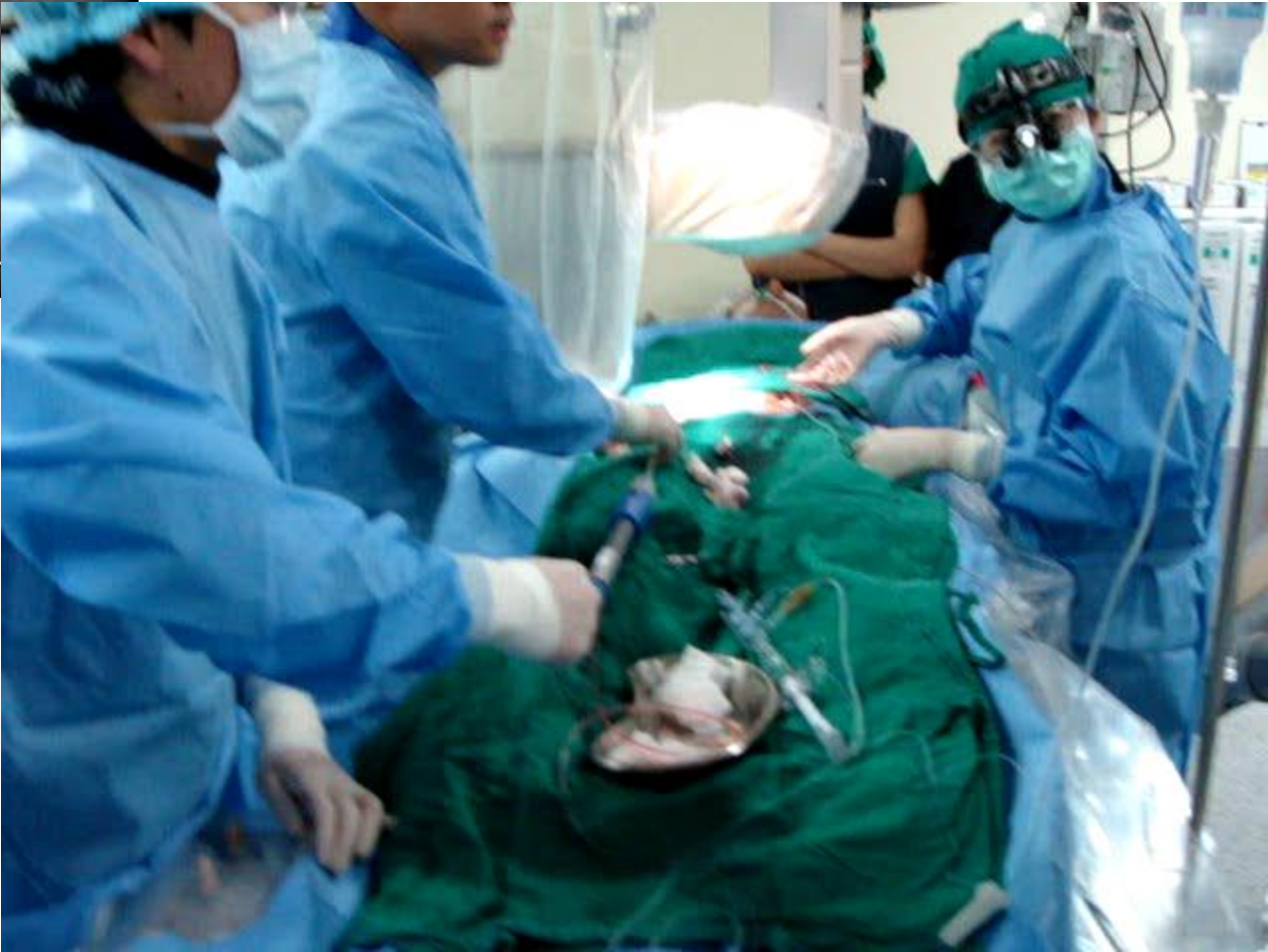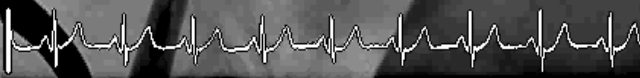
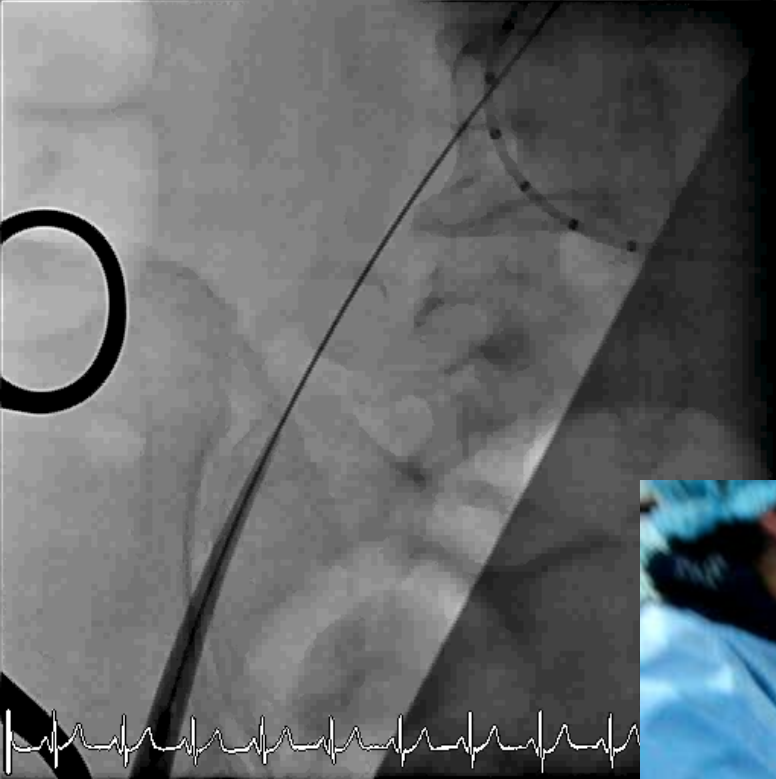


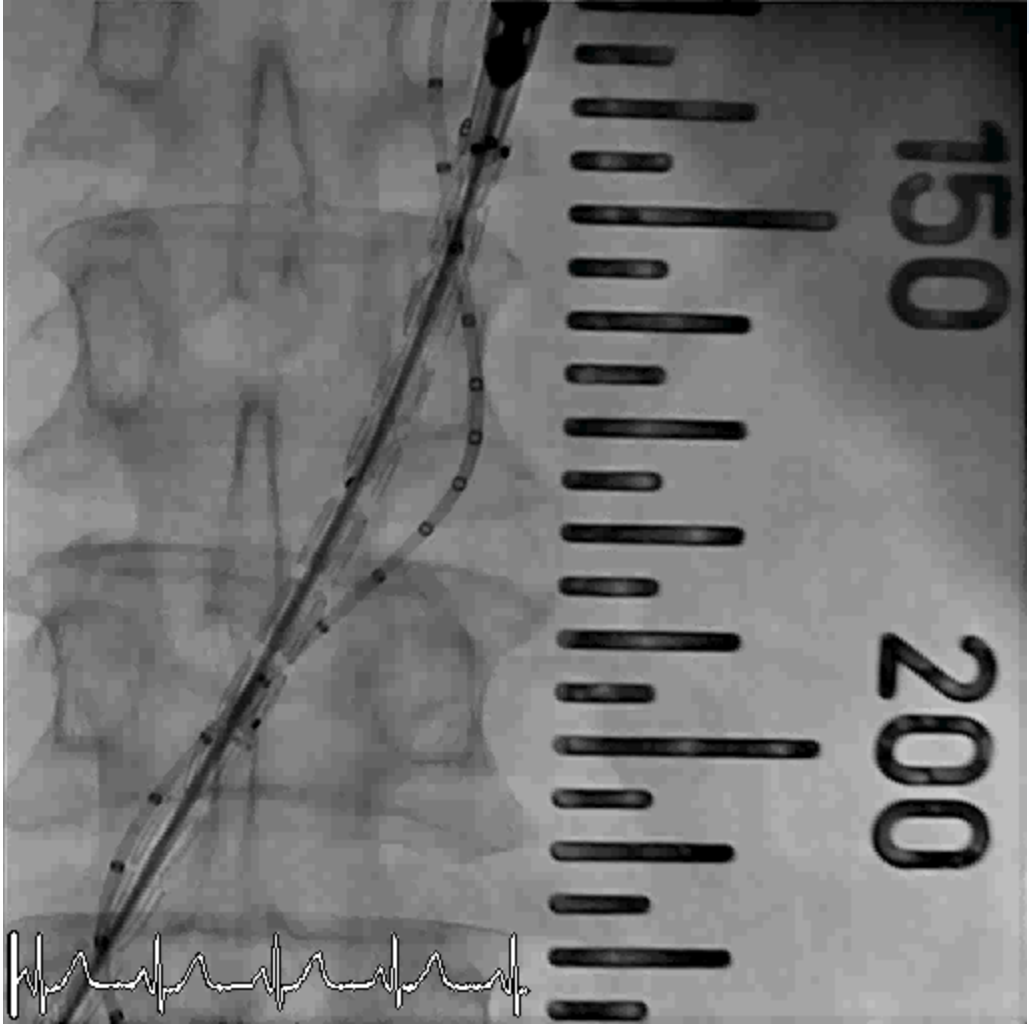


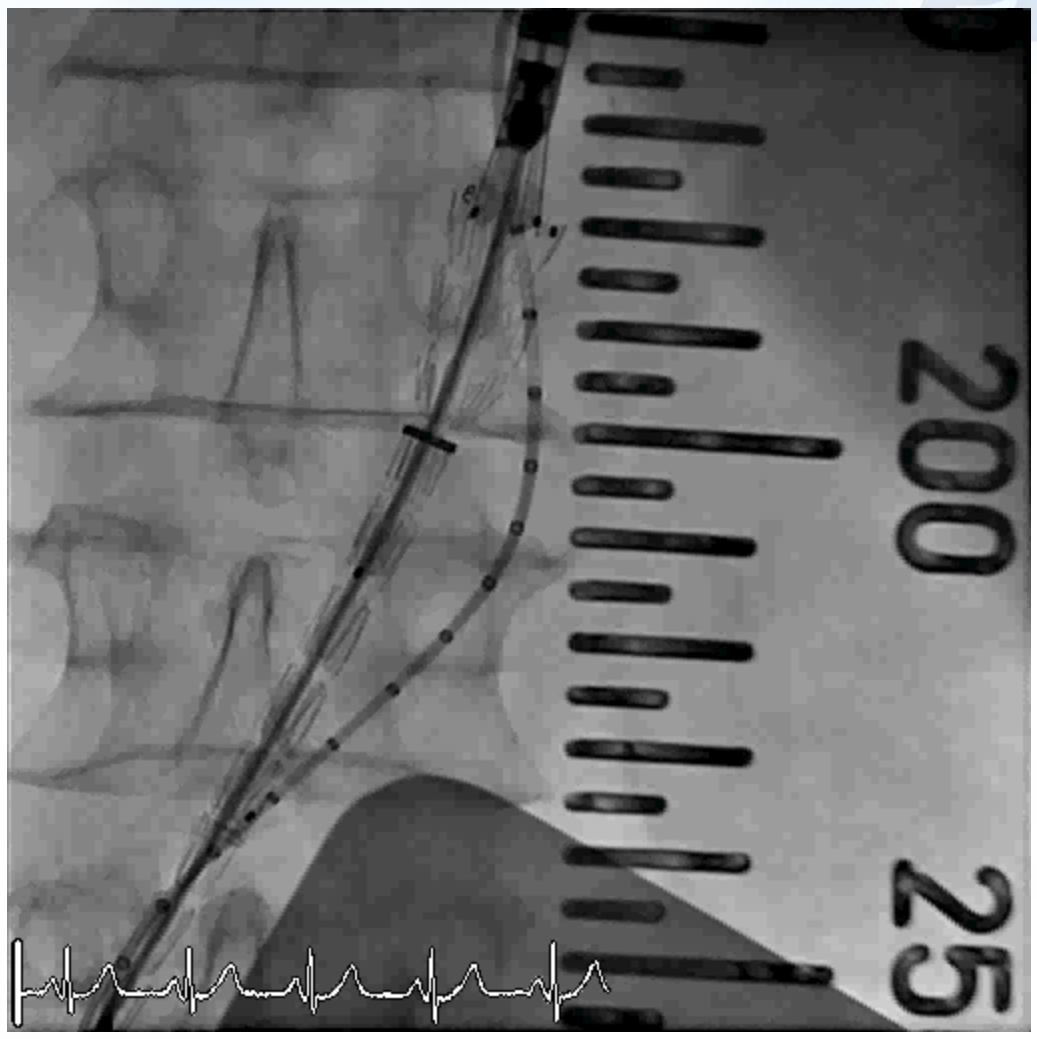


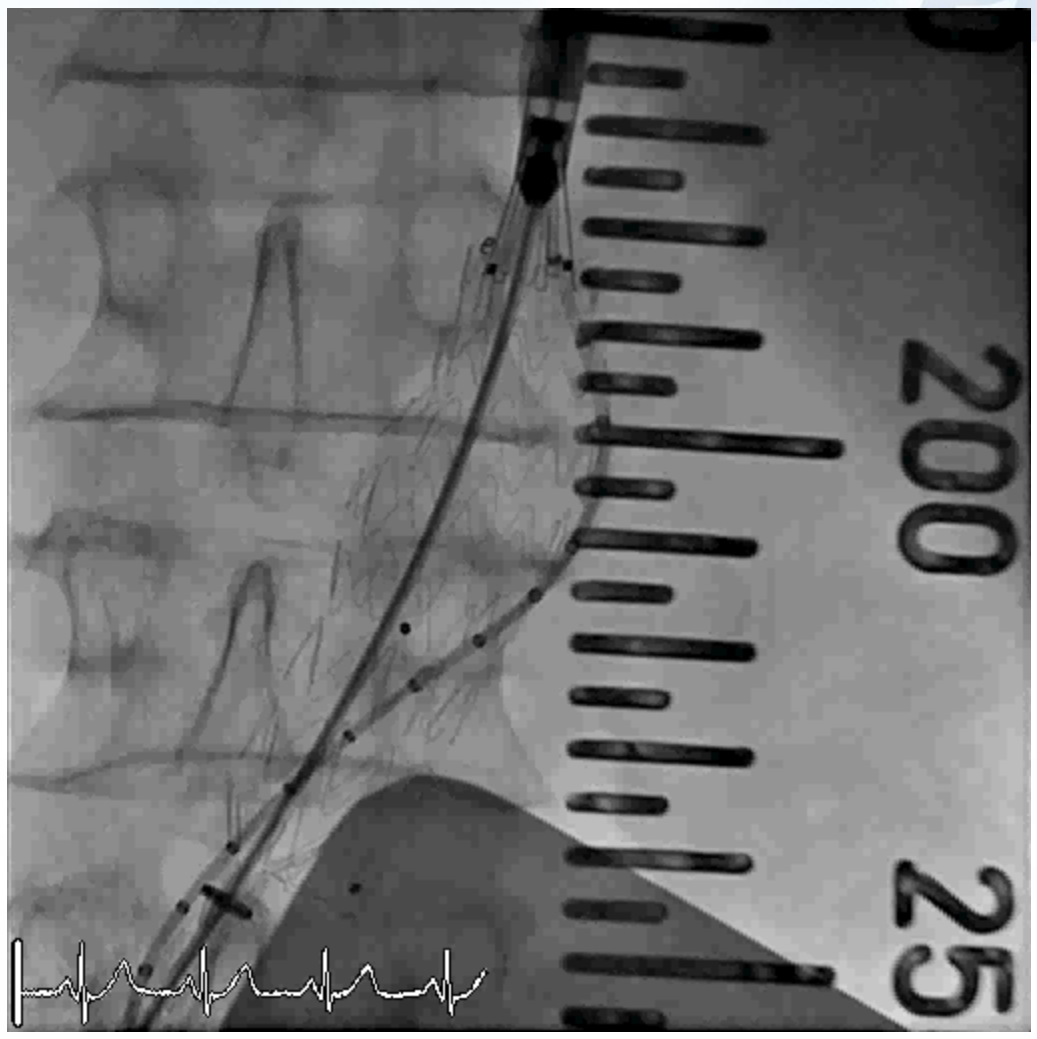




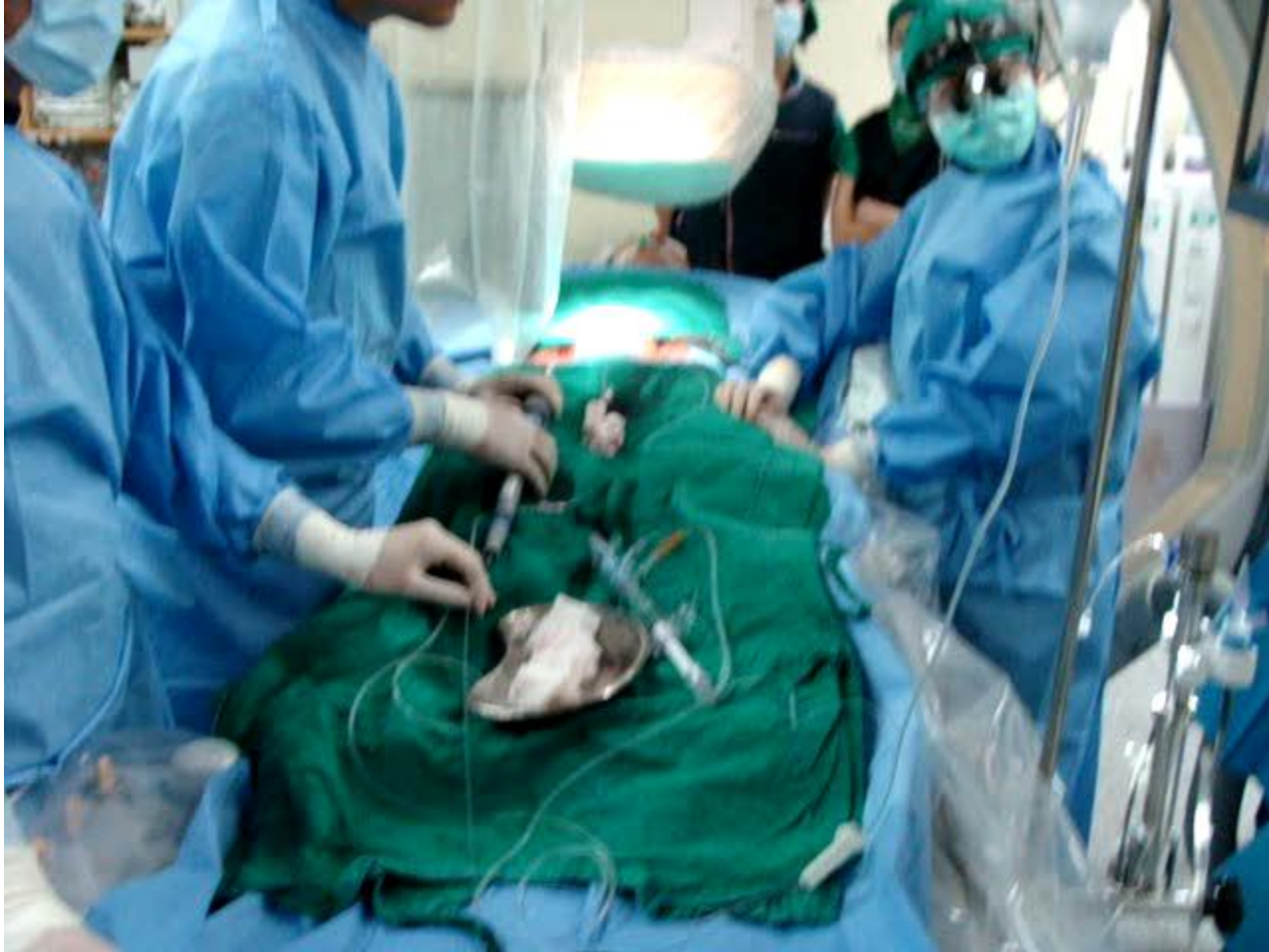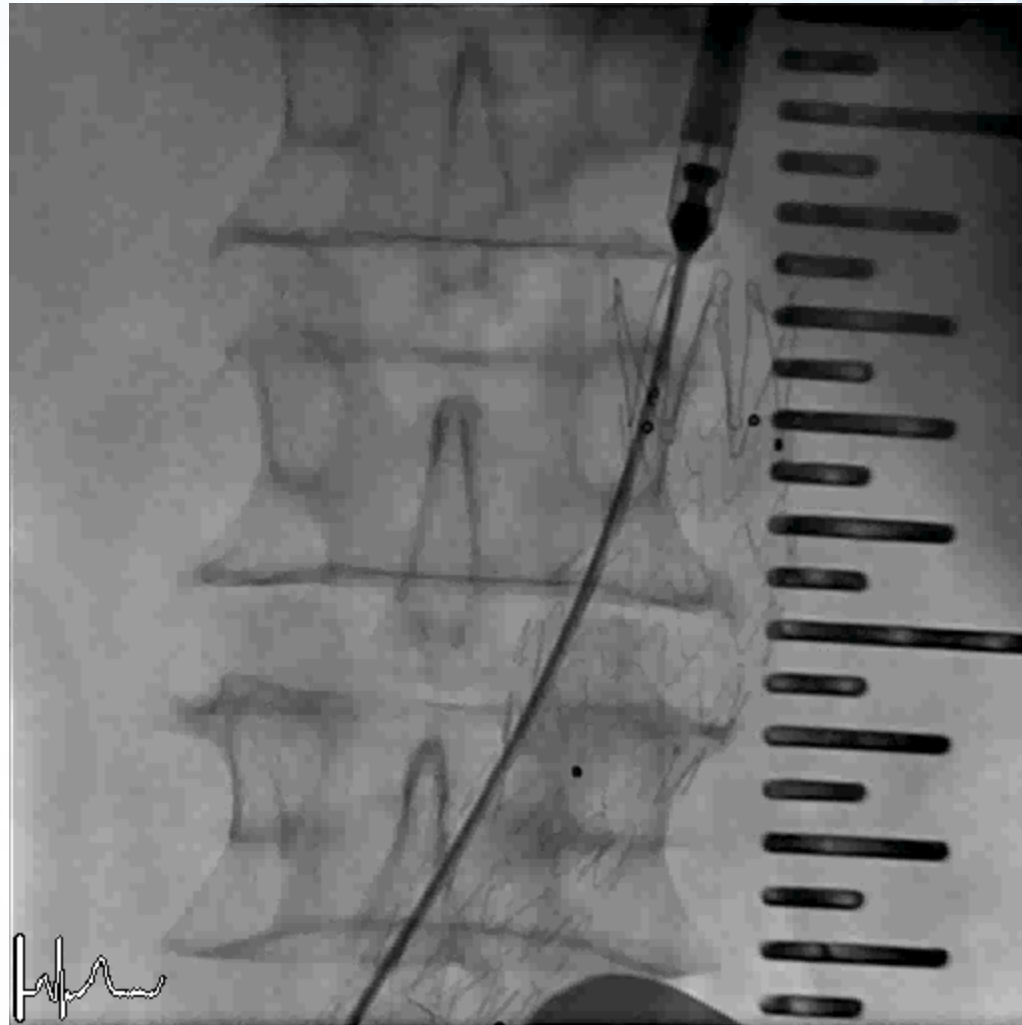


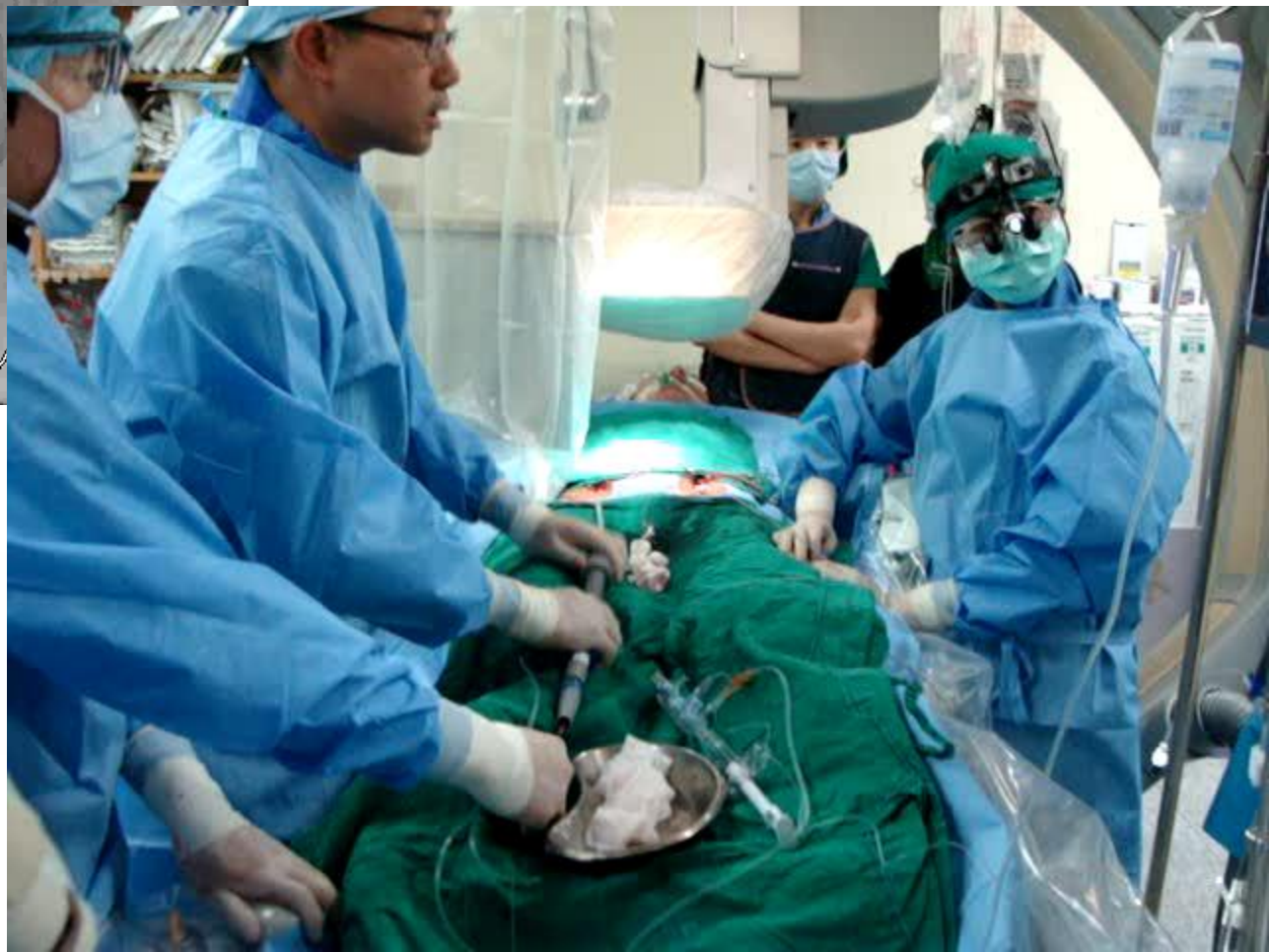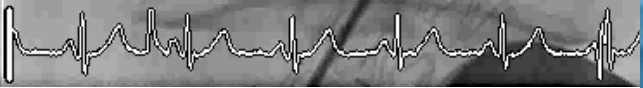
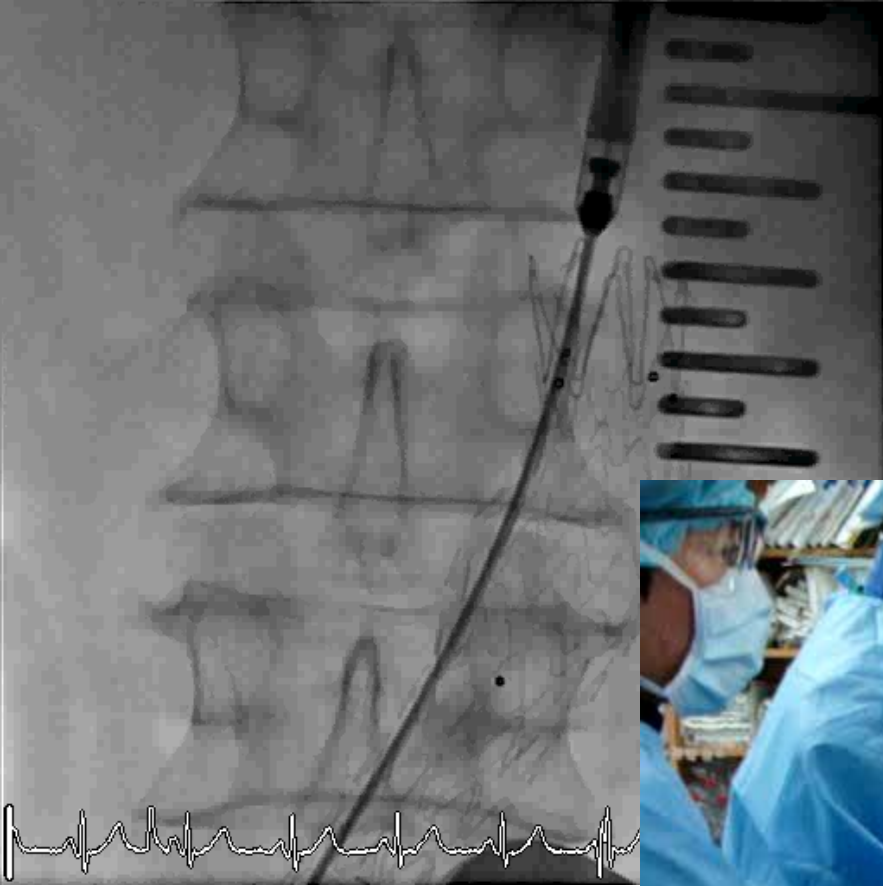


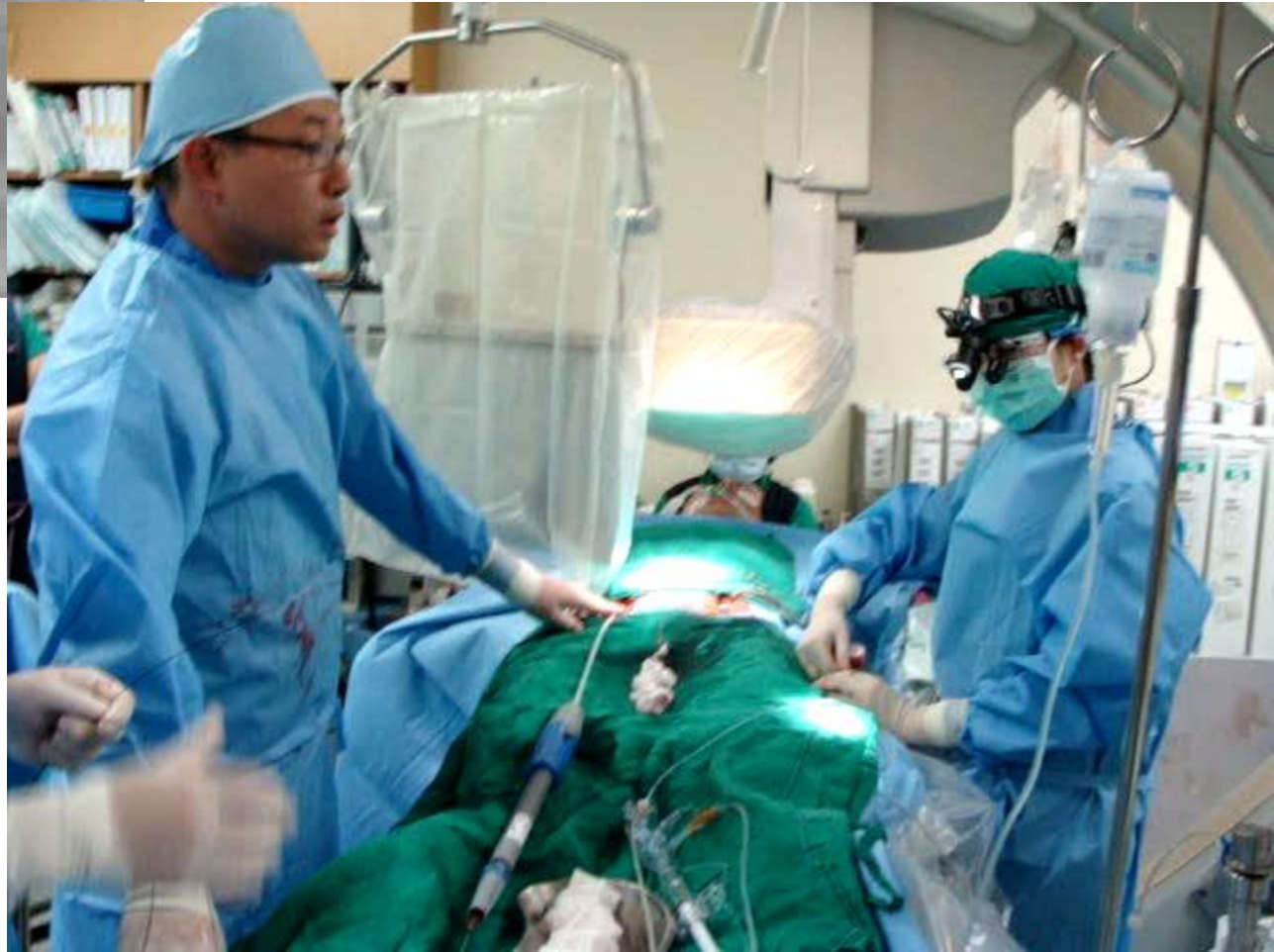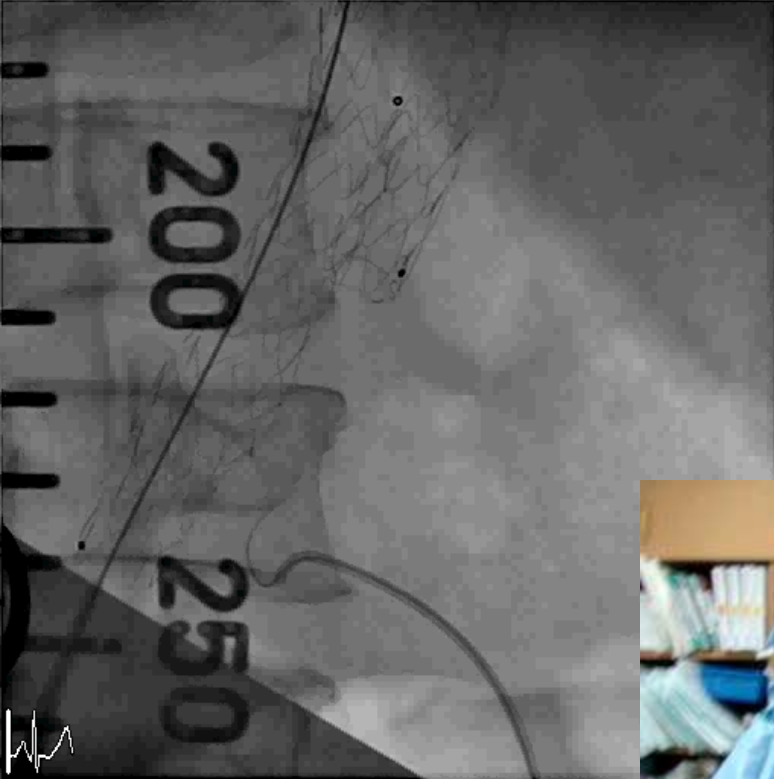


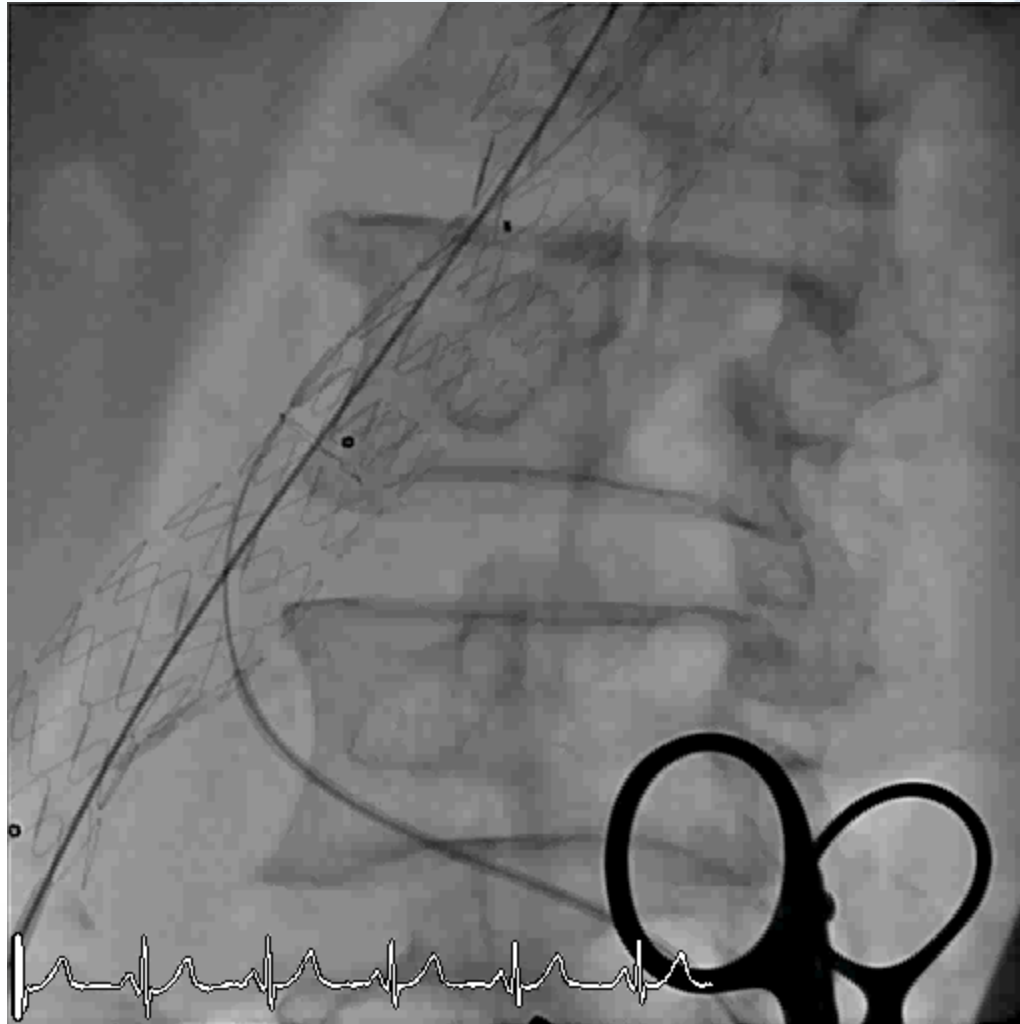


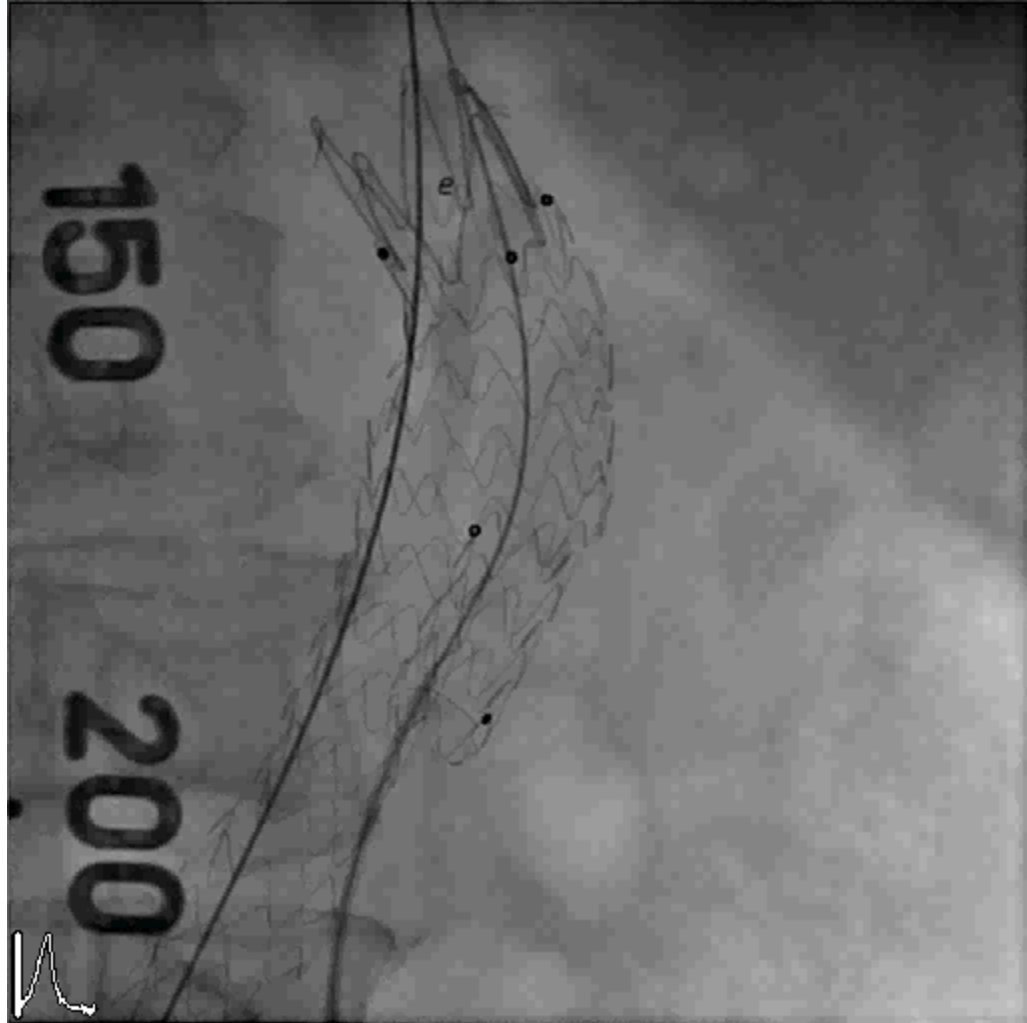


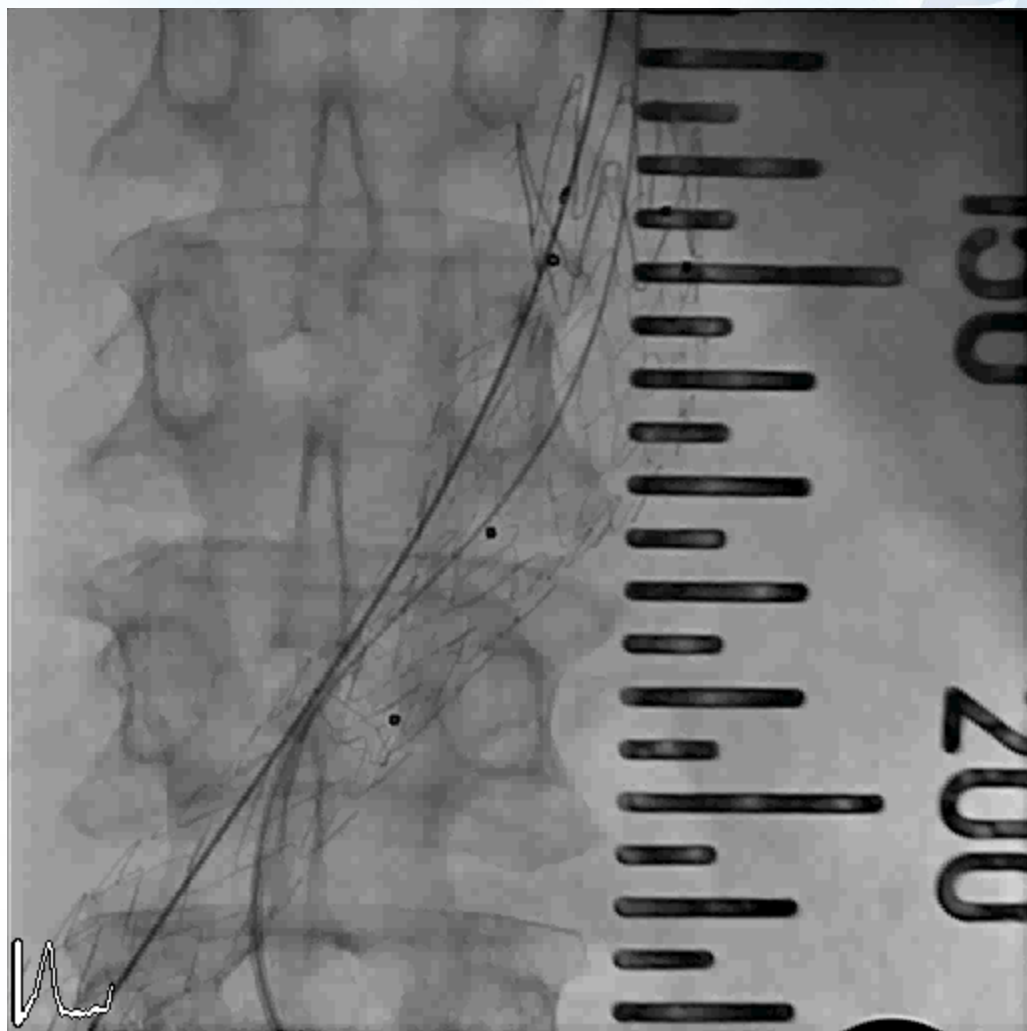




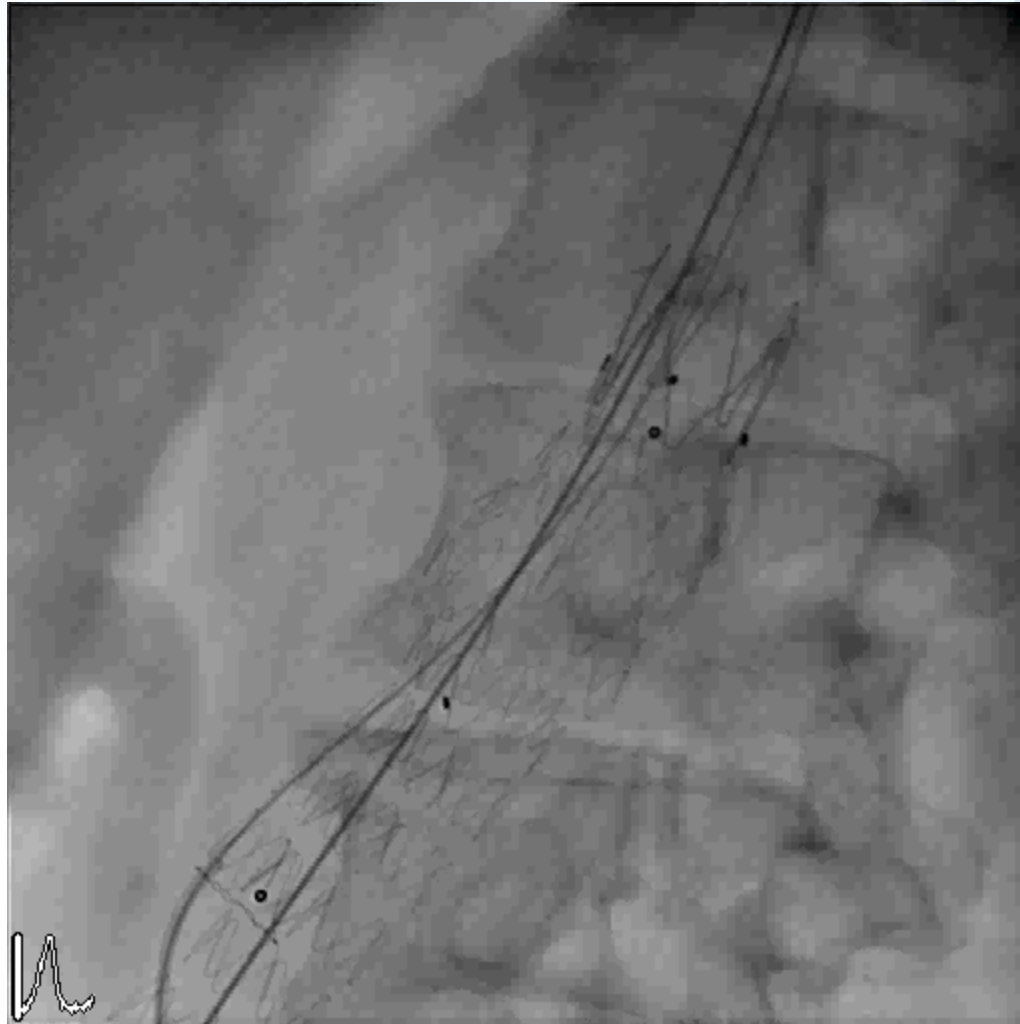


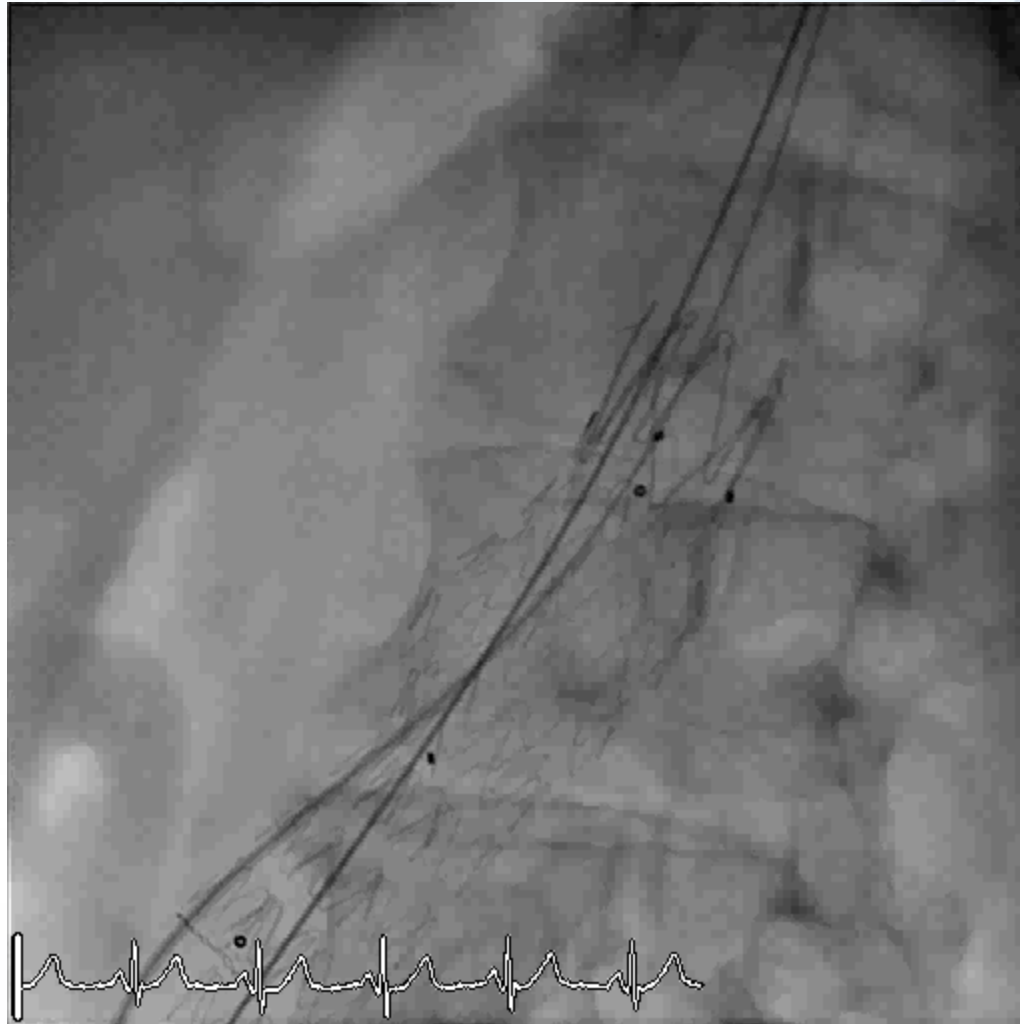


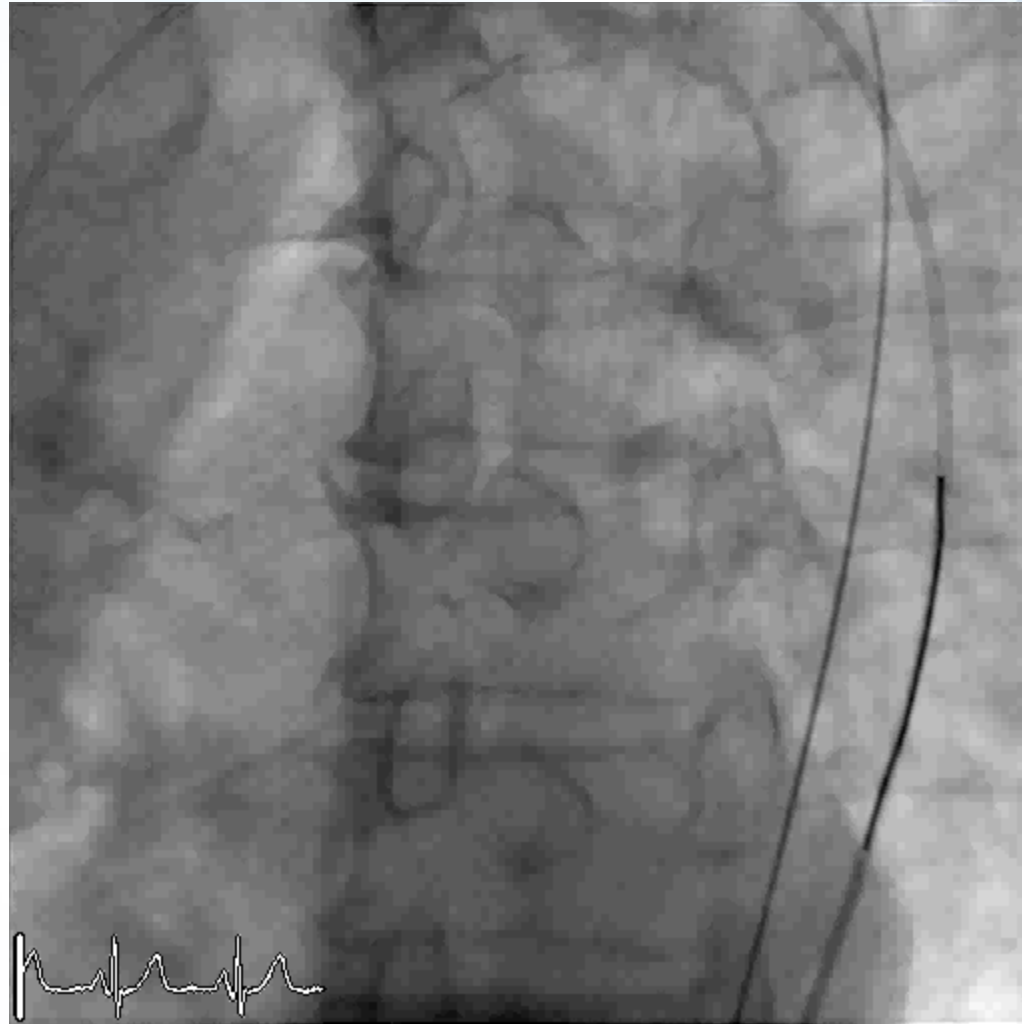


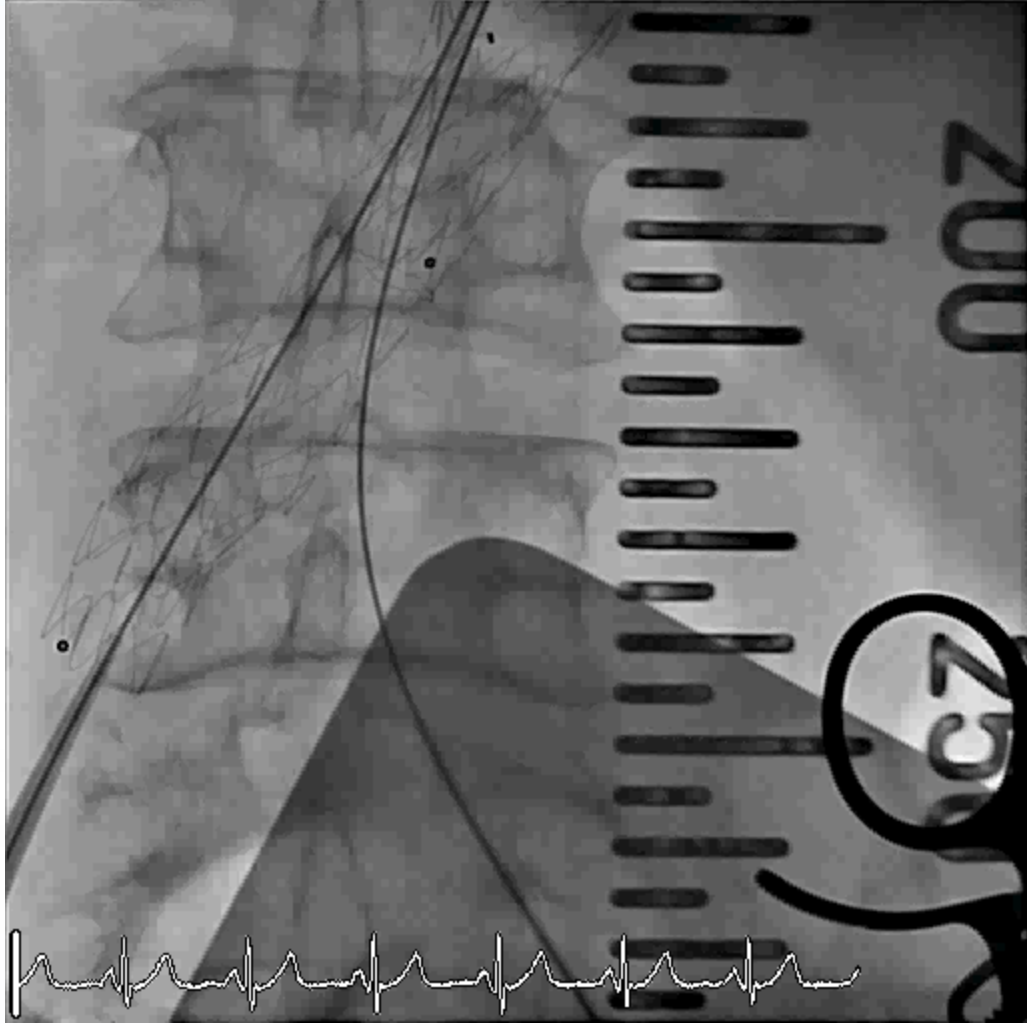


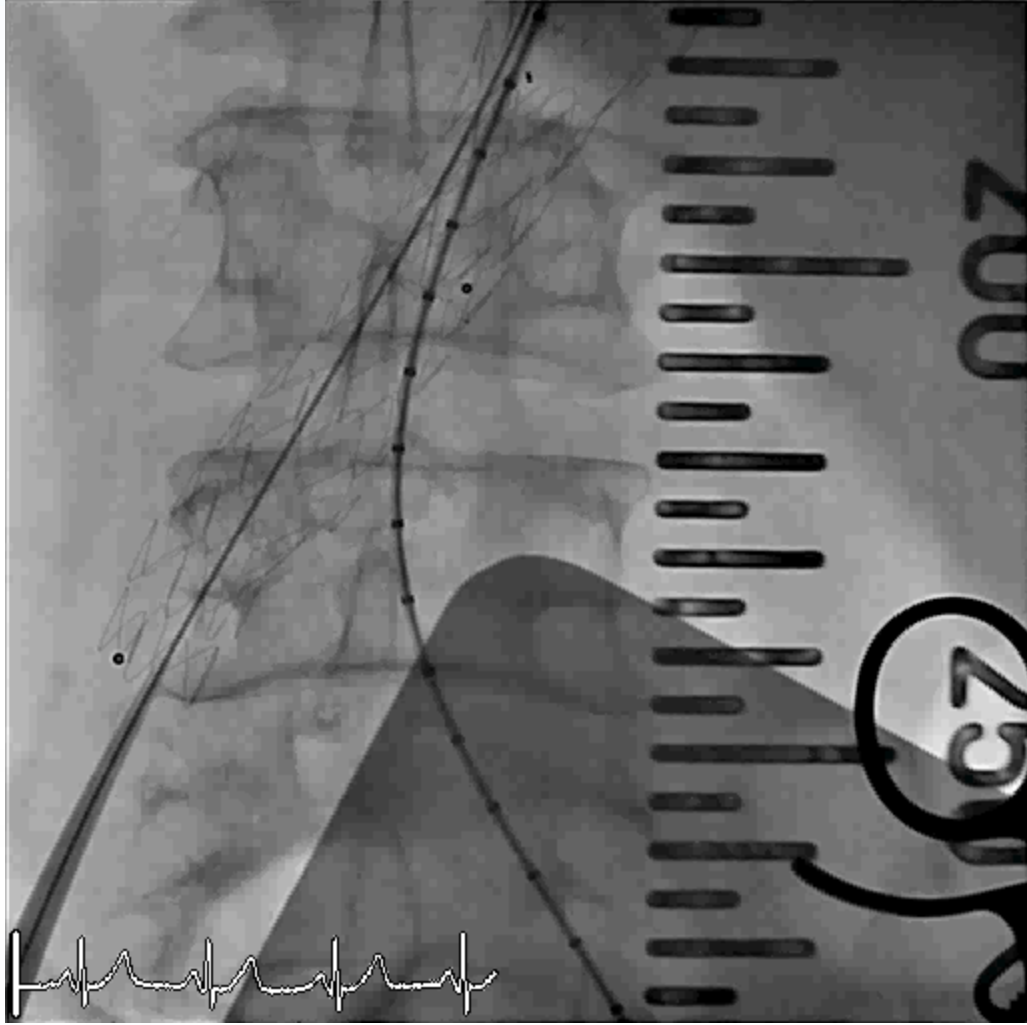
W

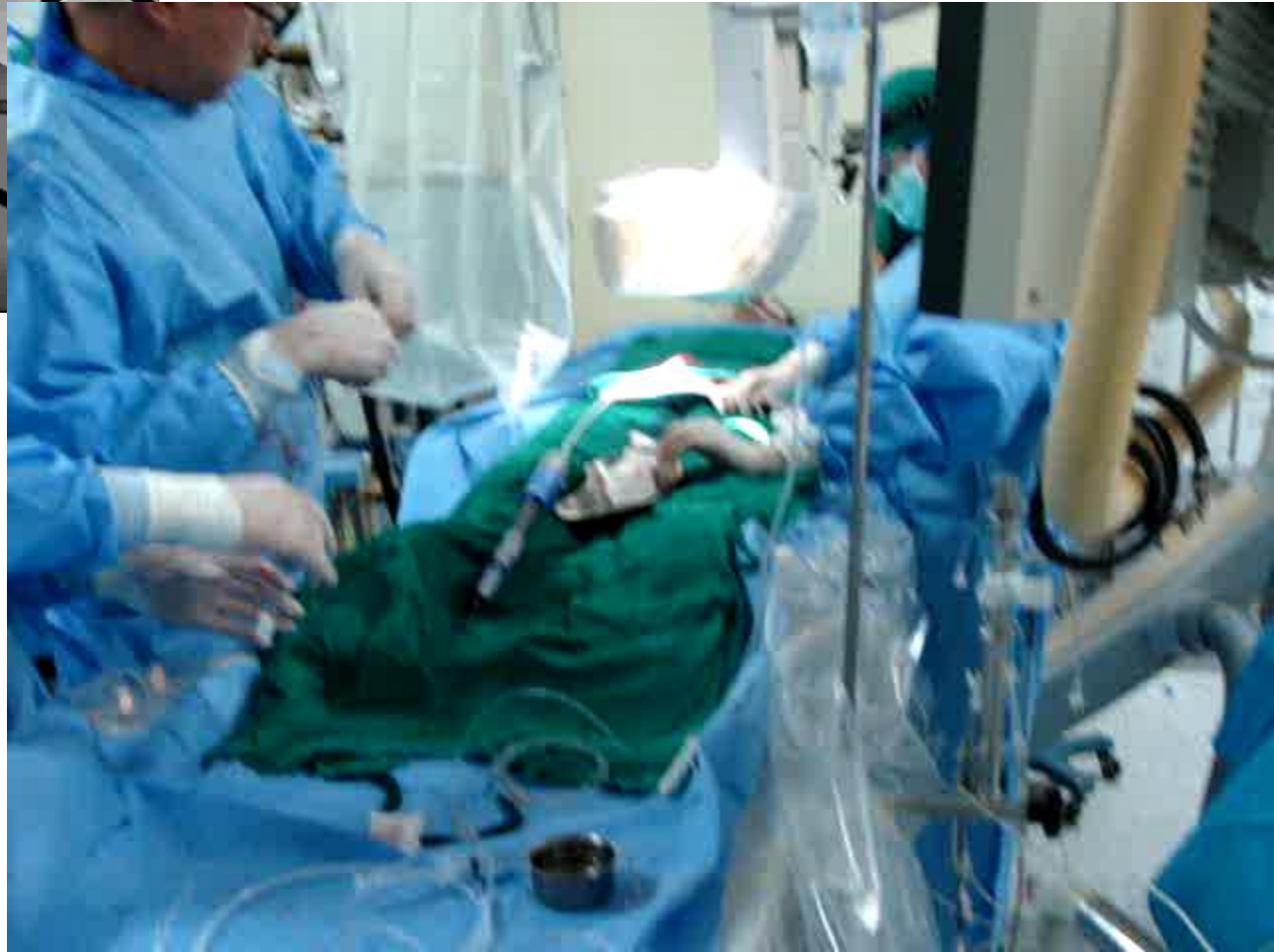
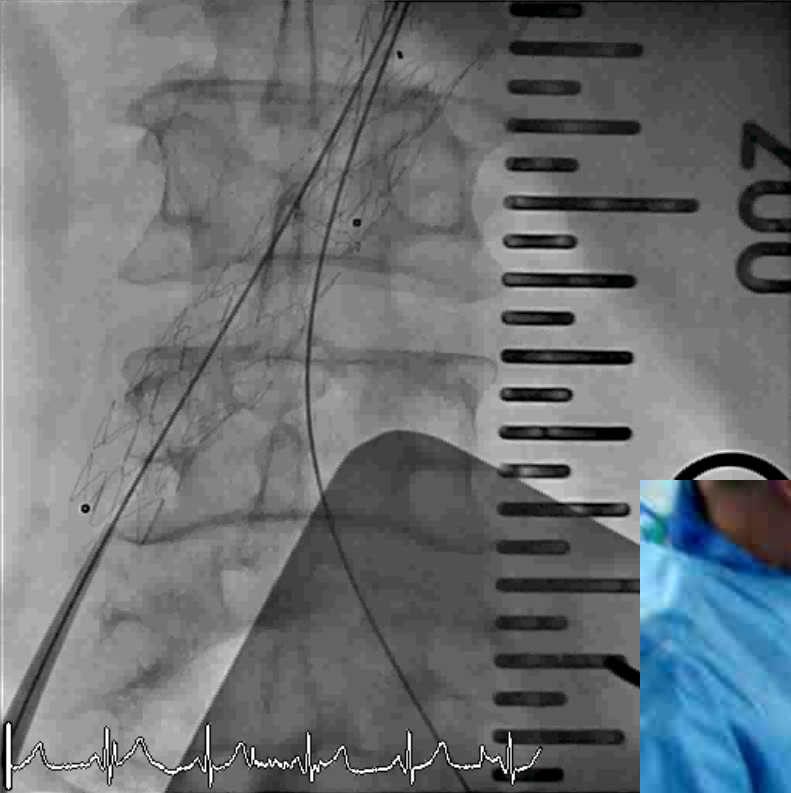
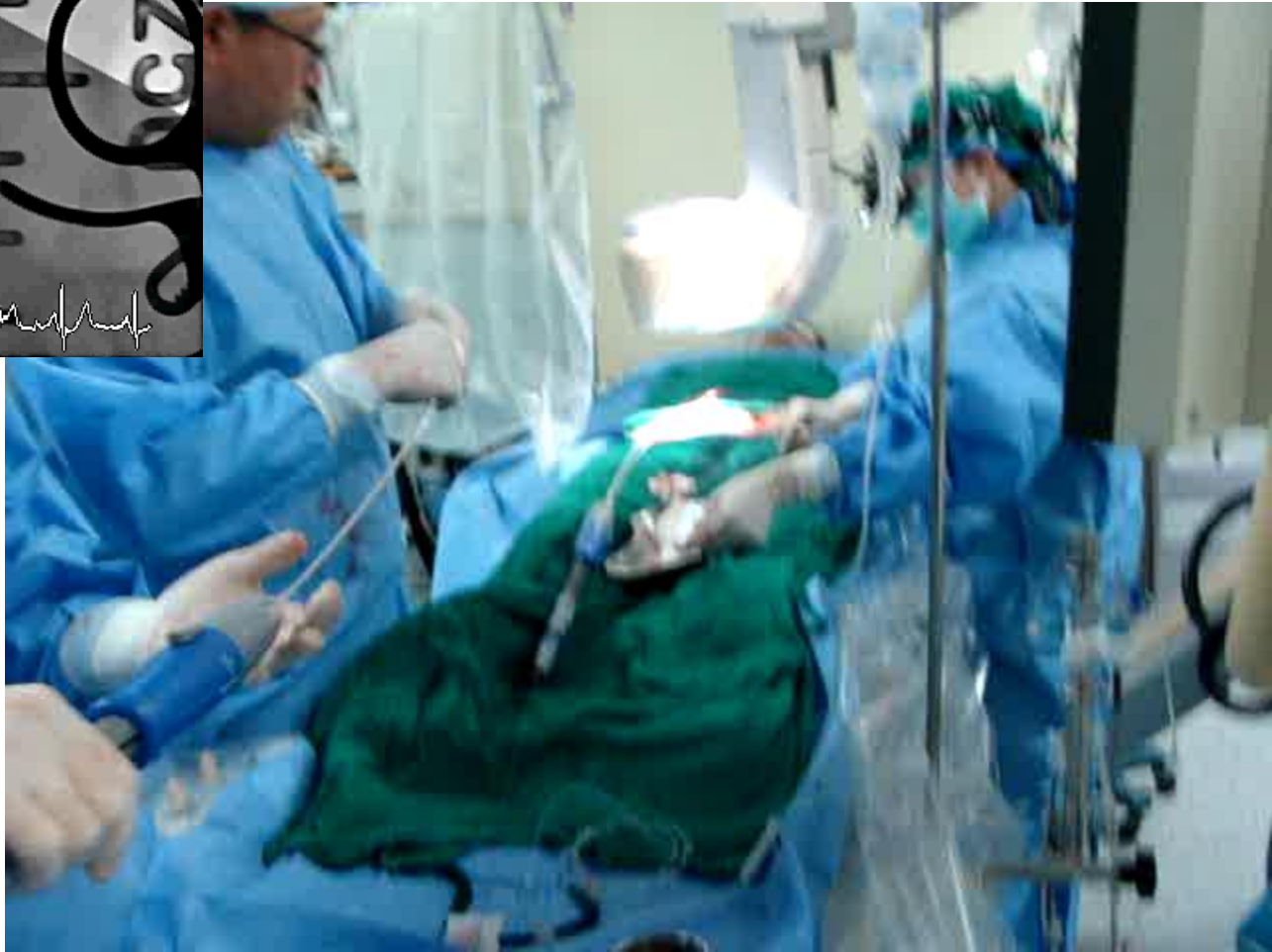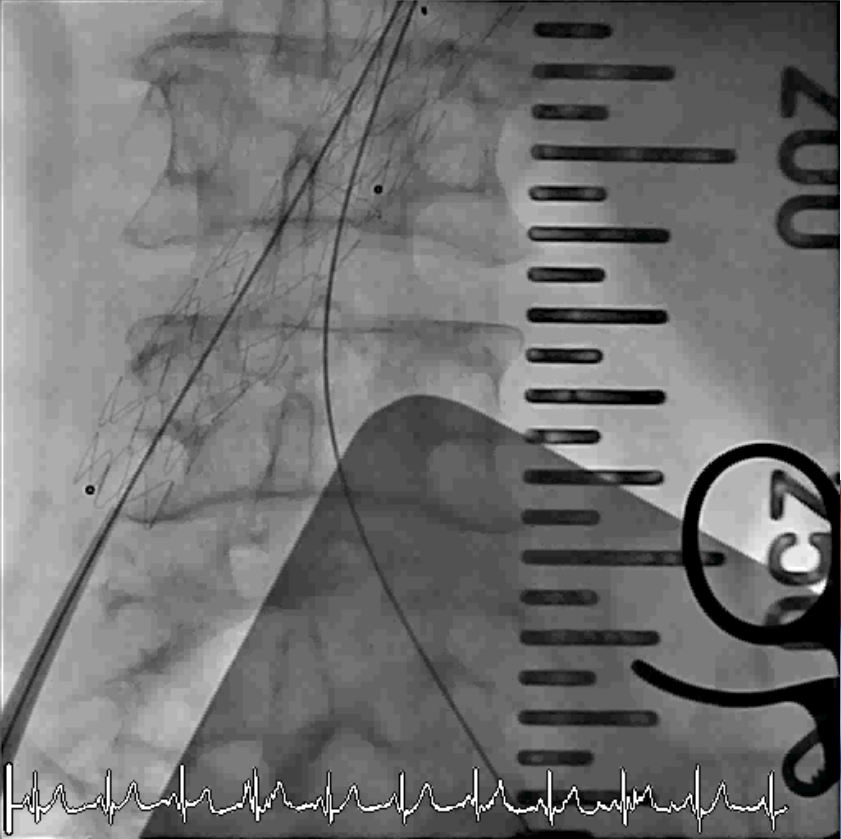


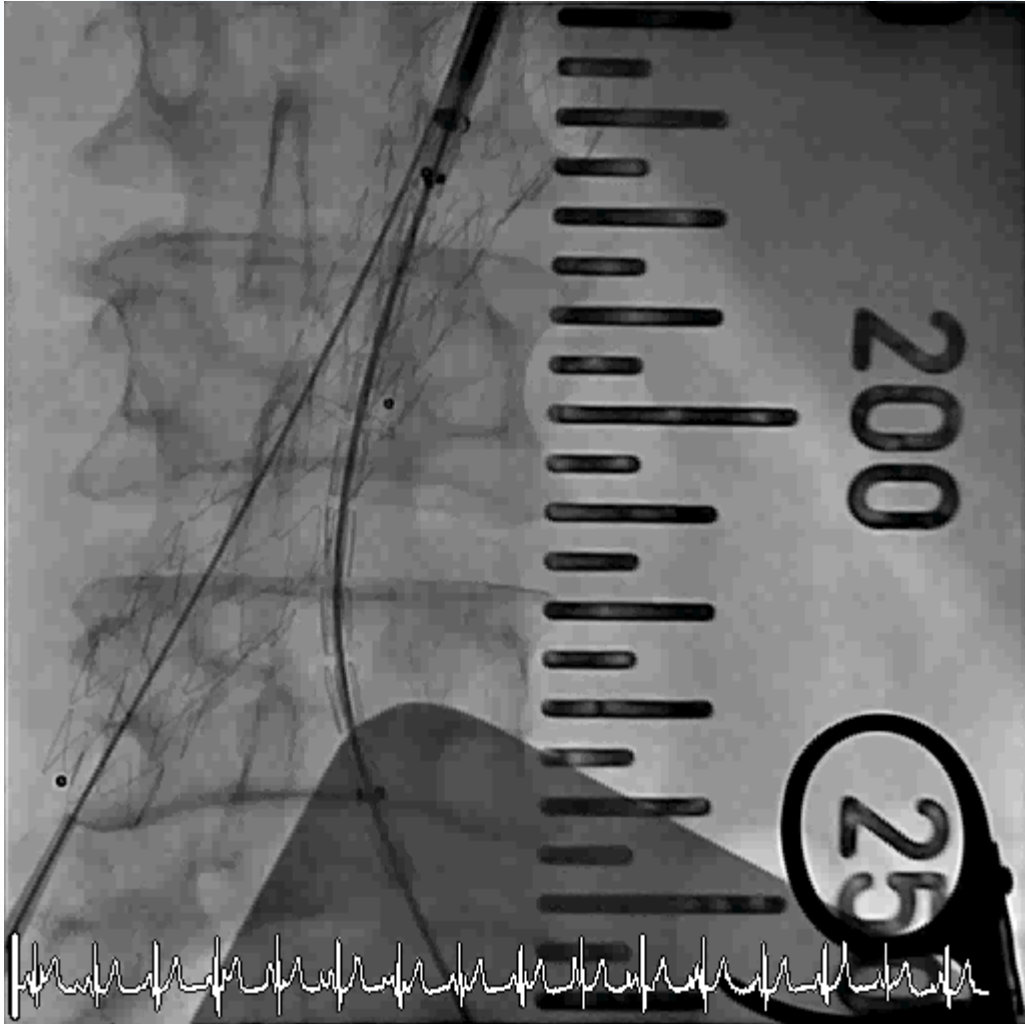


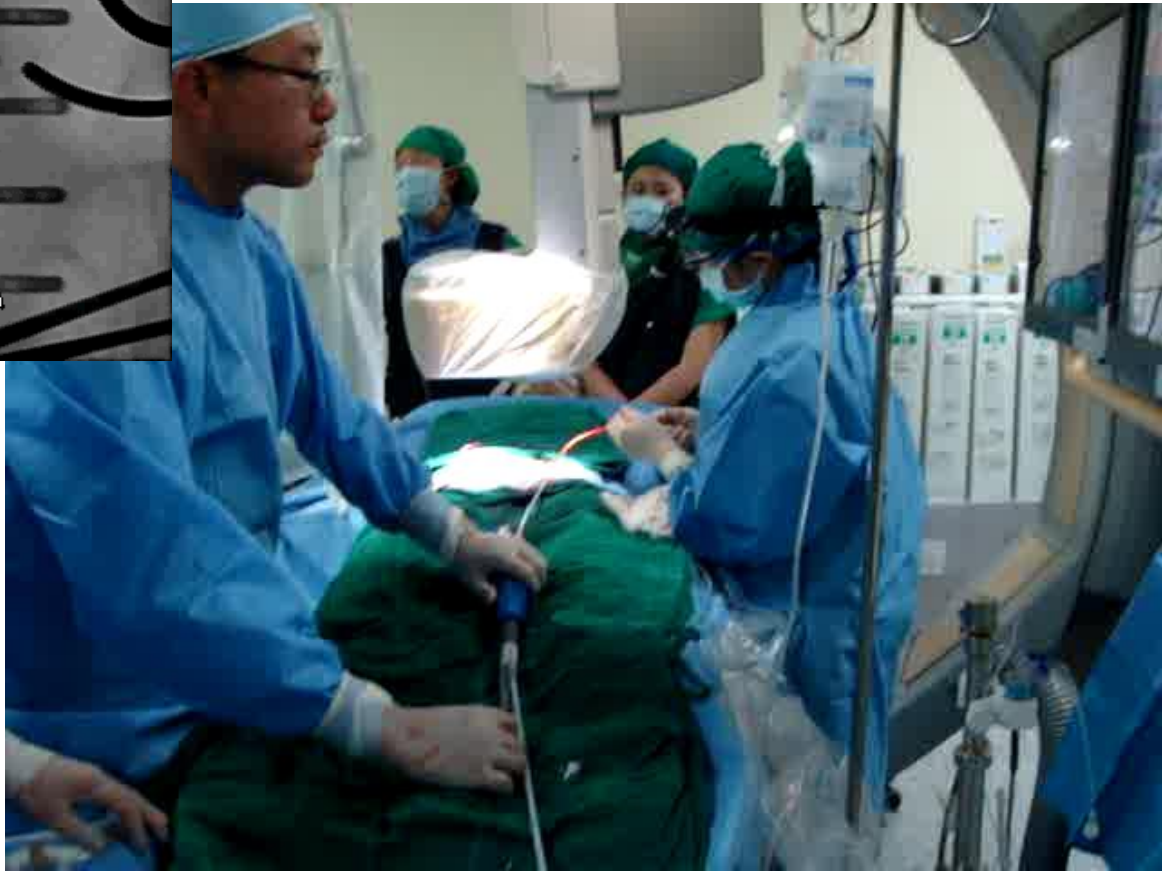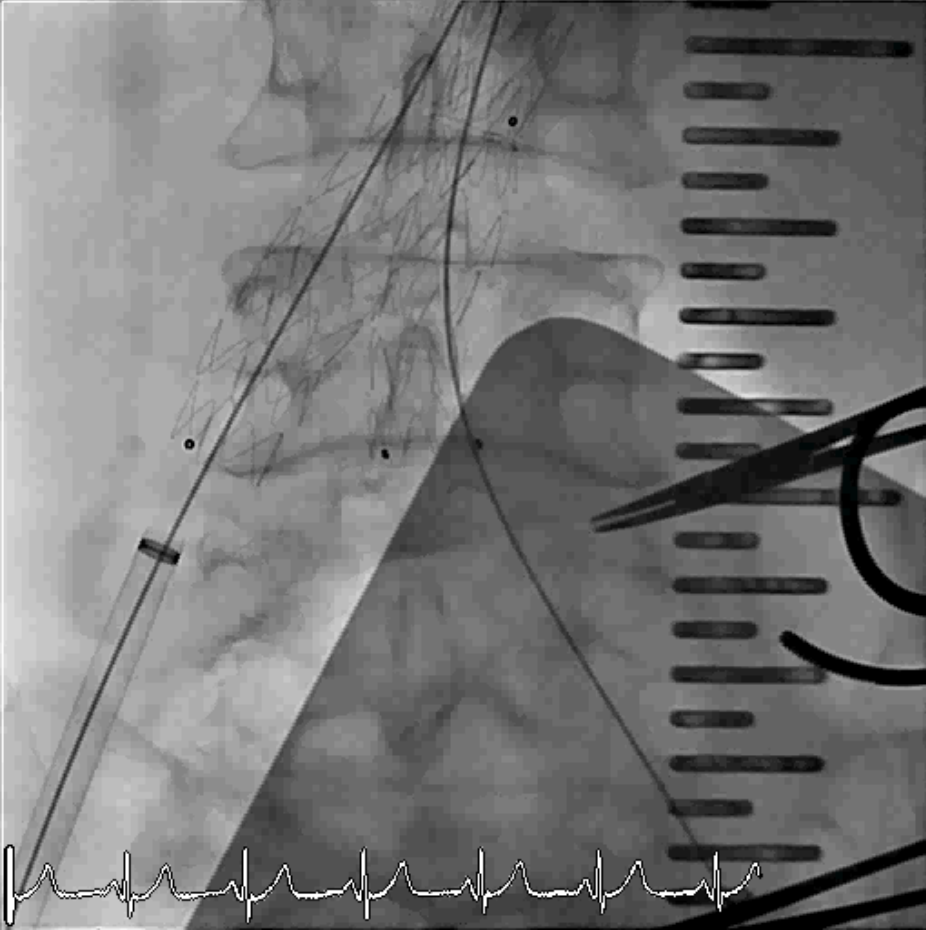


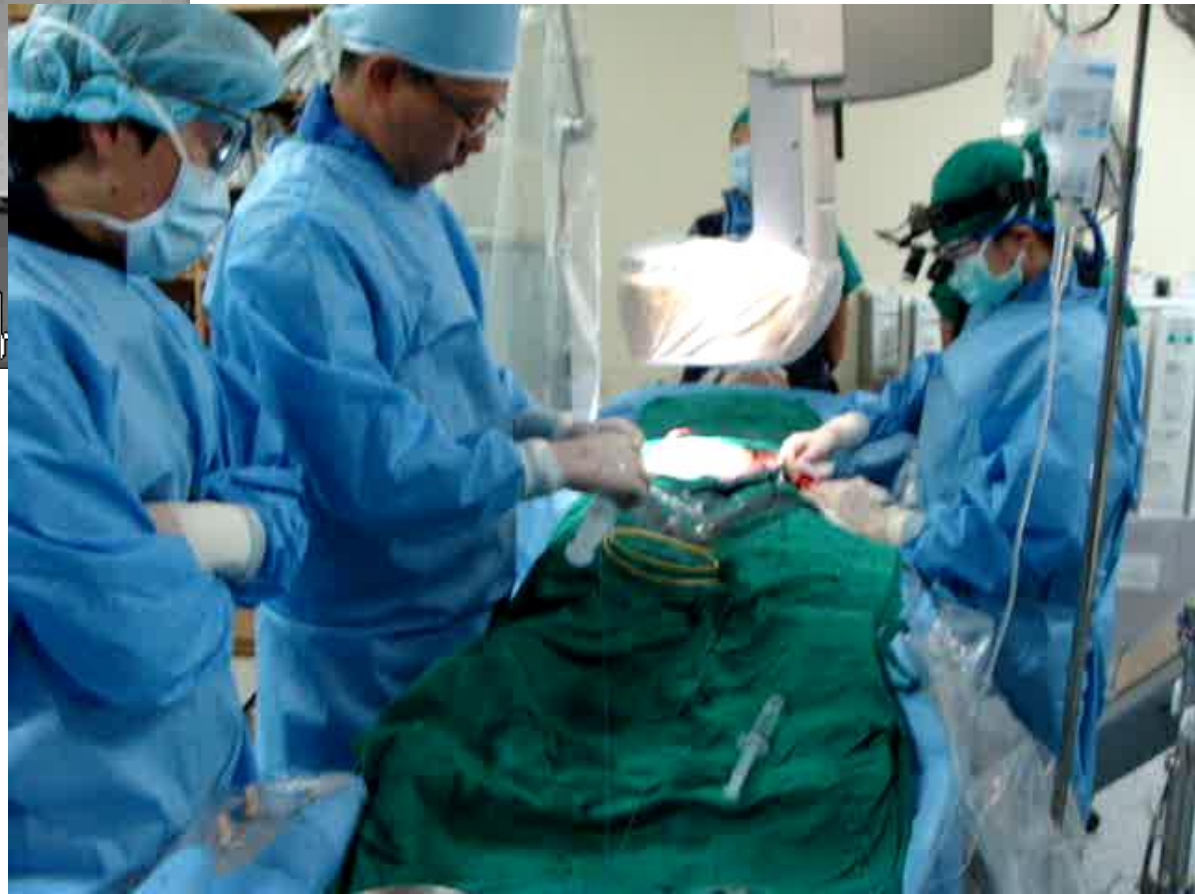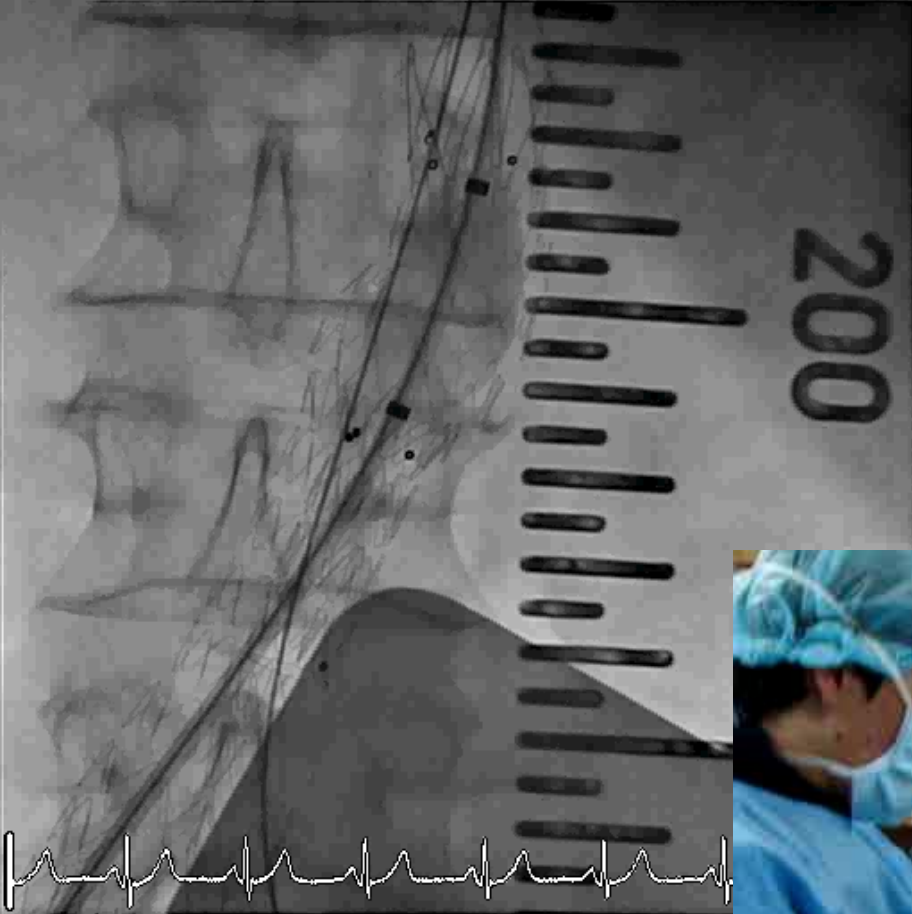


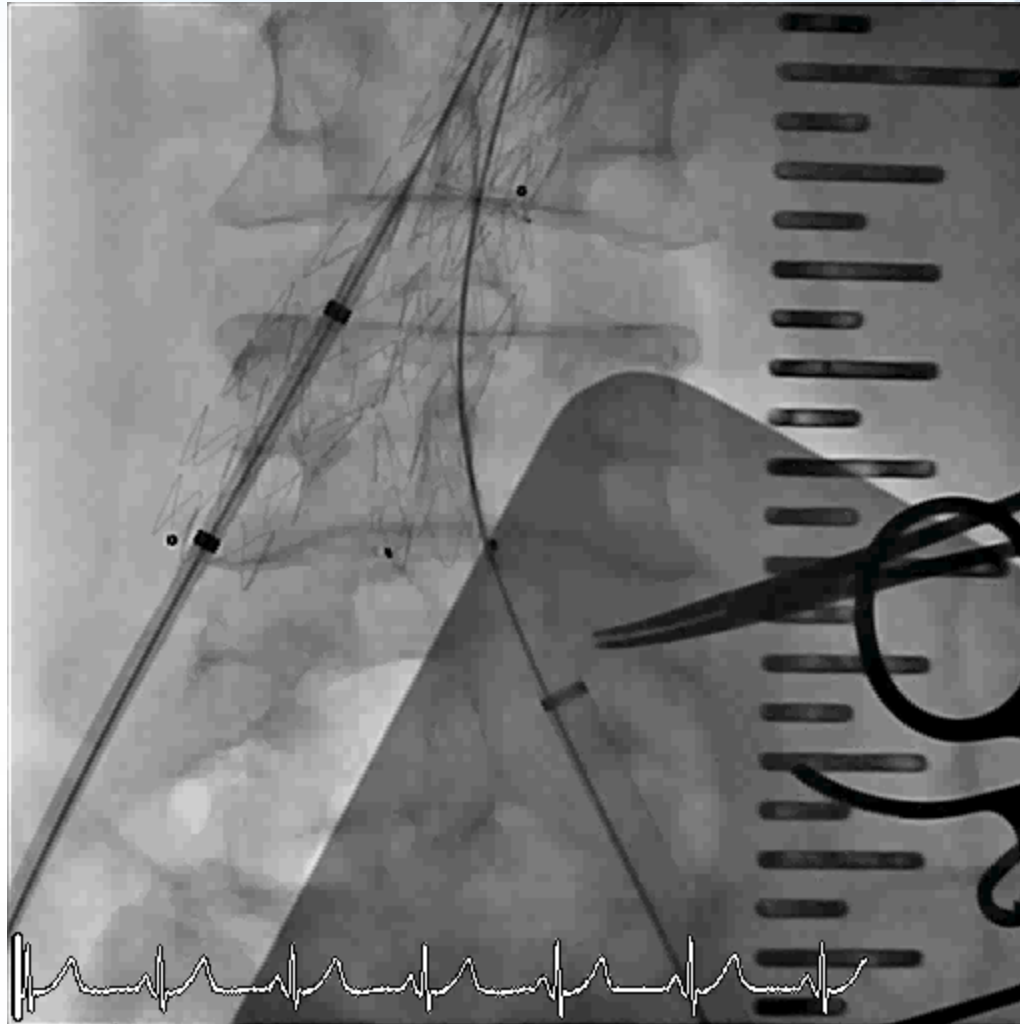


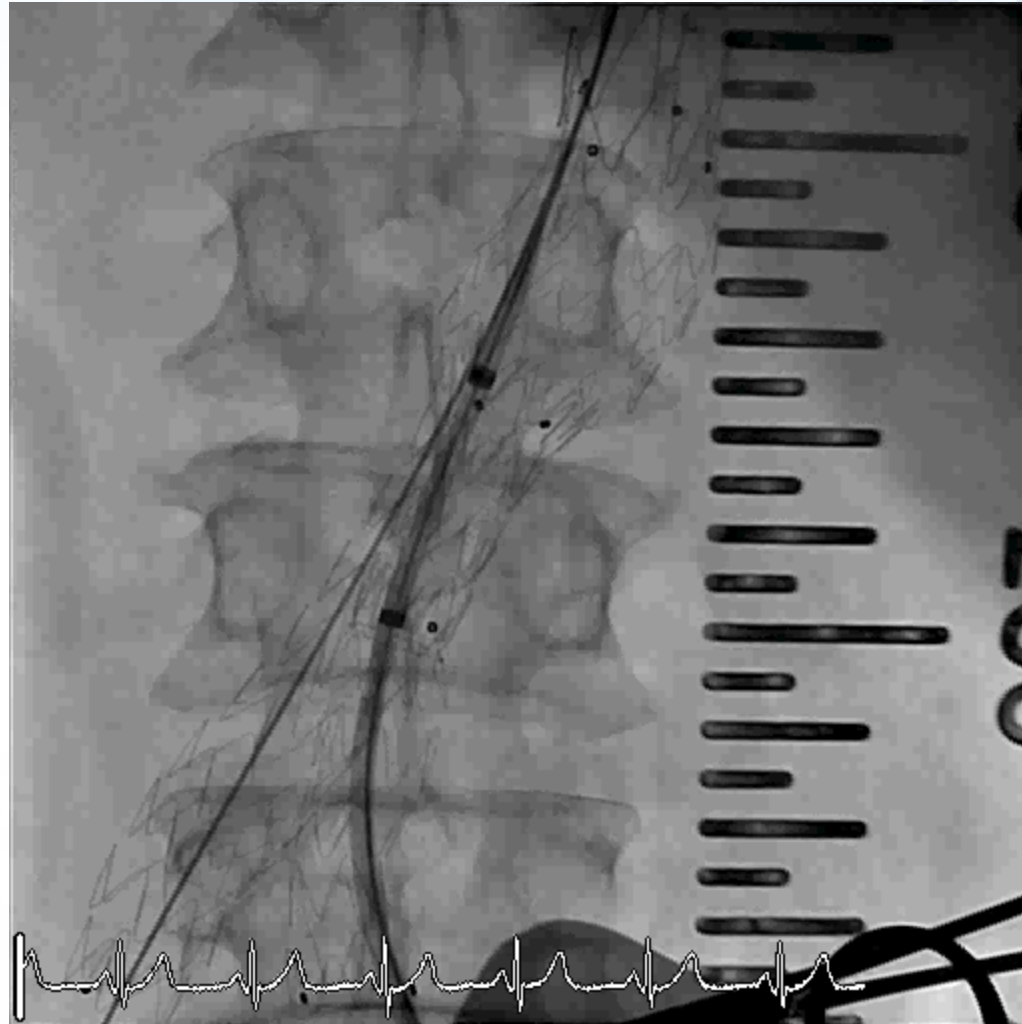


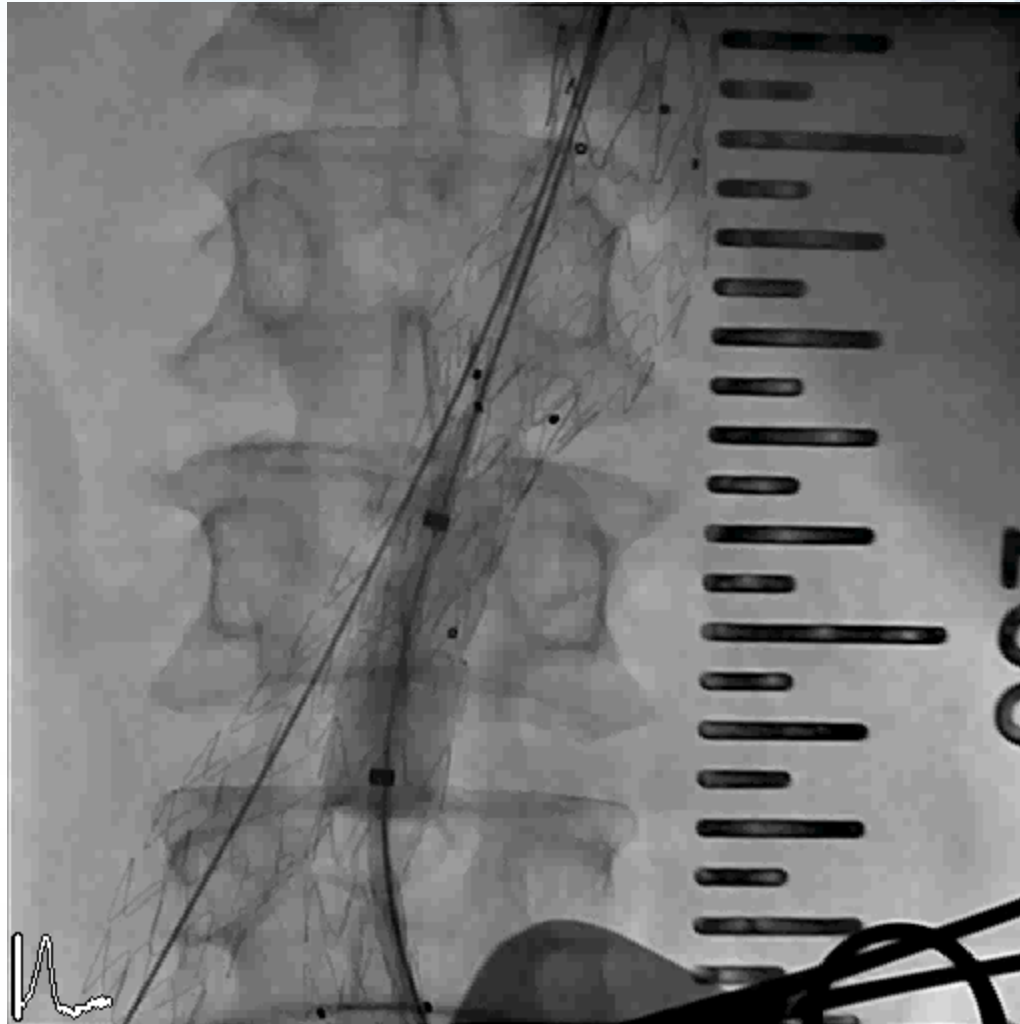


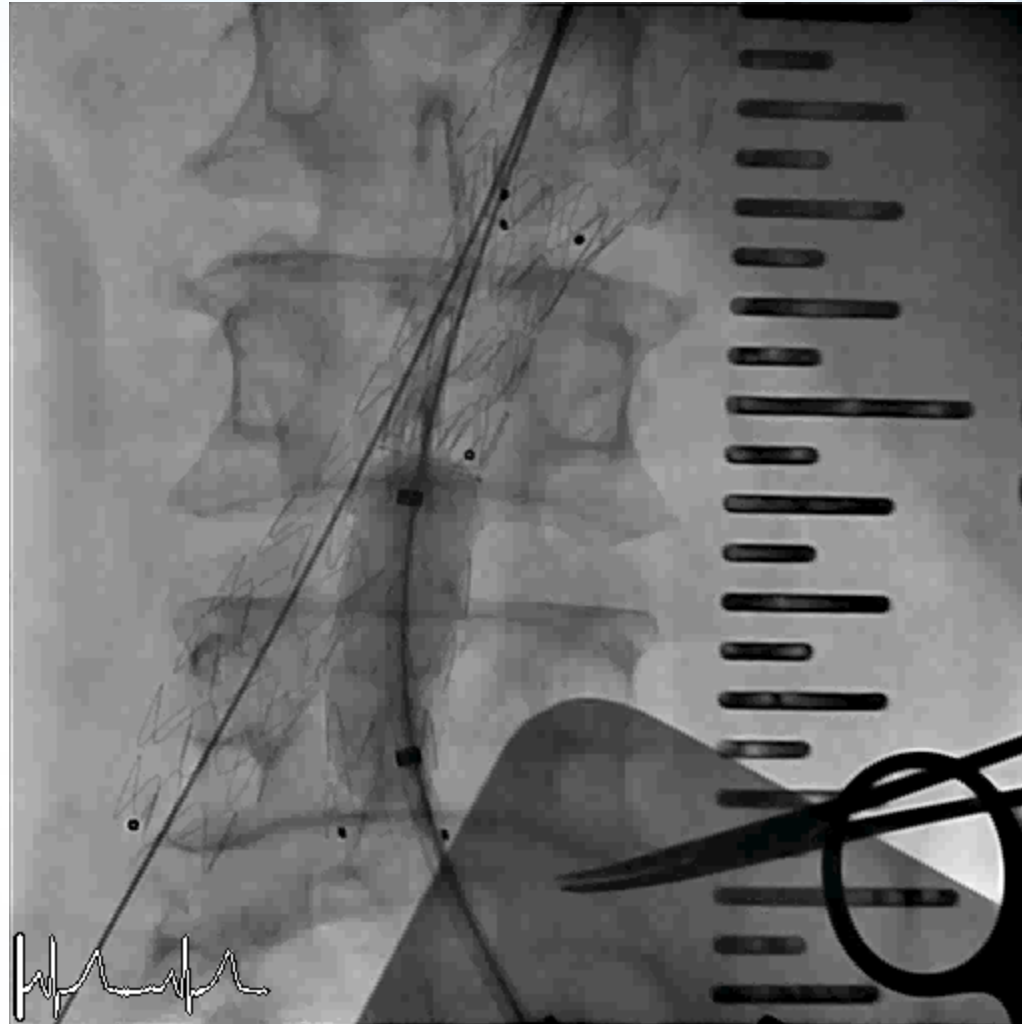


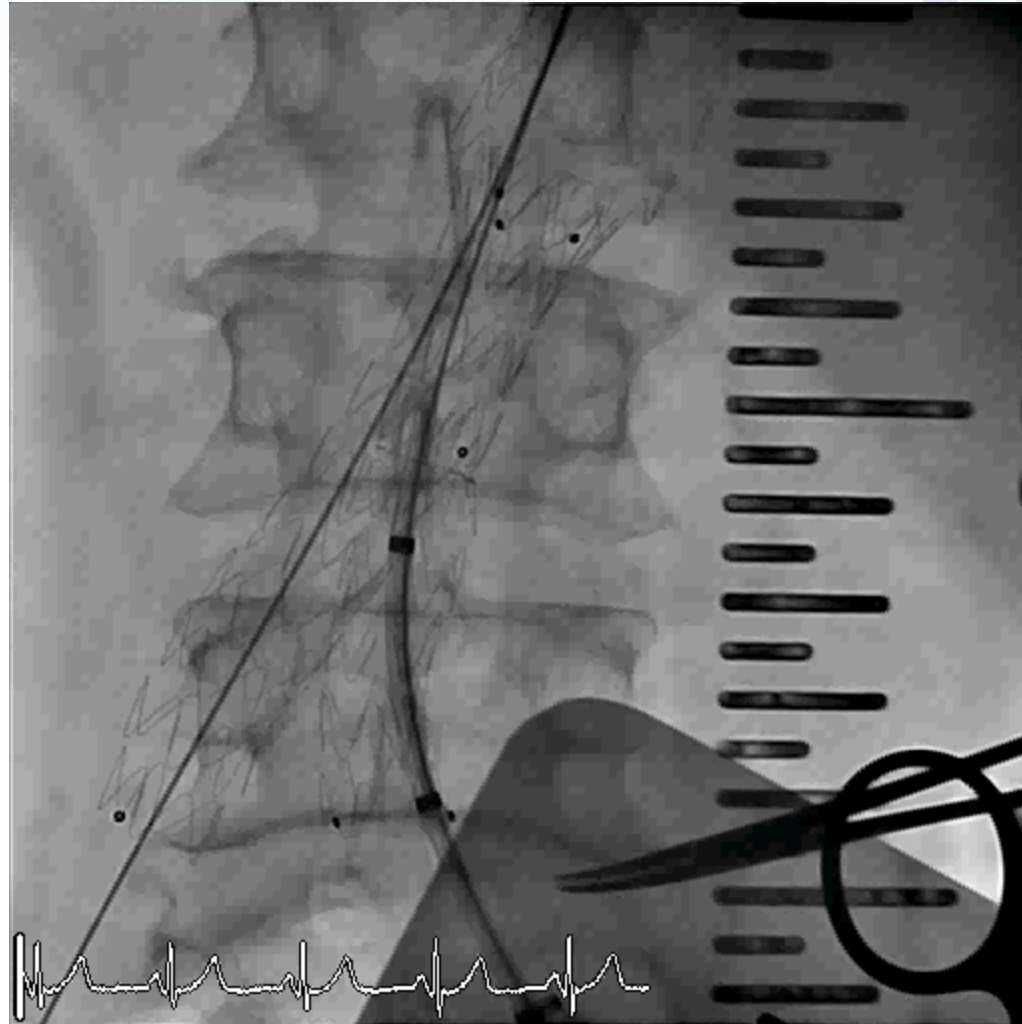


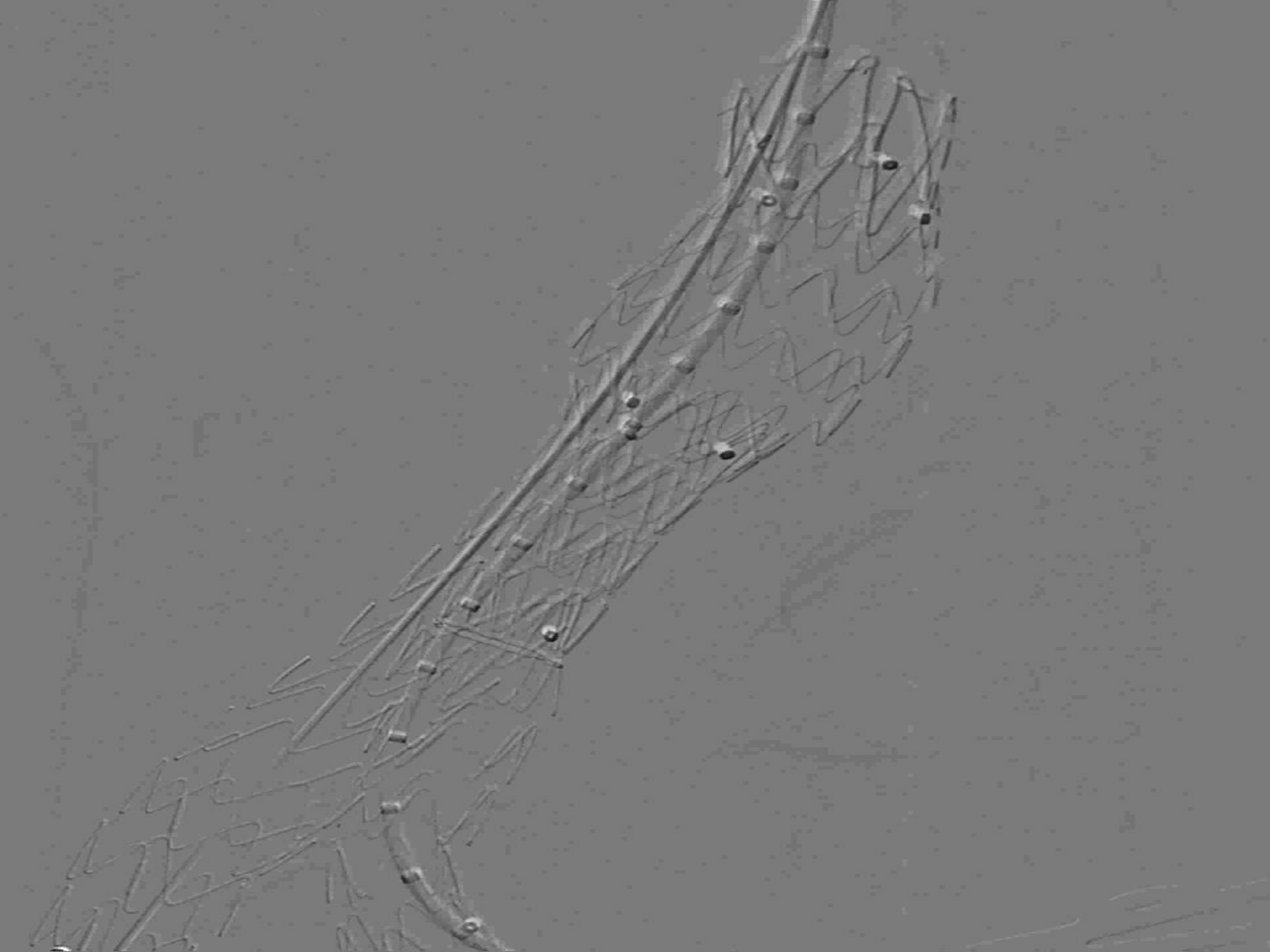




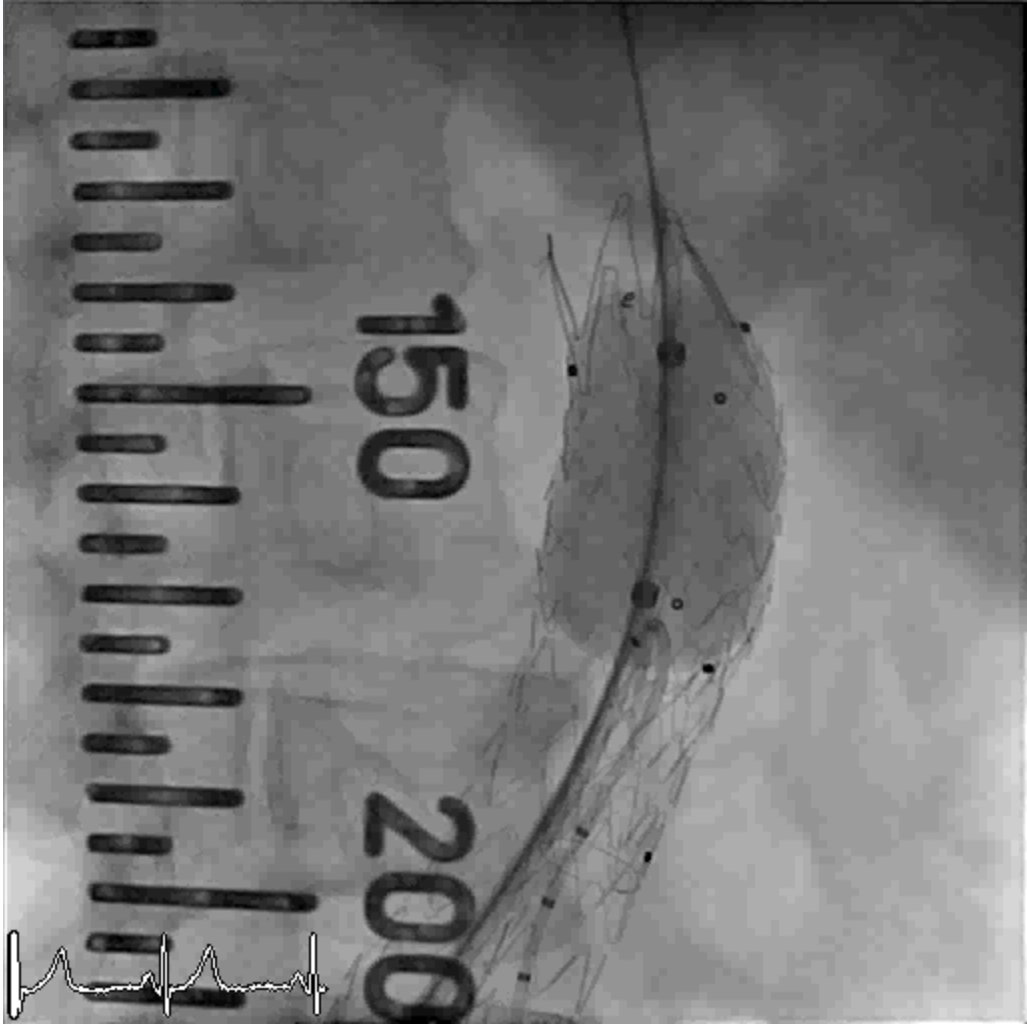


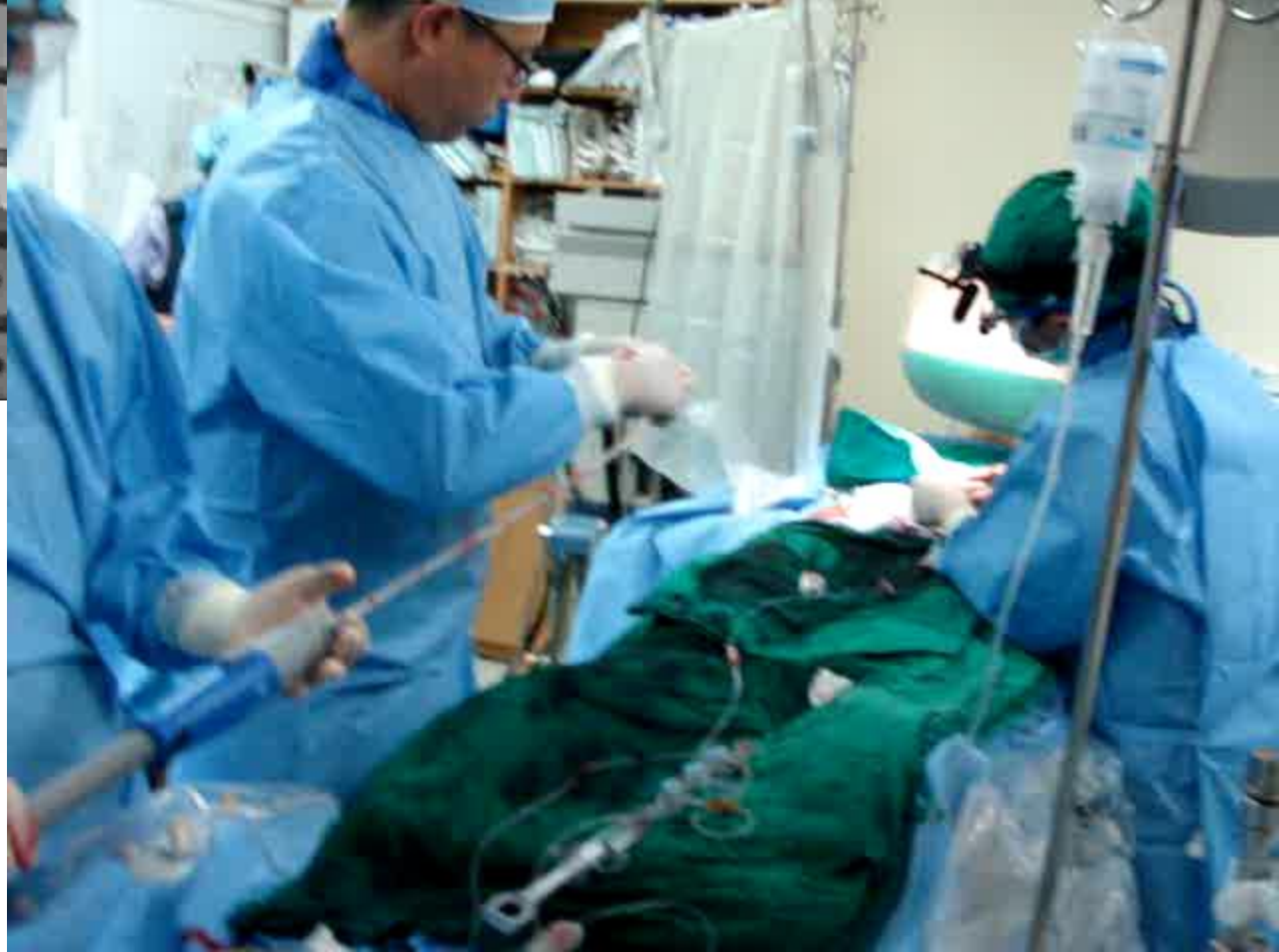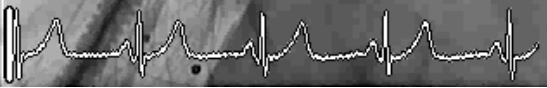
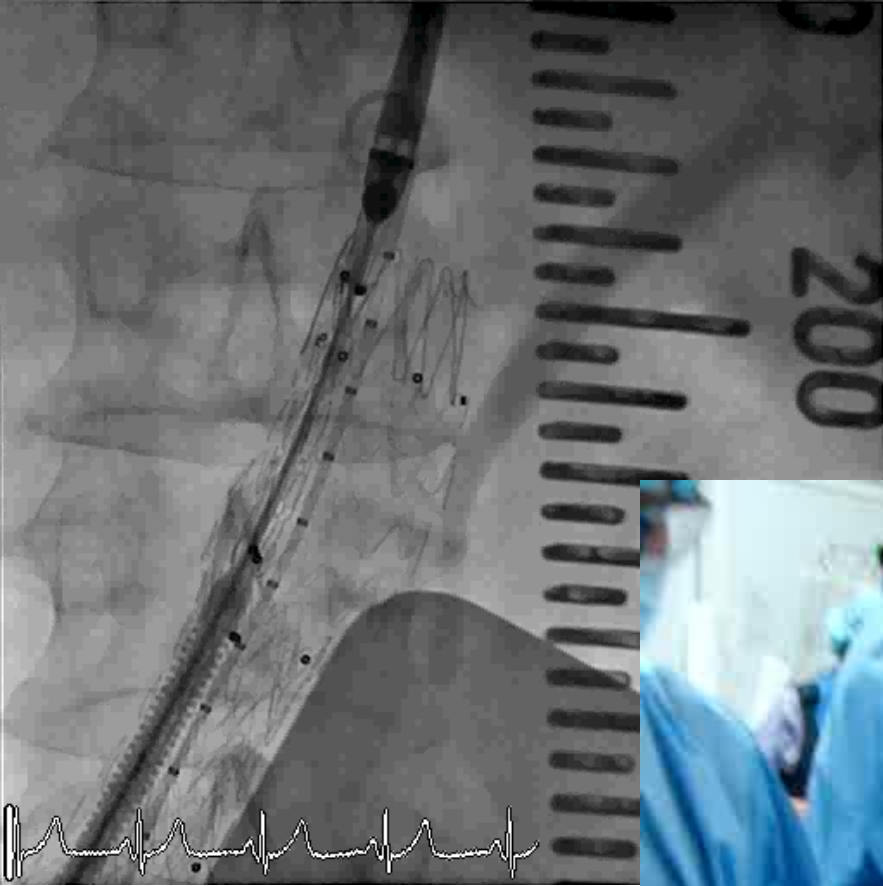




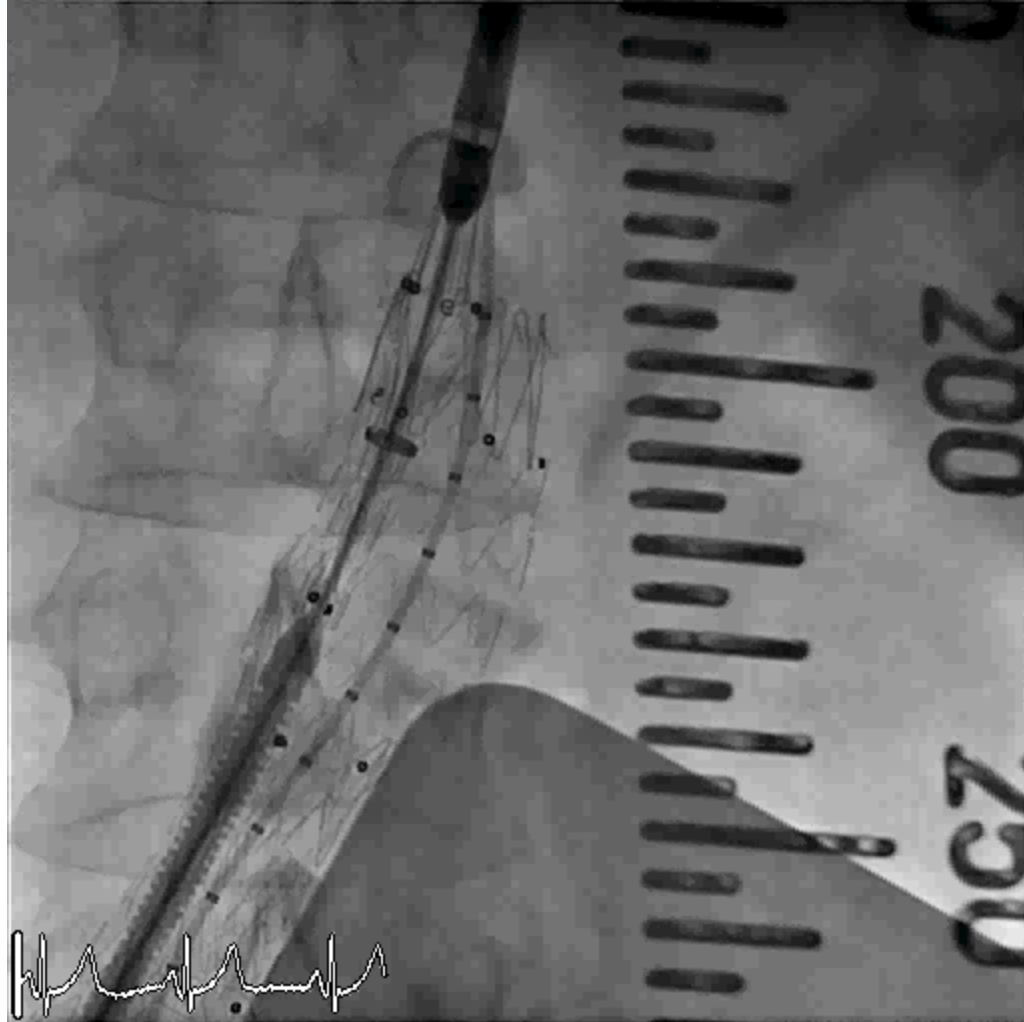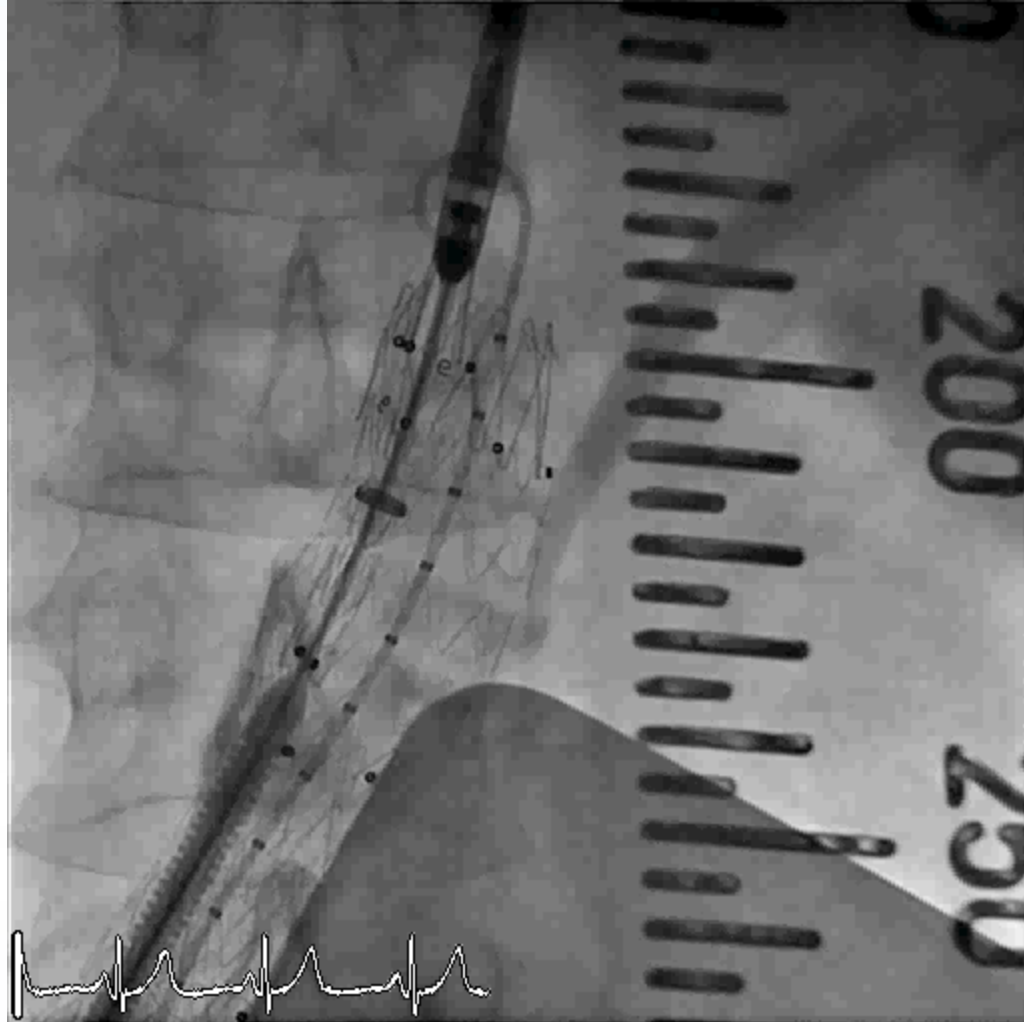











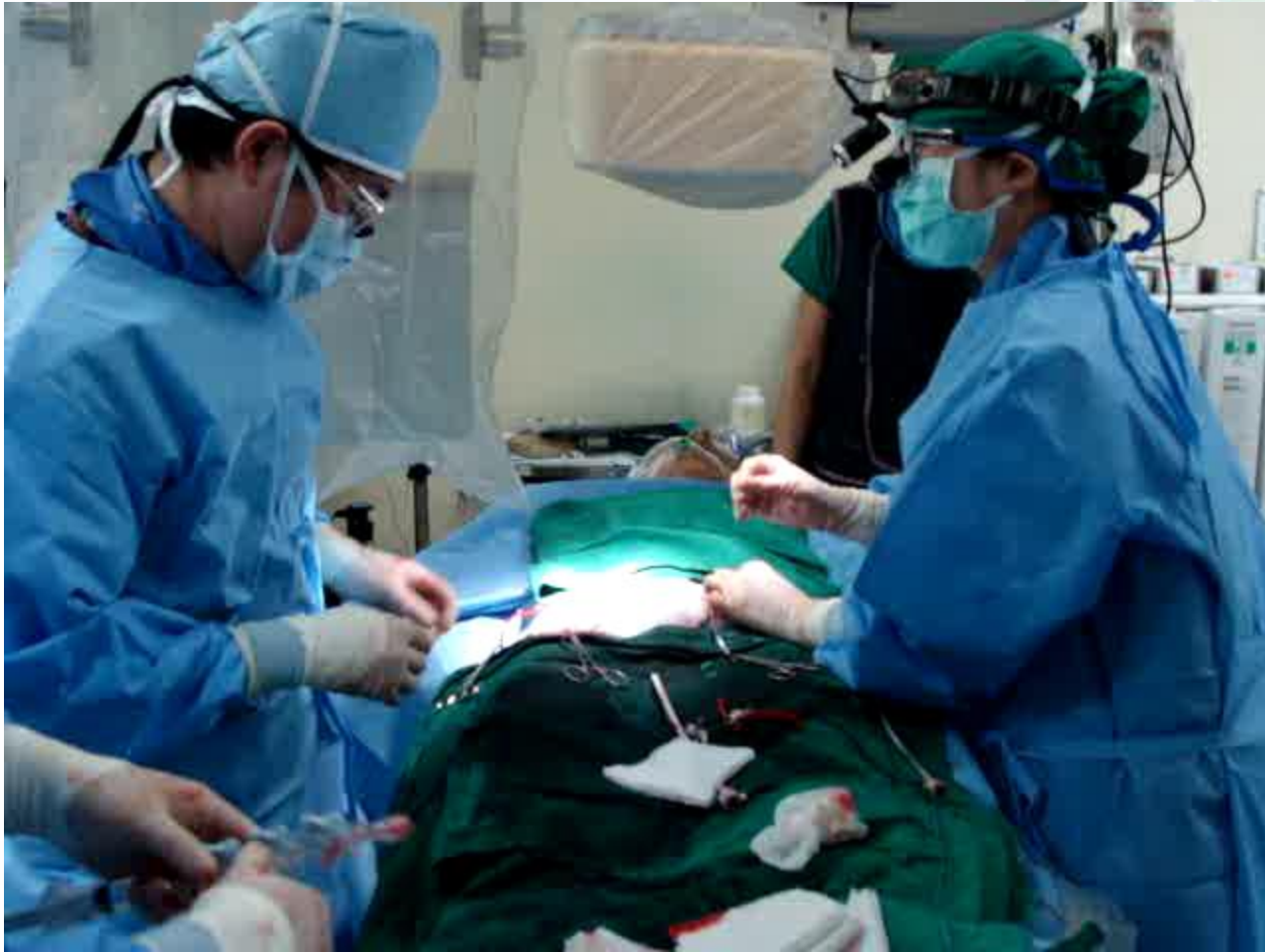









Thank you with my heart



CASE



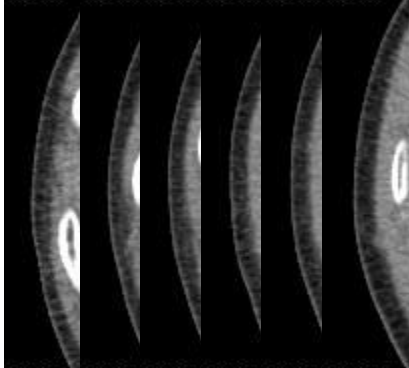
강오 M/46

- Chief Complaint : Abdominal distension
- Known Bercet disease
- Past History : HT(-) , DM(-)
Hyperlipidemia(0), CVA(-)
- Social History : Smoking (-)
- ESR 3, CRP 0.2

CT

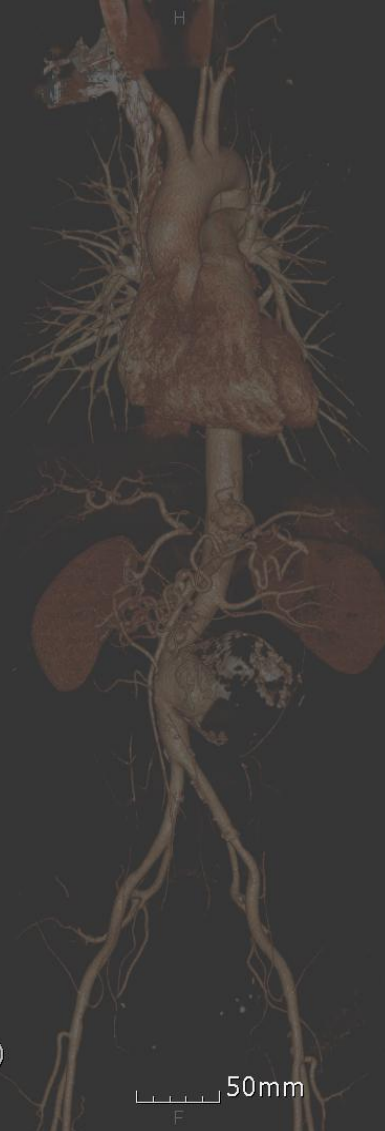

Idx :Idx Idx Idx Idx Idx 1
SMS SM SM SM SM SMS
Se 5Se Se Se Se Se 5
Im 1Im Im Im Im Im 1
CT CT CT CT CT CT
FFS FFS FFS FFS FFS FFS
2.0t2.0 2.0 2.0 2.0 2.0
APPL APF APF APF APF APPL
0.0 0.0 0.0 0.0 0.0 0.0



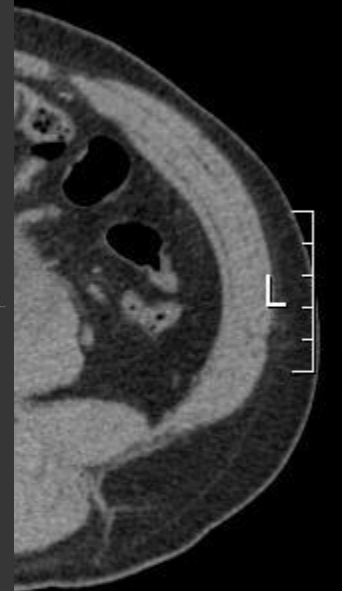FOV FOV FOV FOV FOV FOV
TP 3TP TP TP TP TP 3
TI 5TI !TI !TI !TI !TI 5
kVp kVpkVpkVpkVpkVp 1
mAs mA mA mA mA mA
GT GT GT GT GT GT 0
Thor Thc Thc Thc Thc Thora
Aort Aor Aor Aor Aor Aorta
201(2012012012012010

Idx 1
SMS Definition AS+
Se 801
Im 1
CT
0.0thk
0.0
R
FOV 652X652
TP 0.0
TI 0
kVp 0.0
mAs 0
GT 0
Thorax^08_Aorta_all (Adult)
VRT Collection
2010-11-09/20:08:26



PNUH
RES/CROP/SHADE/TYPE
2010-11-09
KANG CHANG^MYEONG^ ^
M 049Y 990166931
DOB:1961-04-05

PNUH
2010-11-09
CHANG MYEONG ^
M 049Y 990166931
DOB:1961-04-05



W 400
L 40
Z 100%
Compression 3:1

W 1326
L 380
B 100
O 100
Z 100%
Compression 7:1



Assessment



1. Huge pseudoaneurysm in the abdominal aorta
2. Bercet disease

Plan

1. EVAR for huge pseudoaneurysm
2. Steroid, azathioprine

