

Severe MVD PCI in the octogenarian. Do Not Hesitate!

Su Hong Kim M.D. PhD.

Chief Director

Busan Veterans Hospital, Veterans Health Service

Rep. of Korea



Veterans
Health
Service

Busan Hospital

JCR 2011

Patient Information

1) 85 year-old female

2) Chief Complaints : resting and aggravated chest pain for 4 days

3) Past History

- HTN for 20 years on medication
- Left ICA moderate stenosis & left MCA minimal infarction : 5 days ago Dx (on Aspirin & clopidogrel medication) : other university hospital



Patient Information

1) CAG at Other University Hospital 3 days ago

- pRCA subtotal obstruction
- dLM 50%, p-dLAD 70-90% diffuse narrowing with heavy calcification
- LCX : diffuse narrowing with calcification

Syntax Score : 36

→ Recommend CABG



Patient Information

Her Care-giver want to visit our hospital

Her son was took a PCI by myself at 2 years ago : p-mLAD CTO : 2 endeavor resolute stents depolyed



Lab. Findings

1) Blood study

- CBC : 6970-10.5-207K
- Lipid : 109-50-36-75
- BUN/Cr : 26/1.3, Na/K : 151/4.2
- proBNP : 4382
- TnT : normal range



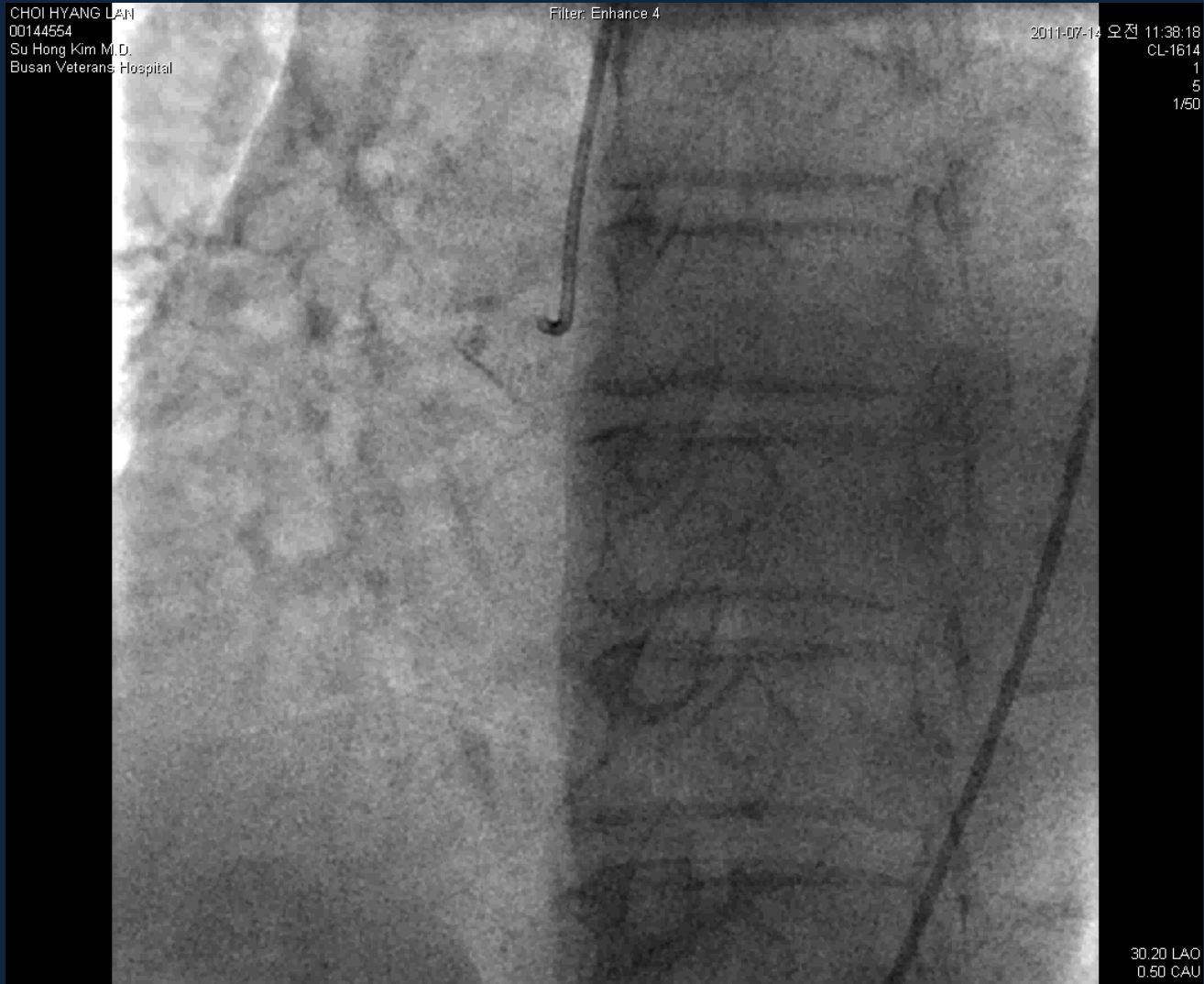Lab. Findings

2) Heart Study

- ECG : normal sinus rhythm without any ST-T change
- EchoCG : normal LV wall motion and systolic function, mild diastolic dysfunction, concentric LVH (14mm/13mm)
- Chest PA : mild cardiomegaly



CAG : RCA

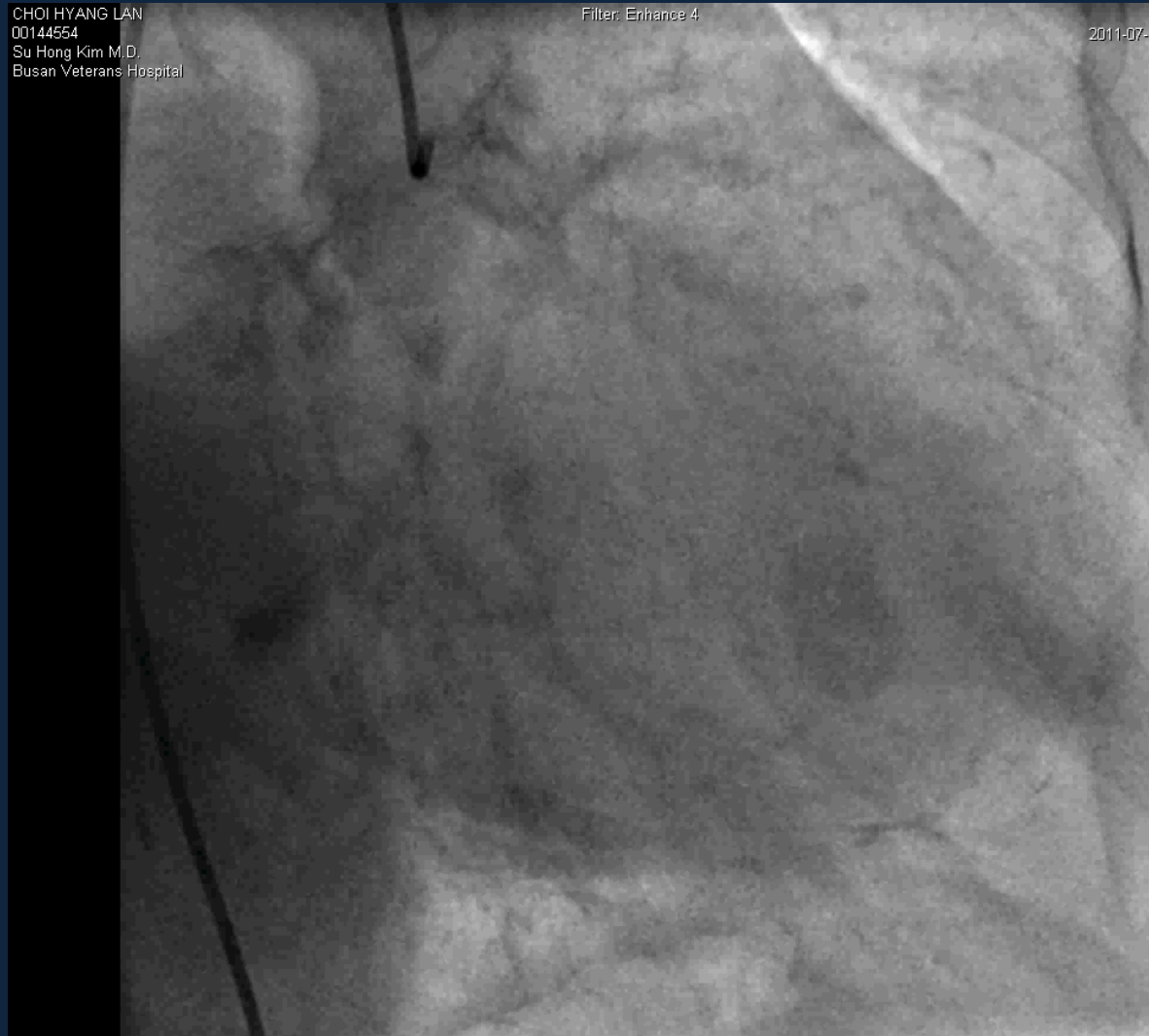

CAG : LCA

CHOI HYANG LAN
00144554
Su Hong Kim M.D.
Busan Veterans Hospital

Filter: Enhance 4

2011-07-14 오전 11:38:18
CL-1614
1
3
1/36



31.10 RAO
19.70 CAU



Veterans
Health
Service

Busan Hospital

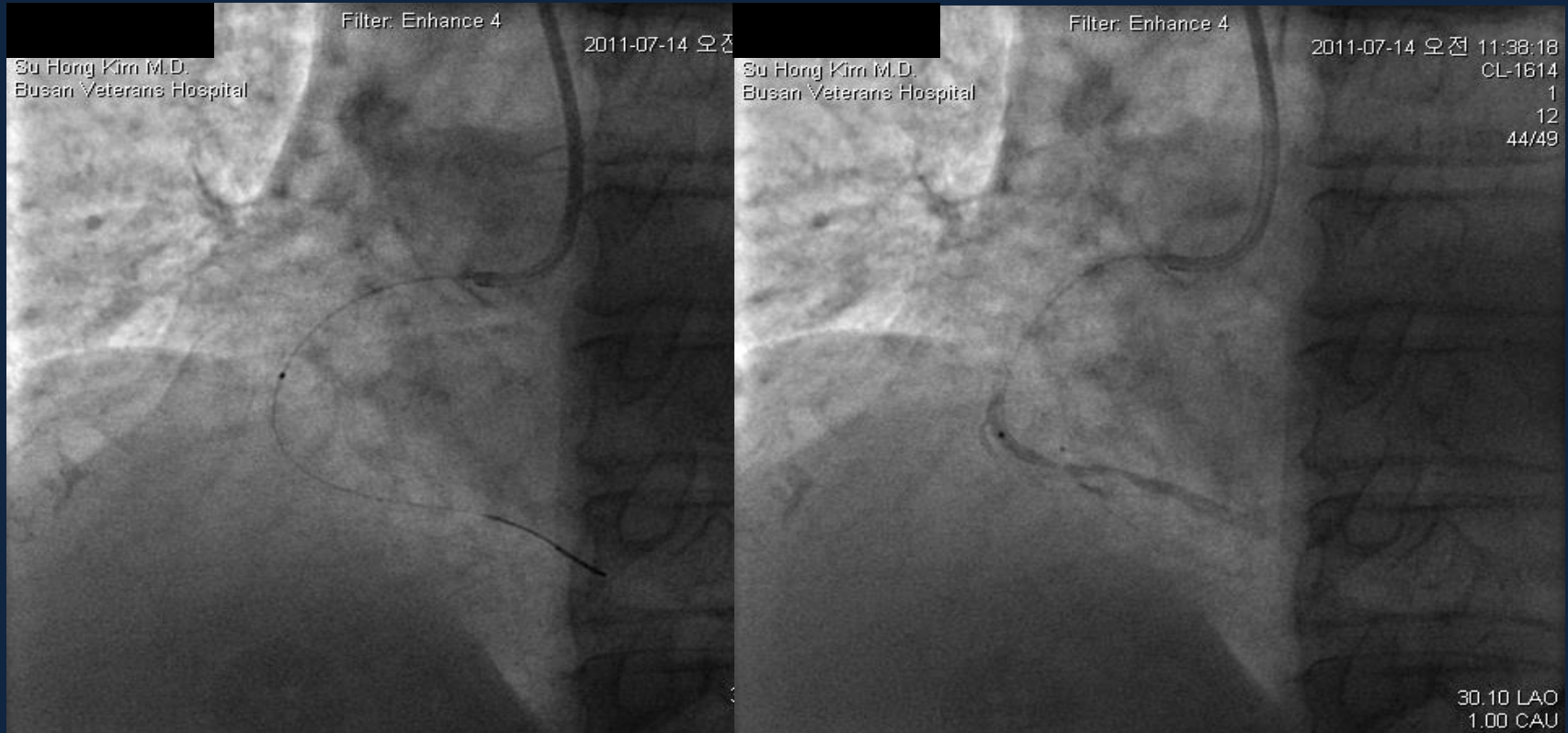JCR 2011

When U meet the case like this..

- 1) Re-Recommend CABG
- 2) Re-Warning



RCA wiring with micro



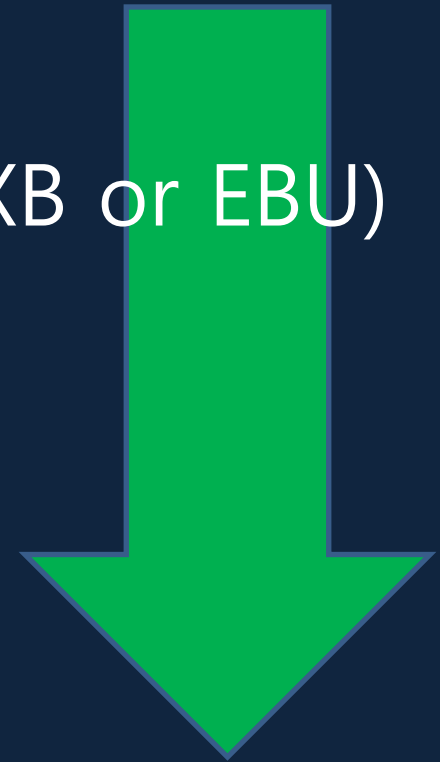
- 1) 7F JR 3.5 & 4 (deep seating) with Runthrough-NS wire : failed
- 2) GC change to 6Fr AL 0.75 with Fielder FC wire : Success



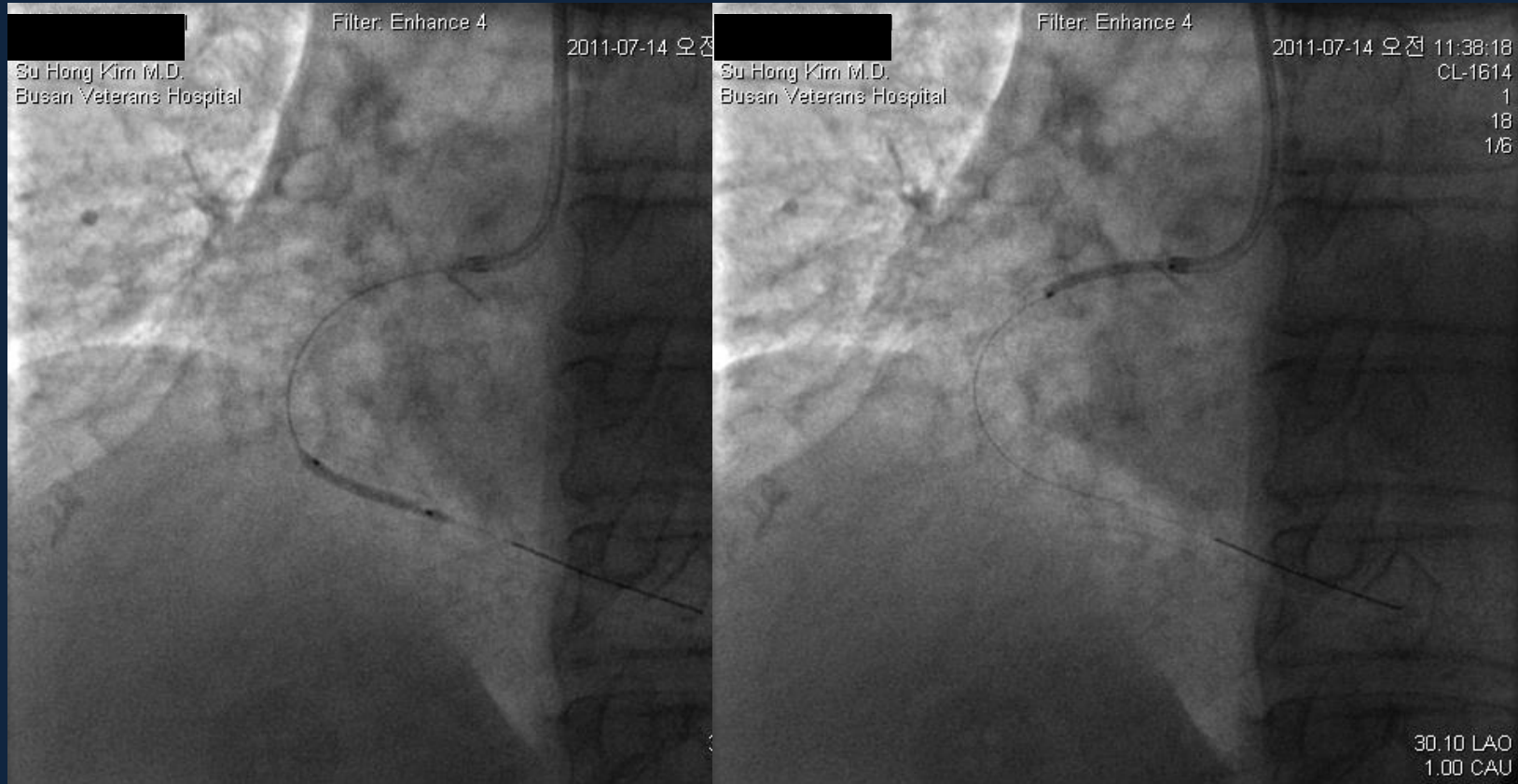My Strategy

Hard to advance to the target lesion

- 1) Deep Seating of GC
- 2) GC change (RCA : AL, LCA : XB or EBU)
- 3) 2 coronary wire
- 4) Anchor Ballooning
- 5) Mother to child GC



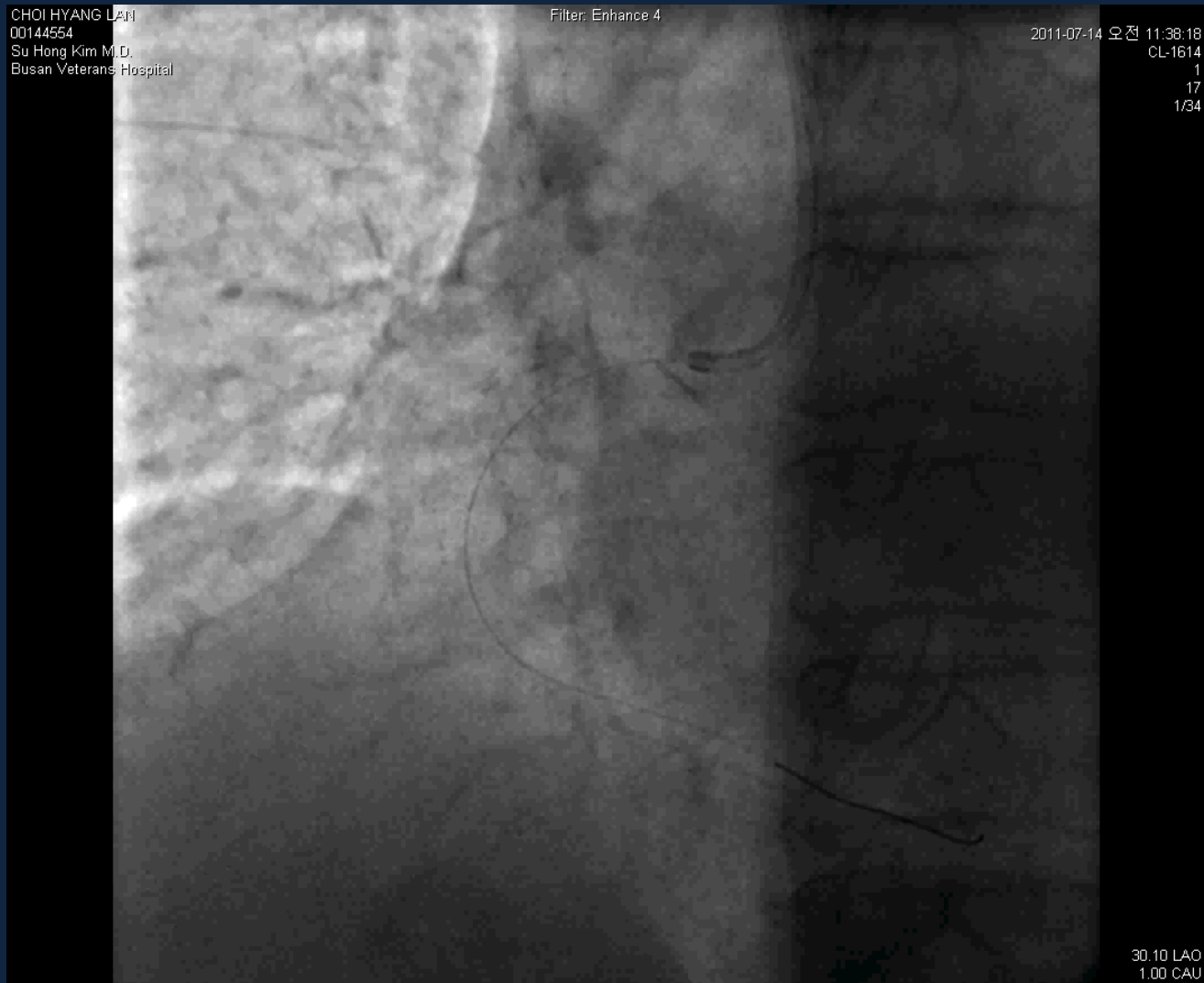PCI with ballooning



1) Trek balloon 1.5X15mm and Pantera balloon 3.0X20



RCA after ballooning

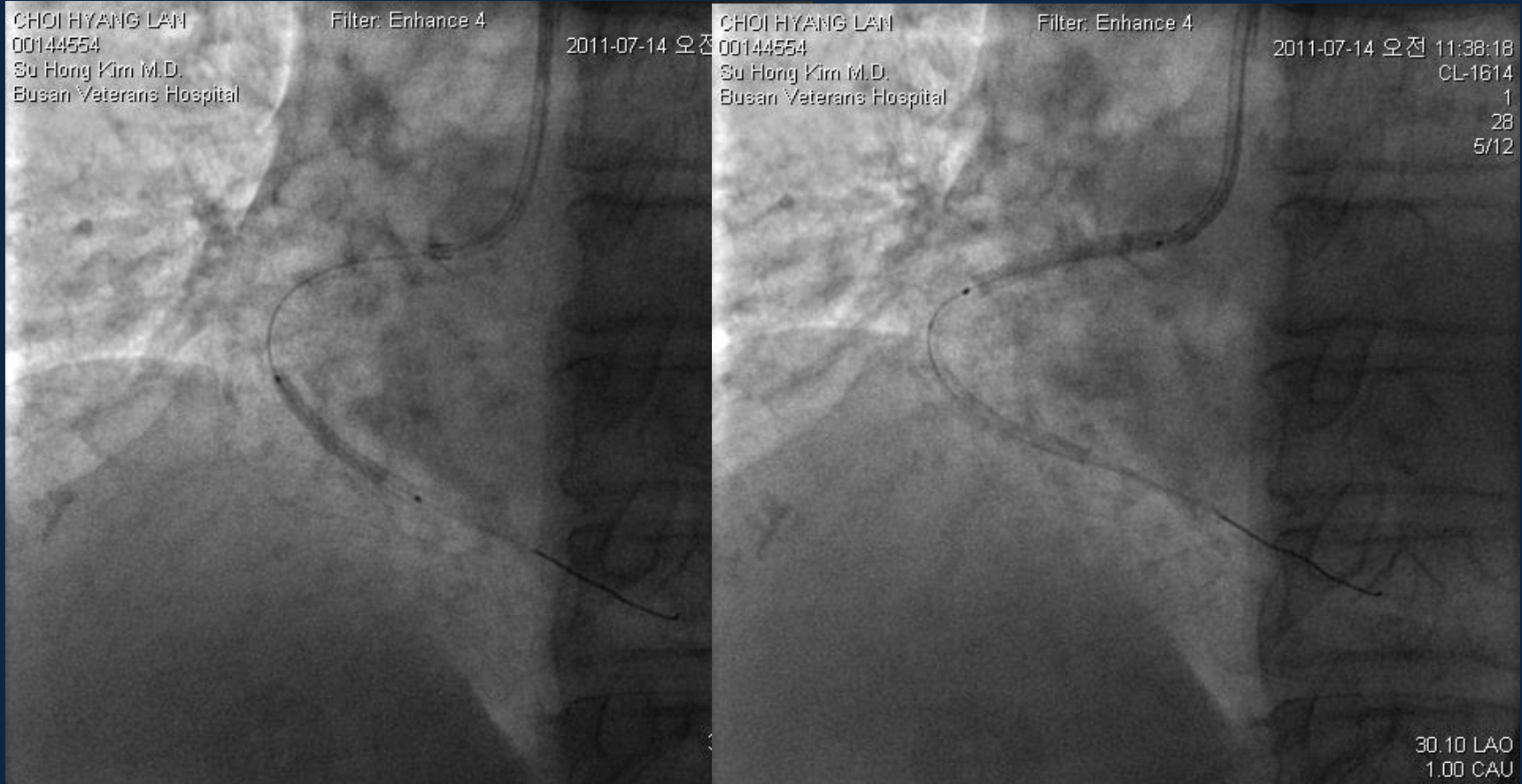

Veterans
Health
Service

Busan Hospital

JCR 2011

PCI with Stenting



1) 2 endeavor stent (1 Resolute and 1 Integrity 3.0mm sized) were deployed

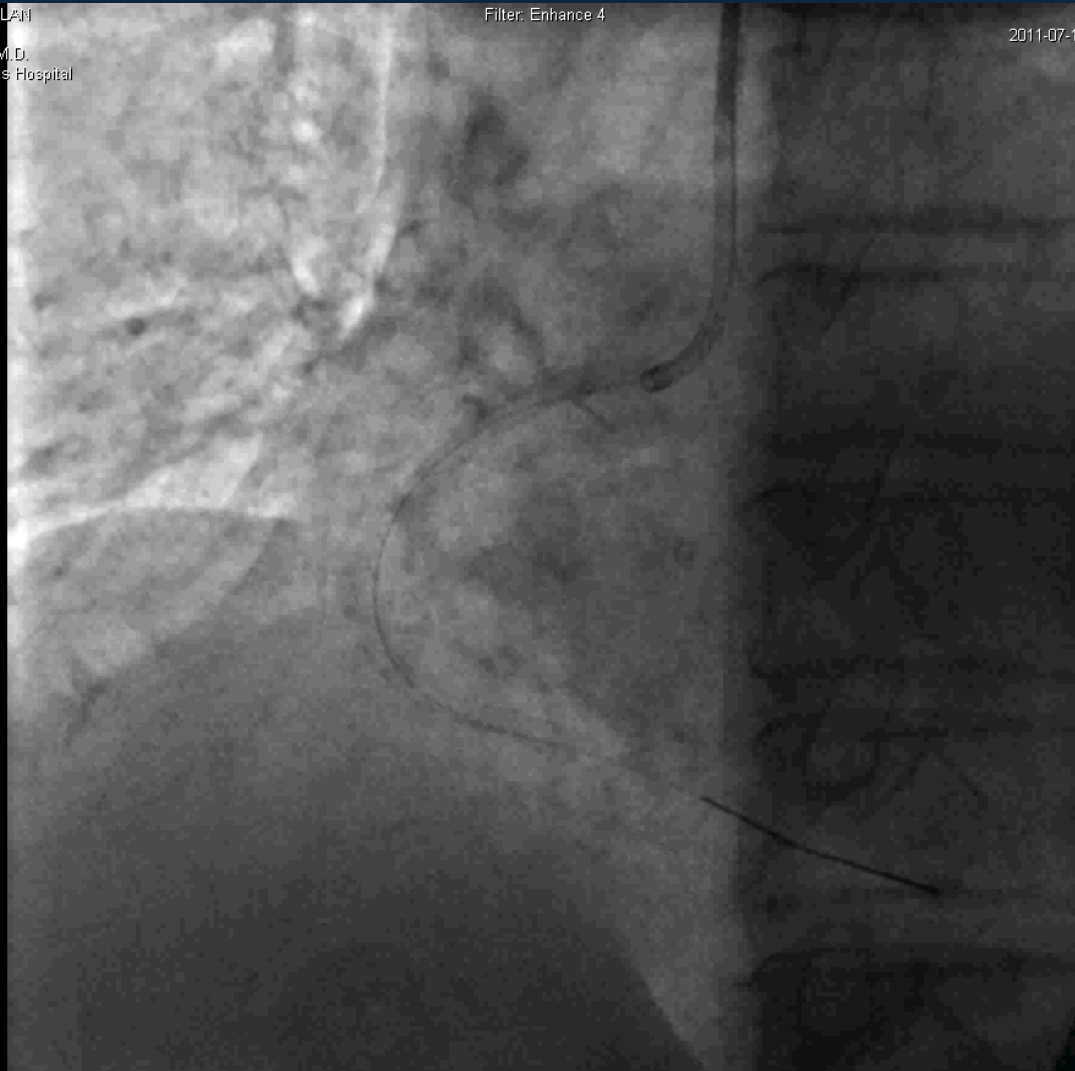

RCA final

CHOI HYANG LAN
00144554
Su Hong Kim M.D.
Busan Veterans Hospital

Filter: Enhance 4

2011-07-14 오전 11:38:18
CL-1614
1
30
1/40



30.10 LAO
1.00 CAU

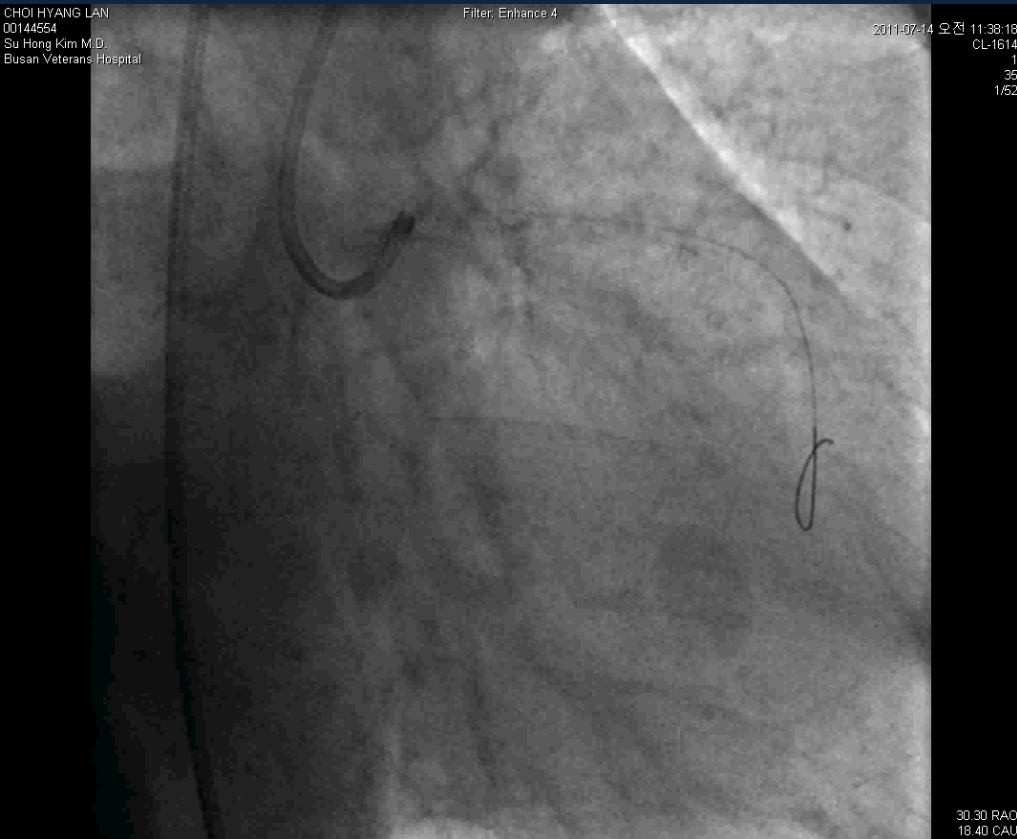


Veterans
Health
Service

Busan Hospital

JCR 2011

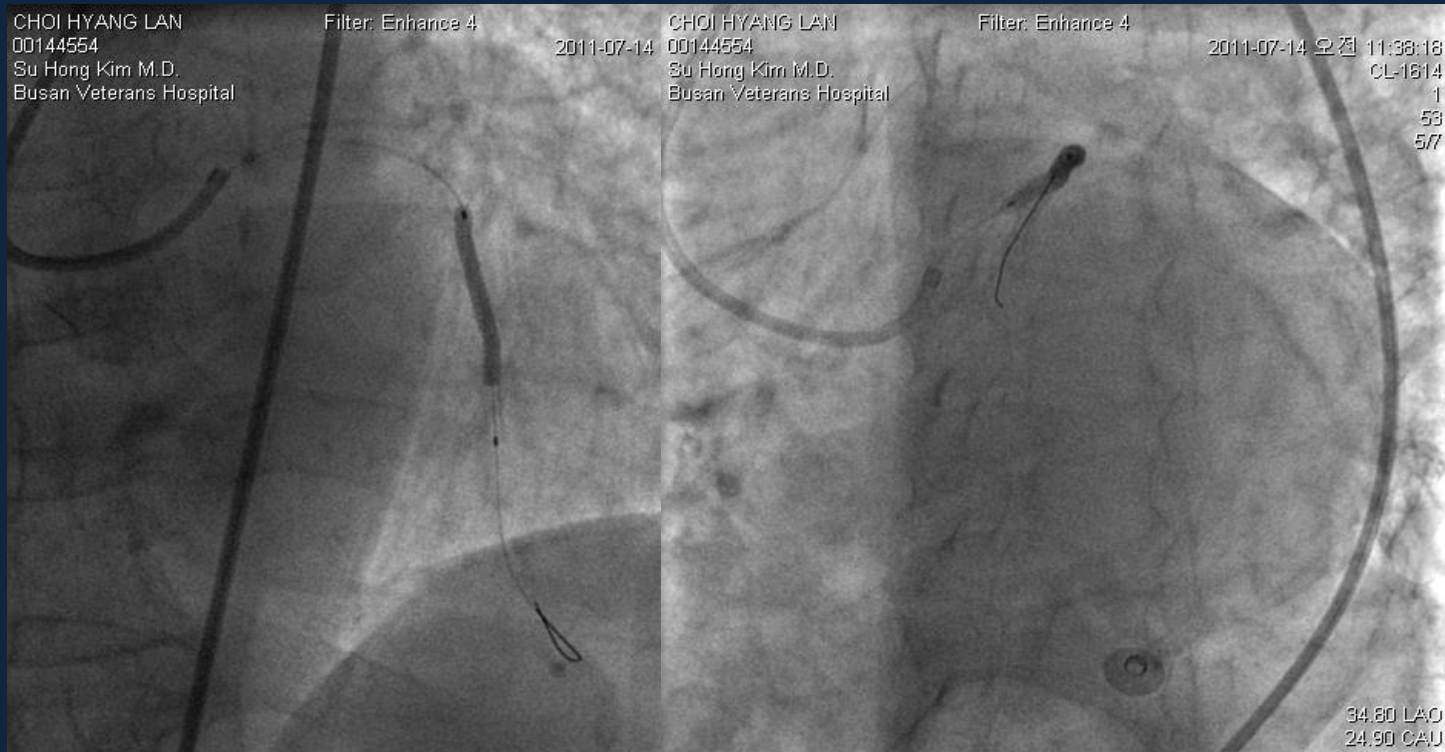LAD after ballooning



- 1) 7F JL 3.5 (deep seating) with Fielder FC wire : failed
- 2) and with microcatheter : Success
- 3) Ballooning with pantera 2.0X20mm



LAD with stenting



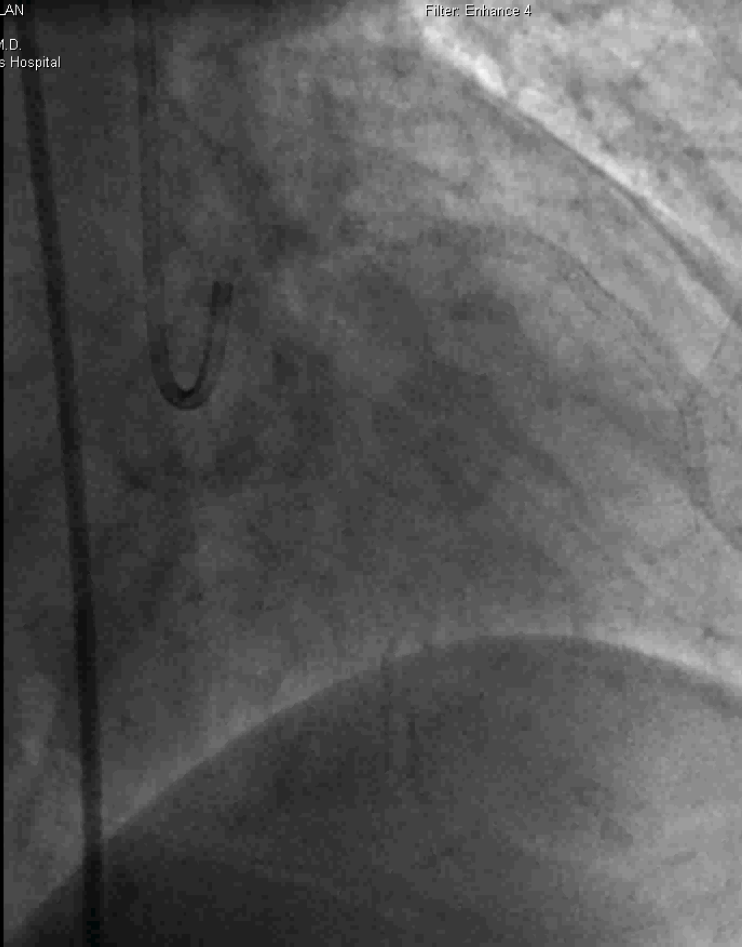
- 1) Hard to advance to stent to the dLAD
- 2) After Deep seating of GC : success to advance
- 3) 2 Xience prime stent (sized 2.5X38 and 2.75X38mm) were deployed



LAD Final

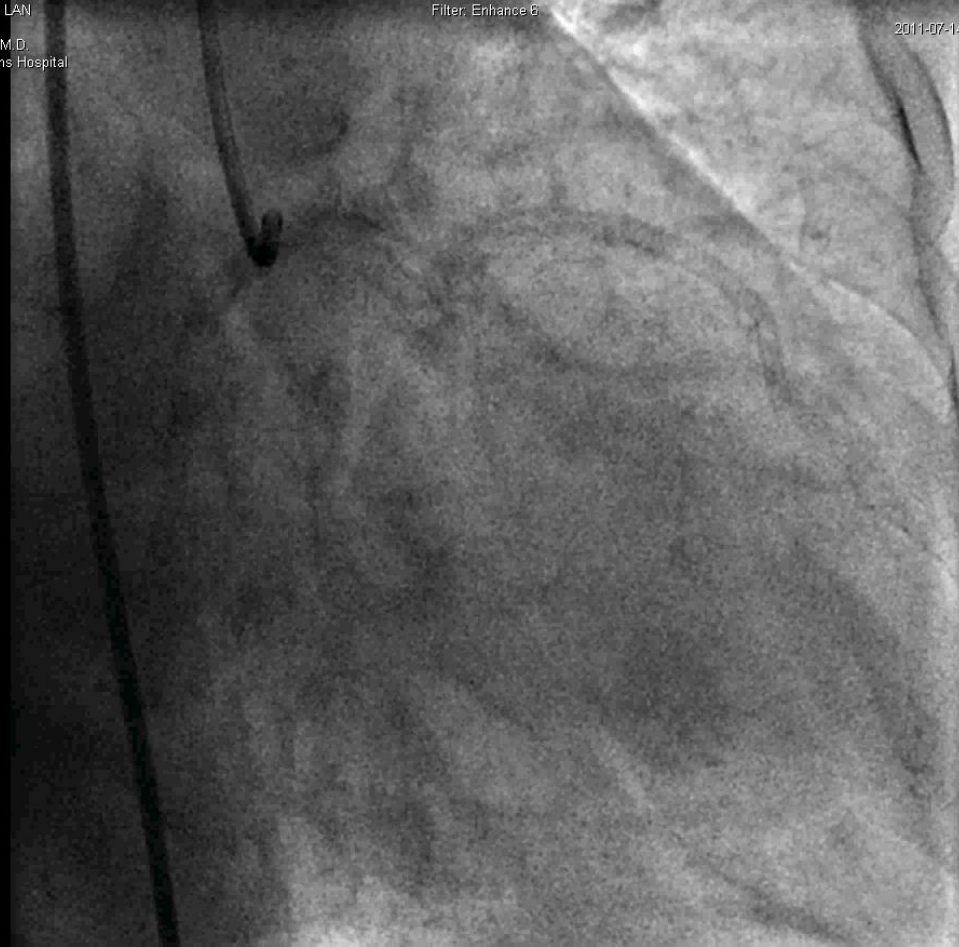
CHOI HYANG LAN
00144554
Su Hong Kim M.D.
Busan Veterans Hospital

Filter: Enhance 4



CHOI HYANG LAN
00144554
Su Hong Kim M.D.
Busan Veterans Hospital

Filter: Enhance 6



2011-07-14 오후



Veterans
Health
Service

Busan Hospital

JCR 2011

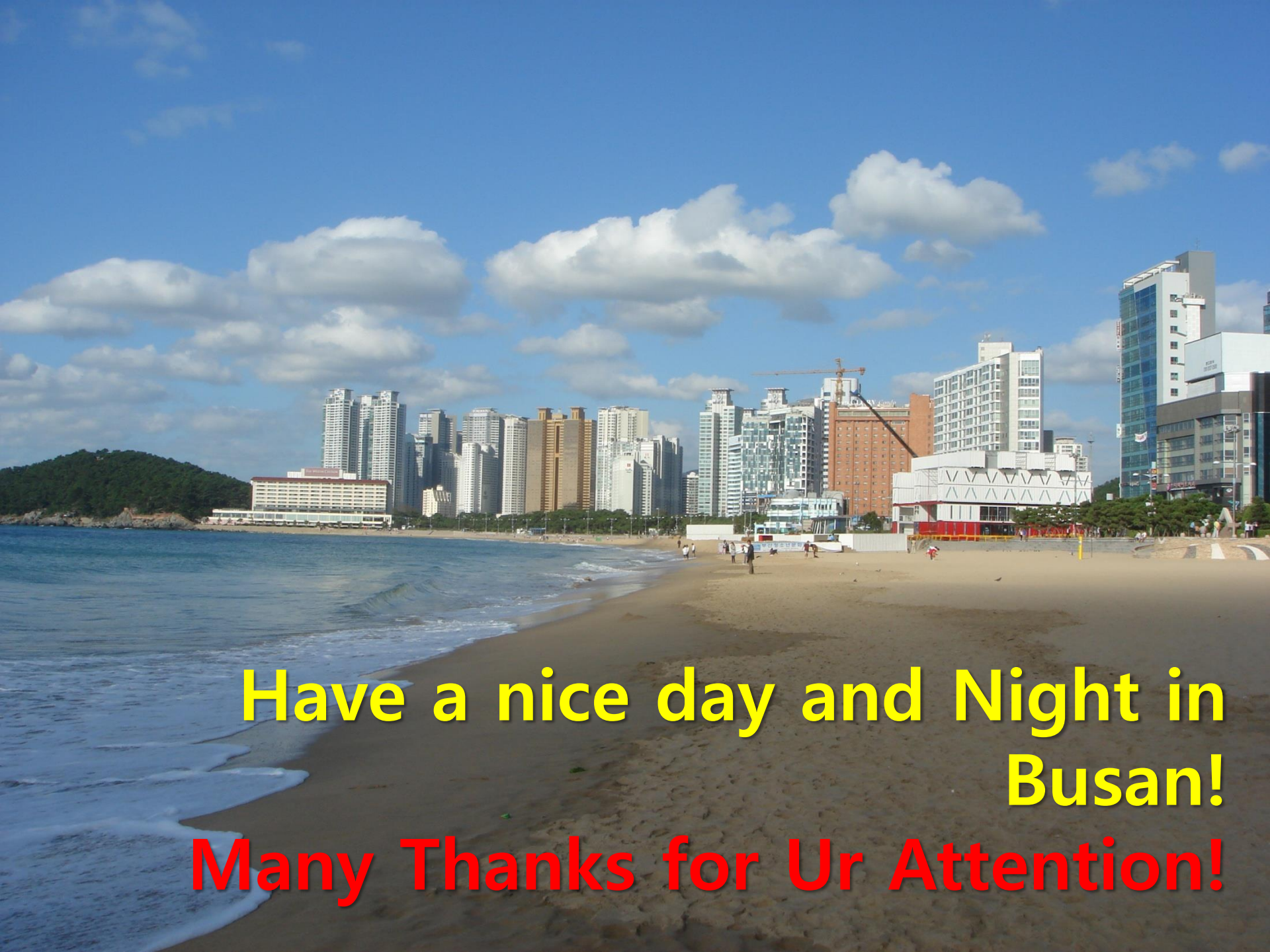Patient Progress

After Hard Attempt and Successful
Angiographic Results

She did **Not** complaint any symptoms for 5
months

May 2012 follow up CAG will be planned.





**Have a nice day and Night in
Busan!**

Many Thanks for Ur Attention!